Journal of Oral Science, Vol. 55, No. 4, 363-366, 2013

Case Report

The usefulness of an autologous blood clot combined with gelatin for regeneration of periodontal tissue

Hiroaki Kabashima[1)], Takako Sakai[2)], Kunitaka Mizobe[1)], Hiroyoshi Nakamuta[3)], Kenichi Kurita[2)], and Yoshihiro Terada[2)]

[1)]Section of Periodontology, Division of Oral Rehabilitation, Faculty of Dental Science, Kyushu University, Fukuoka, Japan
[2)]Section of Fixed Prosthodontics, Division of Oral Rehabilitation, Faculty of Dental Science, Kyushu University, Fukuoka, Japan
[3)]Private Practice, Fukuoka, Japan

(Received July 8, 2013; Accepted October 31, 2013)

Abstract: Several growth factors have been used in tissue regeneration therapy. Here we describe the use of an autologous blood clot combined with gelatin for teeth affected by severe periodontitis and vertical root fracture treated using three oral surgical procedures: periodontal flap surgery, intentional tooth replantation (IR), and tooth autotransplantation. Treatment with a blood clot improved the condition of the periodontal tissue, including reduction of pocket depth. Radiographical images demonstrated no evidence of ankylosis, and revealed the presence of alveolar bone regeneration. Our successful clinical outcome suggests that use of an autologous blood clot combined with gelatin is clinically effective for regeneration of lost periodontal tissue. (J Oral Sci 55, 363-366, 2013)

Keywords: regeneration; blood clot; gelatin.

Introduction

It is reported that application of growth factors such as platelet-rich plasma (PRP), platelet-derived growth factor (PDGF), enamel matrix derivative (EMD), transforming growth factor β (TGF-β) and blood clots at sites of surgical procedures resulting in periodontal defects might promote tissue healing and regeneration, including bone regeneration. Blood clots are rich in platelets and are non-toxic, as well as being a rich source of autologous growth factors. Among the growth factors derived from platelets, it is reported that TGF-β is able to inhibit osteoclast function and bone resorption, and can trigger healing through stimulation of collagen production (1-7). In addition, it has been reported that the presence of a good biodegradable material such as gelatin is required to enhance the biological function of bone morphogenetic protein (BMP) for bone regeneration (8). Gelatin has proven to be a good and clinically safe biomaterial for the controlled release of growth factors. Therefore, if controlled release of growth factors could be achieved for purposes of regeneration, then growth factor-induced regeneration therapy might become a viable treatment option for preservation of natural dentition.

Successful surgical treatment can be defined as an outcome that is clinically acceptable without any clinical symptoms, with improvement in the periodontal probing depth, and tissue regeneration demonstrated radiographically in the surrounding periodontal tissue.

Here we describe the use of autologous blood clots combined with gelatin for achieving successful clinical outcomes in three different surgical procedures: periodontal flap surgery, intentional tooth replantation (IR), and tooth autotransplantation. Our findings suggest that application of an autologous blood clot combined with gelatin is the simplest and safest procedure for induction

Correspondence to Dr. Hiroaki Kabashima, Section of Periodontology, Division of Oral Rehabilitation, Faculty of Dental Science, Kyushu University, 3-1-1 Maidashi, Higashi-ku, Fukuoka 812-8582, Japan
E-mail: hkabashi@dent.kyushu-u.ac.jp

doi.org/10.2334/josnusd.55.363
DN/JST.JSTAGE/josnusd/55.363

Fig. 1 A) Pretreatment conventional intraoral radiograph of the right mandibular second molar. B) Conventional intraoral radiograph taken 1 week after autotransplantation. C) Conventional intraoral radiograph taken 15 months after the operation, showing regeneration of alveolar bone around the involved root.

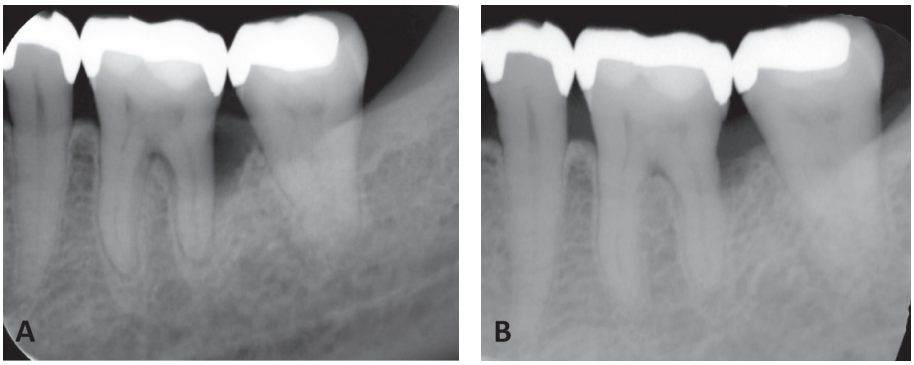

Fig. 2 A) Pretreatment conventional intraoral radiograph of the left mandibular first molar. B) Conventional intraoral radiograph taken 8 months after periodontal flap surgery, showing regeneration of alveolar bone around the involved root.

of tissue healing and regeneration in periodontal defects.

Case Report

Case 1

A 40-year-old woman was referred to the periodontic clinic of Kyushu University Hospital with a main complaint of tooth mobility and occlusal pain around the right mandibular second molar. Her medical history was non-contributory, and she reported no allergies or medication use. Intra-oral examination revealed a 9-mm probing pocket depth and class III mobility. Radiographs showed well-defined radiolucency in the alveolar bone supporting the right mandibular second molar. She was diagnosed as having severe periodontitis (Fig. 1A). We explained the benefits and risks of the treatment procedure and thereafter the patient made an informed decision. The treatment procedures were performed under local anesthesia. The right maxillary third molar and right mandibular second molar were extracted. The socket walls were then curetted and rinsed with sterile saline solution to remove granulation tissue and debris. Prior to transplantation, the right mandibular second molar socket was filled with an autologous blood clot combined with gelatin (Astellas Pharma Inc., Tokyo, Japan). Briefly, gelatin sponge was cut into small pieces (less than 1 mm^3), and placed into the periodontal defects after bleeding had been induced. The gelatin sponge was soaked with blood for 10 min. The right maxillary third molar was then transplanted to the right mandibular second molar region, and the tooth was stabilized using 4-0 silk suture. The patient returned 7 days later for suture removal (Fig. 1B). Thereafter, the replanted tooth was splinted to the adjacent tooth to reduce its mobility and minimize any possible traumatic occlusal force.

Clinical and radiographic follow-up was continued thereafter. For 15 months after tooth transplantation, the patient remained clinically asymptomatic, with normal occlusal function. Periodontal probing pocket depth remained within normal limits. The transplanted tooth showed physiological mobility, without any radiographic evidence of root resorption or ankylosis. In addition, bone regeneration was evident around the root on intra-oral radiographic images after 15 months (Fig. 1C).

Case 2

A 51-year-old woman was referred to the periodontic clinic of Kyushu University Hospital for assessment of swelling on the buccal gingiva of the left mandibular first

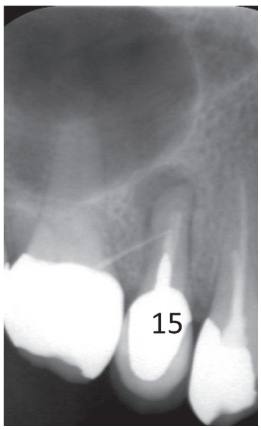

Fig. 3 Pretreatment conventional intraoral radiograph of the right maxillary second premolar, showing expansion of the periradicular lesion (7).

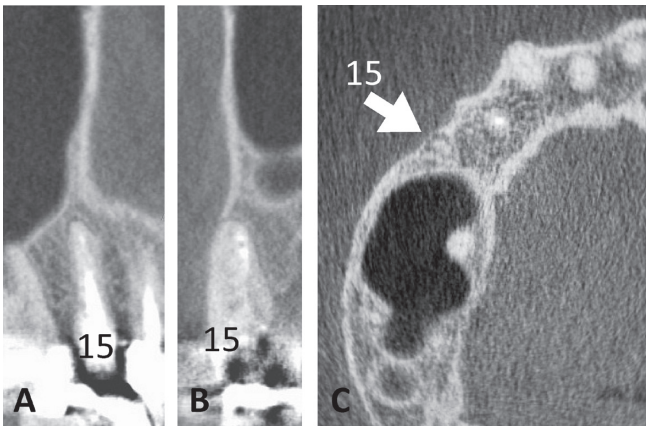

Fig. 4 High-resolution 3D images taken 50 months after replantation, showing regeneration of alveolar bone around the treated root. A) Coronal image of the right maxillary second premolar. B) Sagittal image of the second premolar, showing regeneration of alveolar bone around the affected root. C) Axial image of the second premolar, showing regeneration of alveolar bone around the affected root.

Fig. 5 Conventional intraoral radiograph taken 55 months after replantation.

molar. Her medical history was non-contributory and she reported no allergies or medication use. Periodontal examination revealed an 8-mm probing pocket depth in the distal pocket of the first molar and gingival swelling on the buccal side of the tooth. Vertical bone resorption along the distal side of the root of the first molar was observed on intraoral radiographic images. She was diagnosed as having moderate periodontitis (Fig. 2A). Informed consent of the patient was obtained after the benefits and risks of the treatment procedure had been fully explained. Periodontal flap surgery was carried out under local anesthesia. Buccal and lingual intracrevicular incisions were made and mucoperiosteal flaps were elevated. After the root surface had been scaled and planed, the surgical area was irrigated with sterile saline solution. Thereafter, the treatment procedure was similar to that used in case 1. The periodontal defect was filled with an autologous blood clot combined with gelatin. The flap was repositioned and sutured with 4-0 silk suture to accomplish complete interproximal closure.

Clinical and radiographic follow-up was continued thereafter. For 8 months after the operation, the patient remained clinically asymptomatic, and the periodontal pocket depth remained within normal limits. Bone regeneration along the root of the left mandibular first molar was evident on intraoral radiographic images 8 months after surgery (Fig. 2B).

Case 3

This patient was a 45-year old woman reported previously (7), who was followed up. Figure 3 shows the pretreatment conventional intraoral radiograph of the right maxillary second premolar. The periradicular lesion had expanded along the distal side of the root of the second premolar, revealing a radiolucent area around the middle part of the root. At the 12-month and 41-month recall points after IR, the reconstructed tooth showed no radiographic evidence of root resorption or ankylosis. In addition, bone regeneration around the affected root was evident even on 3D images (7).

Clinical and radiographic follow-up was continued for 55 months after IR. At the 50-month and 55-month recall points, the patient remained clinically asymptomatic, with normal occlusal function. Periodontal probing depth remained within normal limits, and there was no tooth mobility. Periapical healing around the root of the reconstructed tooth was observed radiographically (Fig. 4A-C). At the 12-month and 50-month recall points, no clear changes were evident, even on 3D images. At the 55-month recall point, radiographic examination revealed osseous healing of the peri-apical radiolucency (Fig. 5).

Discussion

Basic and clinical studies have investigated the local application of growth factors such as PRP, PDGF, TGF-β, and EMD, which have been reported to be critical for reliable tissue regeneration after surgical treatment. Platelets make up a large part of a blood clot and function as a reservoir of natural growth factors essential for tissue healing and regeneration. It is reported that the secretion of growth factors from platelets begins as a result of degranulation, after blood clotting has been initiated. Thereafter, several growth factors such as BMP, PDGF, and TGF-β in the blood clot may exert biological activities and promote tissue regeneration at surgical sites (1-8). In addition, it has been reported that platelets release anti-microbial proteins and play an important role in preventing bacterial infection (9). We have previously reported that BMP-2-positive cells were observed in blood clots such as those used for regeneration of periapical tissue in patients undergoing guided tissue regeneration treatment (10).

In the cases described here, the affected teeth were neither mobile nor tender to percussion, and probing depths were within normal limits. Absence of ankylosis and the presence of bone regeneration around the affected root were evident radiographically, indicating that the outcome was favorable. Therefore, our present results suggest that an autologous blood clot immobilized with gelatin hydrogel fragments might function not only as a carrier of natural growth factors, but also as a filler to prevent the growth of soft tissue into the periodontal defect. In addition, the good clinical outcome observed in these cases appeared to be attributable to the regenerative potential of the blood clot, suggesting that slow degradation of the gelatin hydrogel facilitated controlled release of growth factors from the clot, thus helping to maximize the healing potential of the residual tissue through growth factor-mediated tissue regeneration in the circumferential periodontal defects surrounding the affected teeth while aseptic conditions were maintained, as reported previously (8).

Local application of an autologous blood clot combined with gelatin is thought to be a desirable and safe procedure for promotion of tissue regeneration in circumferential periodontal defects. However, further long-term studies of treatment outcomes should be performed to investigate the possible clinical application of autologous blood clots combined with gelatin hydrogel to promote tissue healing and alveolar bone regeneration after surgical procedures.

References

1. Howes R, Bowness JM, Grotendorst GR, Martin GR, Reddi AH (1988) Platelet-derived growth factor enhances demineralized bone matrix-induced cartilage and bone formation. Carcif Tissue Int 42, 34-38.
2. Centrella M, Horowitz MC, Wozney JM, McCarthy TL (1994) Transforming growth factor-β gene family members and bone. Endocr Rev 15, 27-39.
3. Heijl L, Heden G, Svärdström G, Ostgren A (1997) Enamel matrix derivative (EMDOGAIN) in the treatment of intrabony periodontal defects. J Clin Periodontol 24, 705-714.
4. EI-sharkawy H, Kantarci A, Deady J, Hasturk H, Liu H, Alshahat M et al. (2007) Platelet-rich plasma: growth factors and pro- and anti-inflammatory properties. J Periodontol 78, 661-669.
5. Houde N, Chamoux E, Bisson M, Roux S (2009) Transforming growth factor-β1 (TGF-β1) induces human osteoclast apoptosis by up-regulating Bim. J Biol Chem 284, 23397-23404.
6. Yamauchi N, Yamauchi S, Nagaoka H, Duggan D, Zhong S, Lee SM et al. (2011) Tissue engineering strategies for immature teeth with apical periodontitis. J Endod 37, 390-397.
7. Kabashima H, Mizobe K, Sakai T, Nakamuta H, Kurita K, Terada Y (2012) The usefulness of three-dimensional imaging for prognostication in cases of intentional tooth replantation. J Oral Sci 54, 355-358.
8. Yamamoto M, Takahashi Y, Tabata Y (2003) Controlled release by biodegradable hydrogels enhances the ectopic bone formation of bone morphogenetic protein. Biomaterials 24, 4375-4383.
9. Clemetson KJ (2011) The role of platelets in defense against pathogens. Hamostaeologie 31, 264-268.
10. Kabashima H, Nagata K (2001) Presence of interleukin-4-producing cells for human bone regeneration after application of guided tissue regeneration membranes. J Endod 27, 444-448.