Journal of Oral Science, Vol. 54, No. 3, 219-225, 2012

Original

In vitro comparison of cone beam computed tomography with different voxel sizes for detection of simulated external root resorption

Frederico S. Neves[1)], Deborah Q. de Freitas[1)], Paulo S. F. Campos[2)], Solange M. de Almeida[1)] and Francisco Haiter-Neto[1)]

[1)]Department of Oral Diagnosis, Division of Oral Radiology, Piracicaba Dental School, State University of Campinas, Piracicaba, SP, Brazil
[2)]Department of Oral Radiology, School of Dentistry, Federal University of Bahia, Salvador, BA, Brazil

(Received 14 April and accepted 27 June 2012)

Abstract: The present study compared the efficacy of cone beam computed tomography using different voxel sizes in the diagnosis of simulated external root resorption. The presence or absence of simulated defects on buccal, mesial and distal root surfaces of 20 premolars was evaluated. The defects were small (0.26 mm in diameter and 0.08 mm deep), medium (0.62 mm in diameter and 0.19 mm deep) and large (1.05 mm in diameter and 0.24 mm deep), equally distributed on each root surface. Images were obtained using Classic i-CAT cone beam computed tomography with different voxel sizes: 0.12, 0.20, 0.25 and 0.30 mm. Five oral radiologists evaluated the images. Accuracy, sensitivity, specificity, positive and negative predictive values were determined. The sensitivity decreased and specificity increased as voxel size increased. Accuracy values were the highest for the smallest voxel size (0.12 mm). The results for voxel sizes 0.20 mm and 0.25 mm were similar. Positive and negative predictive values were similar in all protocols, except with 0.30 mm, in which they were the lowest. In conclusion, external root resorption was more easily diagnosed when a smaller voxel size was used. (J Oral Sci 54, 219-225, 2012)

Correspondence to Dr. Frederico Sampaio Neves, Department of Oral Diagnosis, Division of Oral Radiology, Piracicaba Dental School, State University of Campinas, PO 52, Piracicaba, São Paulo 13414-903, Brazil
Tel: +55-19-21065327
E-mail: fredsampaio@yahoo.com.br

Keywords: computed tomography; voxel; external root resorption; tooth root.

Introduction

External root resorption (ERR) may occur as a complication after orthodontic tooth movement, dental trauma, transplantation, pulp infection, bleaching procedures, and periodontal procedures, with impacted teeth, cysts, and tumors, and due to pressure from an adjacent erupting tooth (1).

Apical root resorption is an undesirable sequelae of orthodontic therapy that may, in some cases, compromise the results of successful treatment (2,3). When root resorption is detected during active treatment, a decision must be made as to whether to continue, modify or discontinue the treatment. After three months, apical root resorption is usually detected in a few teeth. The number increases significantly after six months (2). Orthodontic patients with detectable root resorption during the first six months of active treatment are more likely to experience resorption in the following six-month period than those without it (4). Thus, early detection of root resorption during orthodontic treatment is essential for identifying teeth at risk of severe resorption (5).

The diagnosis of ERR is often based on clinical and radiographic examination, and its detection is a real challenge to the dentist, especially when there are no evident clinical signs (6). However, conventional radiography is not always reliable for the diagnosis of ERR, particularly

Table 1 Diameter and depth of the root defects

	Diameter (mm)	Deep (mm)
No cavity (control group)	0	0
Small cavity (ERR1)	0.26	0.08
Medium cavity (ERR2)	0.62	0.19
Large cavity (ERR3)	1.05	0.24

in small defects on the buccal or lingual surface. It is necessary for a certain degree of resorption to occur before the defect can be detected by conventional radiographic examination. Thus small cavities, 0.60 mm in diameter and 0.30 mm deep, may not be visible in conventional intraoral radiographs (7). It has been observed that orthodontic forces induced ERR after the first week of treatment; however this was not evident in periapical radiographs (8). When conventional radiographs were used, defects less than 0.28 mm of depth could not be viewed (9). Moreover, such images do not present a real three-dimensional (3D) view of the resorption (10).

Cone beam computed tomography (CBCT) shows 3D images of dental structures and offers clear structural images with high contrast; furthermore, examination can be performed using lower patient exposure doses when compared to multislice computed tomography (11,12). Few data is available on the detection of ERR by CBCT (13-15) or on the effect of voxel size in such diagnosis (16). Therefore, the aim of this study was to compare the diagnostic efficacy of CBCT with different voxel sizes in detecting simulated ERR.

Materials and Methods

This study was approved by the Piracicaba Dental School – State University of Campinas Ethical Committee. Twenty single-rooted premolar teeth with no visible defects or root fractures, which had been extracted for orthodontic purposes and stored in water, were used. Four defect possibilities (Table 1) were randomly distributed over nine regions of each root surface: buccal cervical, buccal middle, buccal apical, distal cervical, distal middle, distal apical, mesial cervical, mesial middle and mesial apical. The root surfaces received an equal number of defect possibilities (45 no cavity, 45 small, 45 medium and 45 large cavities), distributed equally in each root third. The defects were created with a spherical diamond bur (KG, Sorensen, Brazil) using a cavity preparation machine developed by Soares et al. (17) to standardize the cavity diameter and depth.

The radicular portion of each tooth was covered uniformly with a layer of utility wax (Epoxiglass, São Paulo, Brazil), with approximately 0.30 mm of thickness,

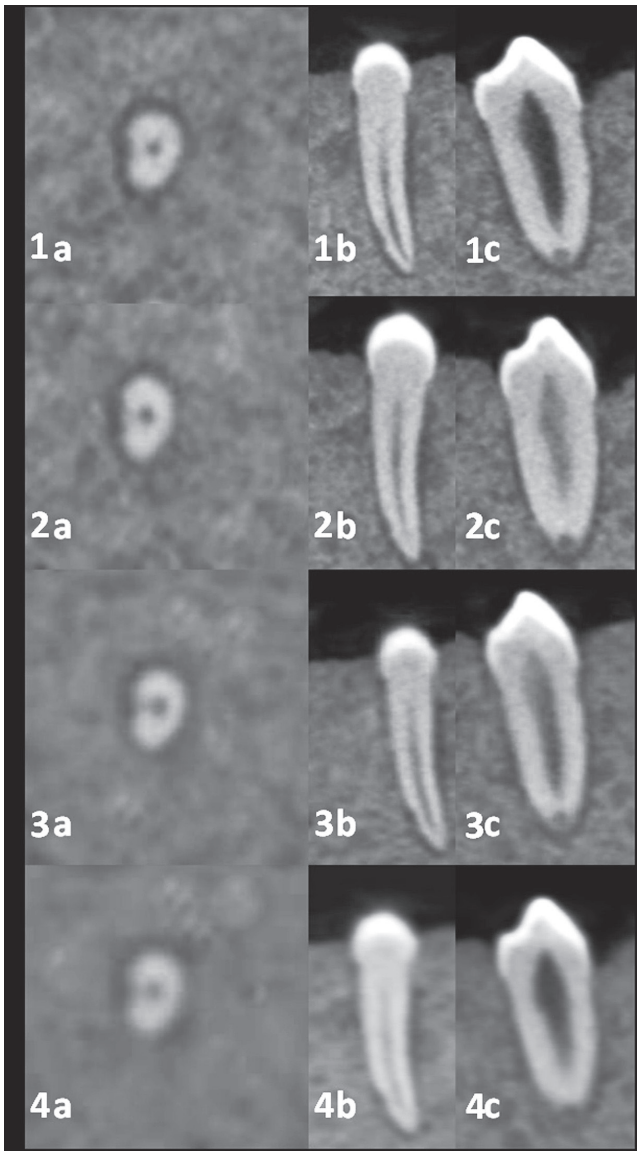

Fig. 1 Simulated external root resorption (large cavity) visualized in the apical third of CBCT images with different voxel sizes. 1) 0.12 mm voxel: axial (1a), coronal (1b) and sagittal (1c) slices; 2) 0.20 mm voxel: axial (2a), coronal (2b) and sagittal (2c) slices; 3) 0.25 mm voxel: axial (3a), coronal (3b) and sagittal (3c) slices; 4) 0.30 mm voxel: axial (4a), coronal (4b) and sagittal (4c) slices.

and inserted into stone type plaster mixed with ground rice in an equal ratio by volume in order to obtain a radiographic aspect equivalent to the soft tissue (periodontal space) and alveolar trabecular bone (dental alveolus), simulating an in vivo situation. The presence of wax layer reduces the occurrence of artifacts around the root surface in the image (18).

Images were obtained by means of Classic i-CAT CBCT (Imaging Sciences International, Inc, Hatfield,

Table 2 CBCT protocols used in this study

Voxel (mm)	Field of view (cm)	Acquisition time (s)	Kilovoltage (kV)	Milliamperage (mA)	Milliamperage-second (mAs)
0.12	06 × 16	40	120	08	36.12
0.20	08 × 16	40	120	08	36.12
0.25	08 × 16	40	120	08	36.12
0.30	08 × 16	20	120	08	18.45

Table 3 Sensitivity, specificity, accuracy, positive and negative predictive values for different voxel sizes

Voxel (mm)	Sensitivity	Specificity	Accuracy	NPV	PPV
0.12	0.58	0.58	0.58	0.31	0.80
0.20	0.52	0.62	0.54	0.30	0.80
0.25	0.46	0.71	0.52	0.30	0.82
0.30	0.34	0.73	0.44	0.27	0.79

NPV: Negative predictive value, PPV: Positive predictive value

PA, USA), according to four different protocols (Table 2). The images (Fig. 1) were evaluated blindly by five previously calibrated oral radiologists with at least 6 months experience of using CBCT, under dim light conditions. The presence or absence of ERR was evaluated in each of the nine regions of the root. All three-dimensional slices of the images were analyzed using XoranCat software version 3.0.34 (Xoran Technologies, Ann Arbor, MI, USA). The observers were allowed to use only the "zoom" tool. After 60 days, all images were re-evaluated. Inter- and intraobserver agreements were calculated by the kappa test (poor agreement, 0.40; moderate agreement, 0.40-0.59; good agreement, 0.60-0.74; excellent agreement, 0.75-1.00).

A decision matrix was used for statistical analysis, considering the following diagnostic outcomes: true positive (TP, i.e., clinical presence of ERR with positive CBCT diagnosis of ERR), true negative (TN, i.e., clinical absence of ERR with negative CBCT diagnosis of ERR), false negative (FN, i.e., clinical presence of ERR with negative CBCT diagnosis of ERR) and false positive (FP, i.e., clinical absence of ERR with positive CBCT diagnosis of ERR). The sensitivity (TP/TP + FN), specificity (TN/TN + FP), accuracy (TP + TN/TP + TN + FP + FN), positive predictive (TP/TP + FP) and negative predictive (TN/TN + FN) values were calculated for each voxel size and defect using SAS 9.1 software (SAS Institute, Cary, NC, USA).

Results

The mean intraobserver agreement was very good (0.91 for voxel resolution of 0.12 mm; 0.87 for voxel resolution of 0.20 mm; 0.88 for voxel resolution of 0.25 mm and 0.81 for voxel resolution of 0.30 mm). Considering the very high intraobserver Kappa values, interobserver agreement was calculated based on the first readings only. The mean Kappa values for interobserver agreement were very good for 0.12 mm, 0.20 mm, and 0.25 mm (0.89, 0.82 and 0.82, respectively) and good for 0.30 mm voxel resolution (0.74).

The sensitivity, specificity and accuracy, positive and negative predictive values are shown in Table 3. The sensitivity values tended to decrease and the specificity values increased with an increase in the voxel size. Accuracy values showed that the 0.12 mm voxel gave the best result; the 0.20 mm and 0.25 mm voxels were similar. Positive and negative predictive values increased with small voxel sizes, except the negative predictive value in 0.25 mm, which demonstrated the highest value.

Table 4 presents sensitivity, specificity, accuracy, and positive and negative predictive values of the different voxel sizes for small cavity (ERR1), medium cavity (ERR2) and large cavity (ERR3). The results revealed that as the cavity size increased, sensitivity, accuracy, positive and negative predictive values also increased.

When correlating the voxel size and root region (Table 5), better sensitivity, accuracy, positive and negative predictive values were obtained in the apical and middle third when there was a decrease in voxel size.

Discussion

The aim of this article was to determine the diagnostic efficacy of cone beam computed tomography in the detection of simulated external root resorption by changing scanning parameters resulting in different voxel sizes. We decided not to use the task specific filters or image

Table 4 Sensitivity, specificity, accuracy, positive and negative predictive values correlating the voxel size and diameter of the cavities

	Sensitivity			Specificity			Accuracy			NPV			PPV		
Voxel (mm)	ERR1	ERR2	ERR3	ERR1	ERR2	ERR3	ERR1	ERR2	ERR3	ERR1	ERR2	ERR3	ERR1	ERR2	ERR3
0.12	0.40	0.64	0.69	0.58	0.58	0.58	0.49	0.61	0.63	0.49	0.62	0.65	0.49	0.61	0.62
0.20	0.38	0.64	0.52	0.62	0.62	0.62	0.51	0.63	0.57	0.53	0.63	0.54	0.47	0.63	0.61
0.25	0.35	0.51	0.50	0.71	0.71	0.71	0.54	0.61	0.60	0.56	0.59	0.56	0.52	0.64	0.66
0.30	0.25	0.31	0.44	0.73	0.73	0.73	0.51	0.52	0.58	0.53	0.52	0.54	0.46	0.54	0.65

NPV: Negative predictive value, PPV: Positive predictive value, ERR1: small cavity, ERR2: medium cavity, ERR3: large cavity.

Table 5 Sensitivity, specificity, accuracy, positive and negative predictive values correlating the voxel size and root region

	Sensitivity			Specificity			Accuracy			NPV			PPV		
Voxel (mm)	Apical	Middle	Cervical	Apical	Middle	Cervical	Apical	Middle	Cervical	Apical	Middle	Cervical	Apical	Middle	Cervical
0.12	0.60	0.62	0.51	0.60	0.60	0.53	0.60	0.62	0.52	0.33	0.34	0.26	0.81	0.82	0.76
0.20	0.58	0.60	0.38	0.60	0.53	0.73	0.58	0.58	0.47	0.32	0.31	0.28	0.80	0.78	0.81
0.25	0.49	0.51	0.38	0.73	0.60	0.80	0.55	0.53	0.48	0.32	0.29	0.30	0.84	0.79	0.85
0.30	0.40	0.42	0.20	0.67	0.28	0.87	0.47	0.48	0.37	0.27	0.28	0.26	0.78	0.79	0.81

NPV: Negative predictive value, PPV: Positive predictive value

enhancement tools of CBCT because we wanted to focus on the effect of voxel sizes in the diagnosis of ERR.

The type of ERR simulation produced by drill was used in this study so that the diameter and depth could be standardized (19). This may not simulate the real clinical condition, in which root resorption lesions have more diffuse edges. However, simulated ERRs are easier to view by radiographic examination than natural ERR; future studies to develop standardized simulated resorption lesions of irregular shape are necessary.

No single two-dimensional (2D) imaging technique is readily available for accurate diagnosis of ERR. Previous studies have characterized the difficulties involved in making these diagnoses (7,20-22). Some studies demonstrated that when ERR simulations were evaluated by digital systems, CCD or PSP, similar (21) or better results (20) than conventional radiographic images were obtained. However, digital and conventional systems are still unable to provide precise views of incipient ERR, because they do not provide a 3D representation of real resorption. A CBCT image avoids overlapping structures and is efficient in detecting ERR (13). However, the dose of ionizing radiation to which the patient is exposed, is higher than that of conventional radiography and lower than that of multidetector computed tomography. Therefore, its application for the diagnosis of ERR should be further investigated.

In the present study, the evaluation of CBCT revealed that it was difficult to detect small cavities when higher voxel sizes were used. Nevertheless, it was shown to be reliable for ERR diagnosis since the 3D information increases its detection capability, especially when smaller voxel sizes were used. Liedke et al. (16) also compared the diagnostic ability of CBCT in detecting simulated ERR using the same device used in the present study, but with different voxel sizes (0.20 mm, 0.30 mm and 0.40 mm). The sensitivity, specificity and accuracy values obtained differed from those of the present study. They stated that the diagnostic performances of 0.20 and 0.30 mm voxels were similar (0.97 sensitivity values each). In the present study, the values obtained with 0.30 mm and 0.20 mm voxels were very different (0.34 and 0.52, respectively). This disparity in results may be due to the size of defects, since the smallest defect was 0.60 mm in diameter and 0.30 mm deep and the largest was 1.8 mm in diameter and 0.90 mm deep in the previous study. In the present study, the smallest defect was 0.26 mm in diameter and 0.08 mm deep, and the largest defect was 1.05 mm in diameter and 0.24 mm deep. Silveira et al. (13) also found that the increase in cavity size led to improved ability of single-slice computed tomography to identify the defects with a voxel size of 1.50 mm, and found that computed tomography was highly sensitive in detecting simulated ERR. They reported a detection rate of 0.71 for ERR; and sensitivity and specificity values of 0.89 and 1.00, respectively. However, they also used ERR simulating cavity sizes larger than those used in the present study, and showed that the smallest resorption detected were 0.60 mm in diameter and 0.30 mm deep.

Hahn et al. (15) reported high sensitivity, specificity

and accuracy values when evaluating cavities with similar sizes as those used in the present study, using a flat-panel volumetric computed tomography (fpVCT). Furthermore, the authors concluded that the fpVCT had a high potential for the detection and differentiation of simulated external root resorption cavities with potential pathologic relevance at an early stage. The absence of cavities was correctly identified in 53% of the cases only; in 47% it was wrongly classified as a degree 1 cavity (defect 0.30 mm in diameter and 0.08 mm deep). Consequently, it was shown that there is no ideal image for diagnosis. The above study used a 0.07 mm voxel, whereas the smallest voxel used in the present study was 0.12 mm. Thus, it is difficult to make a direct comparison of the results. The influence of voxel size was confirmed in the present study; the smaller the voxel size, easier the ERR detection. Moreover, the authors pointed out that the radiation dose required for a complete fpVCT evaluation of the head was too high when compared with the radiation dose used in conventional radiographs and multislice computed tomography.

Recently, Alqerban et al. (14) compared the efficacy of two CBCT devices in diagnosing simulated ERR in maxillary lateral incisors associated with impacted upper canines. The voxel sizes used in the devices were 0.125 mm (3D Accuitomo-XYZ Slice View Tomograph) and 0.133 mm (Scanora 3D). In cavities 0.16 mm in diameter and 0.15 mm deep (similar to the medium cavity used in the present study) and 0.30 mm (similar to the large cavity used in the present study), only 62.5% and 87.5% were viewed in Accuitomo, and 50% and 62.5% were viewed in Scanora, respectively. In the present study, when the 0.12 mm voxel was used, 64.4% and 68.8% were identified by CBCT. The values obtained by the two CBCT devices were similar. Moreover, it was observed that the voxel size and cavity size influenced the result. Theoretically, smaller voxel sizes provide a better image resolution. This could be explained by the quantum noise, which is fundamentally related to image quality and dependent on the radiation dose, transmissibility of tissues and voxel size. Quantum noise is the main determinant of contrast resolution and spatial resolution, which constitute the main determinants of overall image quality (12).

In agreement with our study, Neves et al. (19) found that the diagnosis of ERR was easier when the cavities were located in the middle and apical root thirds, especially with lower voxel sizes. However, these results did not agree with those of Silveira et al. (13), who observed that ERR in the apical root third was the most difficult to diagnose. This difference could be attributed to the higher voxel size and computed tomography device used in the study.

In the present study, positive and negative predictive values were lower than those reported by others (16). This can be attributed to the difference in the size of the cavities. Moreover, they depend on the prevalence of the disease. Similar to the study by Liedke et al. (16), we calculated positive and negative predictive values based on the prevalence of ERR in the experimental setup (in the present study 77%). In the real clinical situation where the prevalence is lower, the difference between positive predictive values with different voxel sizes becomes lower, as with the absolute positive predictive value.

The Classic i-Cat CBCT images resulted in decrease in sensitivity without jeopardizing specificity for detection of ERR. The highest specificity values were obtained with the voxel sizes 0.25 and 0.30 mm. This can be justified because the defect dimensions were smaller than the voxel resolution, which can mask small cavities.

The SEDENTEXCT guideline (Guidelines on CBCT for dental and maxillofacial radiology. http://www.sedentexct.eu/) suggests that CBCT examination should not be used indiscriminately for all patients. We believe that CBCT should not be used as a routine method for ERR diagnosis, but it should be recommended when lesions were suspected in routine periapical radiographs pre, during or post orthodontic therapy, especially in the most susceptible cases such as roots with abnormal shape, short roots, dental trauma, endodontically treated teeth and in cases of hypodontia (23). Kapila et al. (24) also recommended CBCT to be used in selected orthodontic cases in which conventional radiography cannot supply satisfactory diagnostic information, like cleft palate patients, for assessment of unerupted tooth position and supernumerary teeth, for identification of root resorption and for planning orthognathic surgery. Furthermore, according to Estrela et al. (25), CBCT scans were better than periapical radiographs in detecting ERR when root region, root surface and extension were impossible to determine.

The low radiation dose to the patient should also be mentioned and the principle of ALARA (As Low as Reasonably Achievable) should always be taken in consideration. Torres et al. (26) observed that the radiation dose for CBCT (Classic i-CAT) examination is directly related to the acquisition time and milliamperage. Since we used the same acquisition time, kV and mA for the 0.12, 0.20 and 0.25 mm voxel sizes, the radiation exposure was equal. Based on our results, we recommend the 0.12 mm voxel size to evaluate ERR, due to high sensitivity and PPV values. Although the mA

and acquisition time in 0.30 mm voxel size were smaller, resulting in a lower radiation exposure, the sensitivity was poor.

An in vitro study has some limitations. Only the imaging test was evaluated, whereas clinical parameters such as pulp vitality, history of trauma or orthodontic therapy, which can aid in the diagnosis of ERR, were not. Further studies with multi-rooted teeth and other tomography devices are necessary. Although it is difficult to perform, in vivo research could be conducted. Additionally, CBCT image tools were not used in our study; since they can improve the diagnosis of ERR.

In conclusion, it is important to use the best protocol in CBCT for detection of ERR in order to obtain early diagnosis of this pathology and for the most conservative management. In the present study, ERR was more easily diagnosed when a smaller voxel size was used.

Acknowledgments

The authors would like to thank Flávia Maria de Moraes Ramos-Perez (Department of Oral Radiology, Federal University of Pernambuco - UFPE) for her assistance in this study.

References

1. Leach HA, Ireland AJ, Whaites EJ (2001) Radiographic diagnosis of root resorption in relation to orthodontics. Br Dent J 190, 16-22.
2. Abuabara A (2007) Biomechanical aspects of external root resorption in orthodontic therapy. Med Oral Patol Oral Cir Bucal 12, E610-613.
3. Mohandesan H, Ravanmehr H, Valaei N (2007) A radiographic analysis of external apical root resorption of maxillary incisors during active orthodontic treatment. Eur J Orthod 29, 134-139.
4. Artun J, Van't Hullenaar R, Doppel D, Kuijpers-Jagtman AM (2009) Identification of orthodontic patients at risk of severe apical root resorption. Am J Orthod Dentofacial Orthop 135, 448-455.
5. Owman-Moll P, Kurol J (2000) Root resorption after orthodontic treatment in high- and low-risk patients: analysis of allergy as a possible predisposing factor. Eur J Orthod 22, 657-663.
6. Topkara A (2011) External apical root resorption caused by orthodontic treatment: a review of the literature. Eur J Paediatr Dent 12, 163-166.
7. Andreasen FM, Sewerin I, Mandel U, Andreasen JO (1987) Radiographic assessment of simulated root resorption cavities. Endod Dent Traumatol 3, 21-27.
8. Kurol J, Owman-Moll P, Lundgren D (1996) Time-related root resorption after application of a controlled continuous orthodontic force. Am J Orthod Dentofacial Orthop 110, 303-310.
9. Bernier-Rodriguez JA, Sidow SJ, Joyce AP, McNally K, McPherson JC 3rd (2008) Radiographic interpretation of experimental lesions in radicular tooth structure of human maxillary anterior teeth. J Endod 34, 1466-1469.
10. Patel S, Dawood A, Wilson R, Horner K, Mannocci F (2009) The detection and management of root resorption lesions using intraoral radiography and cone beam computed tomography - an in vivo investigation. Int Endod J 42, 831-838.
11. Ziegler CM, Woertche R, Brief J, Hassfeld S (2002) Clinical indications for digital volume tomography in oral and maxillofacial surgery. Dentomaxillofac Radiol 31, 126-130.
12. Miracle AC, Mukherji SK (2009) Conebeam CT of the head and neck, part 1: physical principles. AJNR Am J Neuroradiol 30, 1088-1095.
13. da Silveira HL, Silveira HE, Liedke GS, Lermen CA, Dos Santos RB, de Figueiredo JA (2007) Diagnostic ability of computed tomography to evaluate external root resorption in vitro. Dentomaxillofac Radiol 36, 393-396.
14. Alqerban A, Jacobs R, Souza PC, Willems G (2009) In-vitro comparison of 2 cone-beam computed tomography systems and panoramic imaging for detecting simulated canine impaction-induced external root resorption in maxillary lateral incisors. Am J Orthod Dentofacial Orthop 136, 764. e1-11.
15. Hahn W, Fricke-Zech S, Fricke J, Gruber RM, Dullin C, Zapf A, Hannig C, Kubein-Meesenburg D, Sadat-Khonsari R (2009) Detection and size differentiation of simulated tooth root defects using flat-panel volume computerized tomography (fpVCT). Oral Surg Oral Med Oral Pathol Oral Radiol Endod 107, 272-278.
16. Liedke GS, da Silveira HE, Silveira HL, Dutra V, de Figueiredo JA (2009) Influence of voxel size in the diagnostic ability of cone beam tomography to evaluate simulated external root resorption. J Endod 35, 233-235.
17. Soares CJ, Fonseca RB, Gomide HA, Correr-Sobrinho L (2008) Cavity preparation machine for the standardization of in vitro preparations. Braz Oral Res 22, 281-287.
18. Özer SY (2011) Detection of vertical root fractures by using cone beam computed tomography with variable voxel sizes in an in vitro model. J Endod

37, 75-79.
19. Neves FS, Vasconcelos TV, Vaz SLA, Freitas DQ, Haiter-Neto F (2012) Evaluation of reconstructed images with different voxel sizes of acquisition in the diagnosis of simulated external root resorption using cone beam computed tomography. Int Endod J 45, 234-239.
20. Westphalen VP, Gomes de Moraes I, Westphalen FH, Martins WD, Souza PH (2004) Conventional and digital radiographic methods in the detection of simulated external root resorptions: a comparative study. Dentomaxillofac Radiol 33, 233-235.
21. Kamburoğlu K, Tsesis I, Kfir A, Kaffe I (2008) Diagnosis of artificially induced external root resorption using conventional intraoral film radiography, CCD, and PSP: an ex vivo study. Oral Surg Oral Med Oral Pathol Oral Radiol Endod 106, 885-891.
22. Stratemann SA, Huang JC, Maki K, Miller AJ, Hatcher DC (2008) Comparison of cone beam computed tomography imaging with physical measures. Dentomaxillofac Radiol 37, 80-93.
23. Lopatiene K, Dumbravaite A (2008) Risk factors of root resorption after orthodontic treatment. Stomatologija 10, 89-95.
24. Kapila S, Conley RS, Harrell WE Jr (2011) The current status of cone beam computed tomography imaging in orthodontics. Dentomaxillofac Radiol 40, 24-34.
25. Estrela C, Bueno MR, De Alencar AH, Mattar R, Valladares Neto J, Azevedo BC, De Araújo Estrela CR (2009) Method to evaluate inflammatory root resorption by using cone beam computed tomography. J Endod 35, 1491-1497.
26. Torres MGG, Campos PSF, Segundo NPN, Ribeiro M, Navarro M, Crusoé-Rebello I (2010) Evaluation of referential dosages obtained by cone-beam computed tomography examinations acquired with different voxel sizes. Dental Press J Orthod 15, 42 e1-4.