Journal of Oral Science, Vol. 54, No. 2, 159-163, 2012

Original

Relationship of maxillary incisors in complete dentures to the incisive papilla

Zakiah M. Isa and Laith M. Abdulhadi

Department of Prosthetic Dentistry, Faculty of Dentistry, University of Malaya, Kuala Lumpur, Malaysia

(Received 1 December 2011 and accepted 24 March 2012)

Abstract: We investigated the relationship of the maxillary central incisors to the incisive papilla in wearers of complete dentures. First, image analyzer software was used to examine the relationship of the midpoint of the incisive papilla to the labial surface of the maxillary central incisors on occlusal photographs of 120 maxillary casts from dentate Malaysian adults. Then, an Alma denture gauge was used to identify the position of the labial surface of the maxillary central incisors in relation to the midpoint of the incisive papilla in complete dentures from 51 patients who requested replacement dentures at the Faculty of Dentistry, University of Malaya. The mean incisor distance to the incisive papilla in dentate adults was 9.59 ± 1.00 mm, while the mean incisor distance to the incisive papilla in complete dentures was 6.34 ± 1.87 mm. Thus, in our sample of edentulous patients, the anterior teeth in complete dentures were positioned approximately 3 mm closer to the incisive papilla, as compared with the position of the central incisors in natural dentition, and did not duplicate the position of the natural anterior teeth. (J Oral Sci 54, 159-163, 2012)

Keywords: complete dentures; maxillary anterior teeth; dental aesthetics; incisive papilla.

Correspondence to Dr. Zakiah Mohd Isa, Department of Prosthetic Dentistry, Faculty of Dentistry, University of Malaya, 50603 Kuala Lumpur, Malaysia
Tel: +60-3-7967-4566
Fax: +60-3-7967-4535
E-mail: zakiah@um.edu.my

Introduction

Aesthetics is a primary concern for patients seeking prosthodontic treatment. In patients with complete dentures, the suitability of artificial teeth depends on the dentist's ability to provide adequate support to the upper lip by maintaining an undistorted philtrum and nasolabial grooves and ensure proper contact of the upper and lower lips at the vermillion border (1). The aim is for the maxillary anterior teeth to restore dentolabial relations that are in optimal harmony with the overall facial appearance, which entails restoring tissues in amounts and positions similar to those of the lost tissues (2).

In the absence of pre-extraction records, the incisive papilla is an anatomic landmark that can be used as an aid for anterior tooth positioning in edentulous patients (3-5). The horizontal relationship between the maxillary central incisors and the position of the incisive papilla is relatively constant. The conventional biometric guideline is 10 mm (2), with a range between 7 mm and 12-13 mm (6-8). In addition, a line connecting the tips of the maxillary canines was found to fall approximately 1 mm anterior or posterior to the center of the incisive papilla (2).

The above guidelines for the relationship of the incisive papilla to the anterior teeth depend on the ethnicity of the population studied and on whether measurements were made from the midpoint or distal surface of the incisive papilla (2,6-9). With gross resorption of the buccal plate after tooth extraction, the papilla may appear to be on the crest of the alveolar ridge, and in cases of more severe resorption it would appear to be in front of the ridge. The midpoint of the incisive papilla is more commonly used as the reference point, although the posterior part of the incisive papilla is more stable, as it undergoes the least

Fig. 1 Standardized position of the cast during digital imaging. Two metal rulers were positioned on a plane parallel to the occlusal plane for calibration of the measurements.

Fig. 2 An Alma denture gauge was used to measure the distance between the labial surface of the central incisors and the middle of the incisive papilla.

change after teeth have been extracted (2,9).

Another anatomic landmark that may be used in complete denture construction is the pterygomaxillary notch-incisive papilla plane, which is parallel to the occlusal plane that uses the mesiolabial incisal edge of the maxillary right central incisor as the anterior reference point and the mesiobuccal cusp tips of the maxillary first or second molars as the posterior reference point (8,10).

To improve aesthetic and functional outcomes with respect to patient requirements and desires, we investigated whether central incisors in complete dentures were placed in the same position as natural teeth, relative to the incisive papilla.

Materials and Methods

A total of 120 casts of maxillary arches from a sample of 49 Malays (23 men and 26 women), 34 Chinese (17 men and 17 women), and 37 Indians (17 men and 20 women) were measured. All subjects in the study were between 19 and 40 years of age, had intact permanent dentition (excluding third molars) with minimal attrition, and had regular dental arches with no history of orthodontic treatment. This study was approved by the Faculty of Dentistry, University of Malaya Medical Ethics Committee, and all subjects signed a participation consent form.

To ensure standardization of the casts, each cast was trimmed so that its base was parallel to the occlusal plane (with the mesiolabial incisal edge of the upper right centrals used as the anterior reference point), while the mesiobuccal cusp tips of the maxillary first molars were used as the posterior reference points. The use of this plane also ensures that the incisive papilla and the hamular notches were on the same plane, i.e., the pterygomaxillary notch-incisive papilla (HIP) plane (8). Each cast was placed on a flat surface with the reference points touching the surface in the most stable position. A line was then drawn along the sides of the base of the cast with a pencil attached to one arm of a geometric compass; the other arm was fixed on the reference plate. The cast was rotated so that a line drawn on the sides of the base of the cast was parallel to the occlusal plane. The excess base material was then trimmed by following the line drawn around the cast.

Standardized digital photographs from the occlusal surface of the casts were then taken. When taking the photographs, two metal rulers set at 90° to each other were used to standardize and calibrate measurements of the casts. The metal rulers were placed alongside the casts by using a retort stand and clamp and were on the same plane as the occlusal plane. All casts were photographed with the line joining the hamular notches parallel to the horizontal plane (Fig. 1).

The images were then uploaded to a computer for measurement with image analyzer software (Leica Qwin Lite Version 2, Leica Microsystems Imaging Solutions, Cambridge, UK). The distance between the line joining the mesial incisal edges of the central incisors to the midpoint of the incisive papilla was then determined. All measurements were made three times. The average of the three values was used as the final measure.

To confirm the validity of measurements made from the images, the distances between the labial surfaces

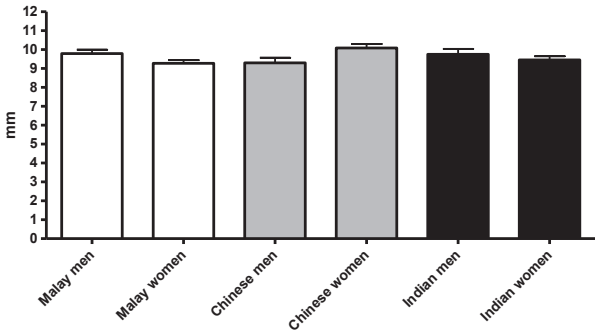

Fig. 3 The mean distance of the labial surface of the central incisors to the center of the incisive papilla in a sample from dentate patients was 9.59 ± 1.00 mm. There was no significant difference in relation to sex or ethnic group ($P > 0.05$).

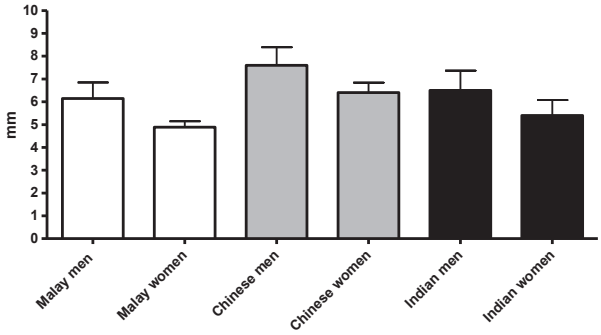

Fig. 4 The mean distance of the labial surface of the central incisors to the center of the incisive papilla in the edentulous sample was 6.34 ± 1.87 mm. No significant difference was found among the values in relation to sex or ethnic group ($P > 0.05$).

of the central incisors and the midpoint of the incisive papilla were directly measured on 10 randomly selected casts with a pair of Digimatic Vernier calipers (Mitutoyo Corp., Kawasaki, Japan). All measurements were made to the nearest 0.01 mm. The results were then compared to measurements made using the image analyzer. The differences were insignificant, and the use of the image analyzer throughout the study was thus deemed valid.

In addition, we used an Alma denture gauge (Asden Ltd., Cheshire, UK) to measure the position of the labial surface of the central incisors in 51 wearers of complete dentures who requested replacement of complete dentures in the Department of Prosthetic Dentistry, Faculty of Dentistry, University of Malaya. The edentulous subjects were 16 Malays (7 men and 9 women), 26 Chinese (10 men and 16 women), and 9 Indians (4 men and 5 women). The subjects were between 45 and 79 years old (mean, 59 years). They had been edentulous for a period of 6 months to 40 years (mean, 7.4 years) at the time of the study. The age of the dentures that the subjects were wearing was between 6 months and 40 years (mean, 4.5 years).

Each maxillary denture was placed on the base of the Alma denture gauge and positioned so that the denture was in the center of the gauge base, with the anterior teeth facing the vertical leg of the gauge. The stylus point of the gauge was then placed in the incisive papilla depression in the acrylic base by pushing down on the black stylus handle. The stylus naturally engaged the deepest part of the incisive papilla depression, which corresponds to the midpoint of the incisive papilla. The distance of the labial surface of the central incisors and the midpoint of the incisive papilla was read from the horizontal scale of the Alma denture gauge (Fig. 2). All measurements were recorded to the nearest 0.5 mm.

Statistical analysis

Data collected were coded and keyed into a computer. Statistical analysis of the data was carried out using SPSS 12.0 for Windows (SPSS Inc., Chicago, IL, USA). The means and standard deviations were calculated for the variables measured. Intergroup comparison of dentate and edentulous subjects, stratified by sex and ethnic group, was performed with one-way ANOVA followed by Tukey's post test. Results were considered statistically significant at $P < 0.05$. The Pearson's correlation test was used to analyze the correlation of denture age and duration of edentulousness with the position of the labial surface of the central incisors on the dentures relative to the midpoint of the incisive papilla.

Results

In dentate subjects, the mean distance of the labial surface of the central incisors to the incisive papilla was 9.59 ± 1.00 mm, and there was no significant difference in relation to sex or ethnic group ($P > 0.05$; Fig. 3). In complete dentures, the mean distance of the labial surface of the central incisors to the incisive papilla was 6.34 ± 1.87 mm (Fig. 4). The values ranged from 4 mm to 12 mm, with a mode of 5 mm. The maxillary central incisors were set at approximately 6 mm or less to the midpoint of the incisive papilla in 55% of edentulous subjects. There was a statistically significant difference between the distance of the labial surface of the maxillary anterior

teeth to the incisive papilla in dentate subjects and those wearing complete dentures ($P < 0.05$). Among edentulous subjects, Pearson correlation coefficients showed no correlation between this distance and either the duration of edentulousness or denture age.

Discussion

When using photographs or computer images to measure distances between intraoral landmarks, it is important to orient the casts in a standardized manner when taking the photographs and verify that the measured landmarks are in the same plane. This ensures that the results are valid and can be applied when artificial teeth are set on complete denture bases.

The present study used the HIP plane, which has been shown to be parallel to the natural occlusal plane and is defined anteriorly by the mesiolabial incisal edge of the upper right central incisor and posteriorly by the mesiobuccal cusp tips of the maxillary first molars (8,10). In a similar study of the relation between the incisive papilla and the labial surface of the central incisors in dentate and edentulous patients, the posterior border of the incisive papilla was used, as it seemed to be relatively stable even after bone resorption (6). However, because the present study used the HIP plane as the reference plane, the midpoint of the incisive papilla was used when making measurements, as the pterygomandibular notch–incisive papilla occlusal plane also uses the center of the incisive papilla as the anterior reference point.

In this study, the mean distance from the labial surface of the central incisors to the midpoint of the incisive papilla was 9.59 ± 1.00 mm (Fig. 5). This finding is within ranges noted in earlier studies (6-8), depending on whether the midpoint or distal surface of the incisive papilla was used for the measurements. As was the case in earlier studies, we found no significant difference in the mean values for men and women.

When attempting to place artificial teeth as close as possible to the positions previously occupied by natural teeth, the incisive papilla is a stable anatomic landmark that can be used as a biometric guideline in the placement of artificial central incisors and canines in maxillary complete dentures. This results in denture teeth occupying the “denture space” (2).

We found that the mean distance of the labial surface of the complete denture anterior teeth to the incisive papilla was 6.3 mm and that the teeth were located between 5 and 6 mm anterior to the incisive papilla in 55% of edentulous patients. These values were significantly lower than in dentate subjects (mean difference, approximately 3.3 mm), which indicates that the anterior teeth in the complete dentures were placed further posteriorly as compared with natural teeth. This was also noted in an earlier study that used calipers with modified tips and found that the mean difference was approximately 2 mm between dentate and complete denture wearers in the distance from the central incisor to the incisive papilla (6). None of our patients with complete denture who requested replacement dentures had any complaint relating to the aesthetics or phonetics of their dentures. This suggests that the positions of the anterior teeth in their dentures were satisfactory, even though they may not have been in the positions formerly occupied by their natural teeth.

Biometric guides in the oral cavity are useful as aids in positioning artificial teeth, as they indicate the position of the natural teeth. However, changes in the oral musculature and skin area due to ageing and residual ridge resorption might need to be accommodated (1). Therefore, determining the final placement of artificial anterior teeth – and achieving aesthetically pleasing results – also depends on the clinical observation and experience of the dentist and consideration of the patient's wishes. The denture gauge used in this study is a simple and quick method that allows clinicians to measure the position of the central incisors relative to the incisive papilla in wearers of complete dentures. In addition, when building occlusion rims, the denture gauge allows dental technicians to use the incisive papilla as a guide in patients with no existing dentures. Obviously, if an improvement is required by the dentist, additions to the wax occlusion rims may be made, and these can be verified at the jaw relationship stage when constructing the complete dentures.

Within the limitations of this study, we conclude that the biometric distance between the incisive papilla and the labial surface of the maxillary central incisors in dentate patients was not used as a guide in positioning artificial central incisors among wearers of complete denture patients in this study. In addition, a mean distance of 6.3 ± 1.9 mm was commonly used in our sample of edentulous patients.

References

1. McCord JF, Grant AA (2000) Registration stage III – selection of teeth. Br Dent J 188, 660-666.
2. Watt DM (1978) Tooth positions on complete dentures. J Dent 6, 147-160.
3. Sellen PN, Jagger DC, Harrison A (1999) Methods used to select artificial anterior teeth for the edentulous patient: a historical overview. Int J Prosthodont 12, 51-58.

4. Sellen PN, Jagger DC, Harrison A (2001) An assessment of the ability of dental undergraduates to choose artificial teeth which are appropriate for the age and sex of the denture wearer: a pilot study. J Oral Rehabil 28, 958-961.
5. Bissasu M (2004) Pre-extraction records for complete denture fabrication: a literature review. J Prosthet Dent 91, 55-58.
6. Grave AMH, Becker PJ (1987) Evaluation of the incisive papilla as a guide to anterior tooth position. J Prosthet Dent 57, 712-714.
7. Lau GCK, Clark RFK (1993) The relationship of the incisive papilla to the maxillary central incisors and canine teeth in Southern Chinese. J Prosthet Dent 70, 86-93.
8. Fu PS, Hung CC, Hong JM, Wang JC (2007) Three-dimensional analysis of the occlusal plane related to the hamular-incisive-papilla occlusal plane in young adults. J Oral Rehabil 34, 136-140.
9. Ehrlich J, Gazit E (1975) Relationship of the maxillary central incisors and canines to the incisive papilla. J Oral Rehabil 2, 309-312.
10. Jayachandran S, Ramachandran CR, Varghese R (2008) Occlusal plane orientation: a statistical and clinical analysis in different clinical situations. J Prosthodont 17, 572-575.