

Original

Prevalence of a second canal in the mesiobuccal root of permanent maxillary first molars from an Indonesian population

Harry H. Peeters¹⁾, Ketut Suardita²⁾ and Darmawan Setijanto³⁾

¹⁾Private Practice, Bandung, Indonesia

²⁾Department of Endodontics, School of Dentistry, University of Airlangga, Surabaya, Indonesia

³⁾Department of Public Health, School of Dentistry, University of Airlangga, Surabaya, Indonesia

(Received 6 May and accepted 11 October 2011)

Abstract: A sample of 308 extracted human permanent maxillary first molars from an Indonesian population was randomly selected. A rhomboid access cavity was made in all teeth in anticipation of identifying a second mesiobuccal canal (MB2). Ultrasonic tips were used to open the subpulpal groove to locate the second canal in the mesiobuccal root. Dentin was carefully removed from the trifurcation area at the expense of the mesial wall. If a second canal was located, a 0.8 C+ file was inserted into it until the file reached the apex. The prevalence of a second canal in the mesiobuccal root of the permanent maxillary first molar was 68.5% (95% CI: 63.1%-73.4%) in this population. Sections of the mesial root showed that the MB2 was a separate canal in 52.6% of the sample and a joined canal in 47.4%. The mean (SD) distance between MB1 and MB2 was 1.55 (0.66) mm. The data obtained from this study provide theoretical and experimental evidence to aid in the clinical management of the MB2 canal and may increase the success rate for root canal treatment of the maxillary first molar. (J Oral Sci 53, 489-494, 2011)

Keywords: dental operating microscope; *in vitro*; Indonesian population; second canal of mesiobuccal root; permanent maxillary first molar; ultrasonics.

Introduction

The main objective of endodontic treatment is thorough mechanical and chemical debridement of necrotic tissue and its complete obturation with an inert filling material. The major cause of endodontic failure when treating the first maxillary molar is failure to debride the entire root canal system, which usually occurs because the clinician was unable to detect additional root canals (1). It was reported that remnants of pulp tissue can be a reservoir for the growth of microorganisms, which may affect and compromise treatment outcomes (2-4). According to a study by Pomeranz and Fishelberg (5), clinicians are aware that the mesiobuccal root often contains two canals; however, the second canal (MB2) is often not observed (6). Therefore, the ability to locate all canals in the root canal system is an important determinant of successful endodontic treatment.

Maxillary molars often have two canals in the mesiobuccal root, as described by Hess in 1925 (7). In 1969, Wiene et al. (8) suggested that inability to locate, instrument, and obturate the MB2 canal could lead to endodontic failure. The anatomy of the roots of the maxillary first molars is very complex (9). Locating the MB2 canal is thus a challenge for the clinician in achieving successful treatment of maxillary molars (Fig. 1). If the prevalence of the MB2 is high in a population, time should be devoted to its location and treatment (10).

In an *in vivo* study by Hartwell and Bellizi (6), the prevalence of the MB2 canal was as low as 18.6%; however, an *in vitro* study by Kullid and Peters noted a prevalence of 95.2% (11). There are differences

Correspondence to Dr. Harry Huiz Peeters, Cihampelas 41 Bandung Jawa, Barat 40174, Indonesia
Tel: +62-224236007
Fax: +62-226127540
E-mail: h2huiz@cbn.net.id

Table 1 Incidence of two canals in the mesiobuccal root in laboratory and clinical studies

No. of canals and apices	No. of studies cited	No. of teeth (canal studies)	1 canal	≥ 2 canals
Mesiobuccal root (Laboratory studies)	24	3235	38.9% (1259)	61.1% (1976)
Mesiobuccal root (Clinical studies)	13	5280	45.3% (2393)	54.7% (2887)

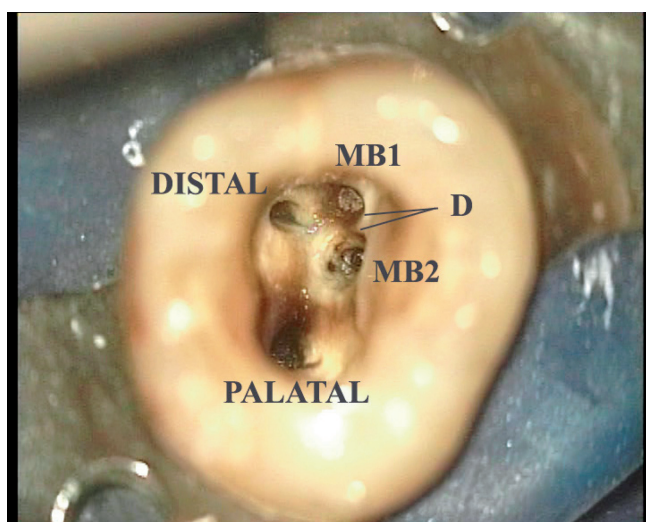


Fig. 1 Occlusal view of maxillary first molar with MB1 and MB2. D = distance between MB1 and MB2.

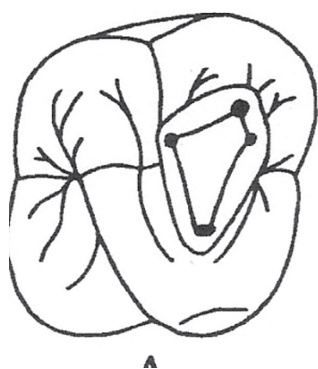

Fig. 2 Modified, rhomboidal access cavity.

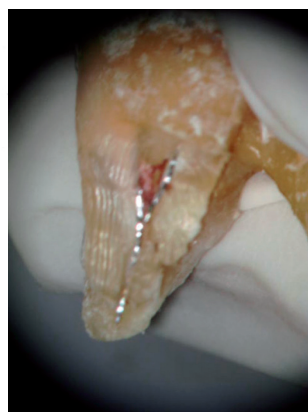


Fig. 3 Photograph showing the point where two canals join.

among reports in the research methodology used. Some studies investigated extracted teeth *in vitro*; others were performed in a clinical setting. Different methods for locating the MB2 result in varying prevalences.

In 1973, Seidberg et al. (12) and Pomeranz and Fishelberg (5) reported the results of studies performed *in vitro* and *in vivo*. The *in vitro* study of Seidberg et al. reported that 62% of 100 teeth had an MB2 canal, whereas the *in vivo* study found that 33.3% of 201 teeth

Table 2 Result of investigation of second mesiobuccal canals

Teeth	3 canals		4 canals (MB2)	
	No.	%	No.	%
Maxillary first molar (n = 308)	97	31.5	211	68.5

had an MB2 canal. The *in vitro* study of Pomeranz and Fishelberg revealed that 69% of 100 teeth had an MB2 canal, whereas the *in vivo* study reported that 31% of 100 teeth had two canals. Limited access and visibility in clinical settings, as well as the risk of perforation, may explain the lower prevalence of MB2 canals as compared with *in vitro* studies (Table 1). It is possible that the use of an operating microscope or loupes to enhance the view of the operative field might increase the ability to locate the MB2 canal (10). The purpose of this study was to determine the prevalence of MB2 in an Indonesian population. In addition, we investigated the presence of both separated and joined canals and the distance between the MB1 and MB2 canals. The data obtained from this study should provide theoretical and experimental evidence that will encourage clinicians to acquire a comprehensive knowledge of the anatomy of the permanent maxillary first molar, which may increase the success rate of root canal treatment of maxillary molars.

Materials and Methods

A sample of 308 extracted human permanent maxillary first molars was randomly selected from an Indonesian population at the Dental Department of Airlangga University. There was no information available on the cause or time of extraction of the teeth. Informed written consent was obtained from each patient. This study was approved by the Ethics Committee of the Airlangga University.

First, the teeth were cleaned of calculus and remaining soft tissue by using an ultrasonic scaler. Then, they were rinsed under running tap water and dried. A rhomboid access cavity (Fig. 2) was made in all teeth to allow for proper preparation if an MB2 were found. Round and

Table 3 Number (%) of teeth that had secondary dentin, required deeper troughing, were perforated, or could not be negotiated

Teeth	Secondary dentin		Deeper troughing		Non-negotiable		Perforation	
	No.	%	No.	%	No.	%	No.	%
Maxillary first molar	6	2.8	28	13.3	18	8.5	5	2.4

Table 4 Location of MB2 canal orifice, relative to first mesiobuccal canal orifice

Teeth	Mean (mm)	SD
Maxillary first molar	1.55	0.66

Table 5 Configuration of MB2 canal in permanent maxillary first molars

Teeth	Separated		Joined	
	No.	%	No.	%
Maxillary first molar (<i>n</i> = 211)	111	52.6	100	47.4

fissure-round burs (Dentsply, Tulsa, OK, USA) were used. The teeth were stored in 5% sodium hypochlorite solution for three hours to dissolve any pulp tissue. After being dried, the teeth were individually numbered, from 1 to 308. The MB1 was located, and a 0.8 C+ file (Dentsply Maillefer, Ballaigues, Switzerland) was inserted into the MB1 canal until it reached the apex. Then, an ultrasonic tip (Suprasson Pmax Newtron; Satelec/Acteon, Mérignac, France) was used to open the subpulpal groove to locate the second canal in the mesiobuccal root. Dentin was removed carefully from the trifurcation area (at the expense of the mesial wall) and subpulpal groove. In some teeth, discolored dentin, which appeared to be a calcified canal, was reduced by 2 to 3 mm below the pulpal floor. When a second canal was located, a 0.8 C+ file was inserted into it until the file reached the apex. If a canal could be traced beyond the orifice and the apex could be reached, it was defined as negotiable.

When the MB2 was negotiated successfully, a 0.8 C+ file was inserted into MB1 to determine if it joined with MB2. If one of the files could not reach the apex, it was considered to be a joined canal. To confirm this, with files inserted into the MB1 and MB2 canals, the mesiobuccal roots were carefully cut from the crown to the apex with a fissure bur to determine whether the canals were joined (Fig. 3) or separated. The distance between MB1 and MB2 at the base of the pulp cavity was then measured in millimeters. If this attempt was unsuccessful, more dentin was removed apically to follow the MB2 canal

deeper into the root with the aid of the ultrasonic tip. The attempt to negotiate the canal was continued until MB2 was successfully negotiated or perforation occurred.

The teeth in which an MB2 canal was not located, and those in which the canal was located but could not be negotiated, were investigated further by horizontal section. The mesiobuccal roots were sectioned horizontally from 2 to 8 mm from the apex and observed microscopically (Carl Zeiss, Oberkochen, Germany) at $\times 24$ magnification to verify the absence or presence of the MB2.

Results

The sample of 308 teeth comprised 211 teeth with an MB2 canal (68.5%; 95% CI, 63.1%-73.4%) and 97 teeth with no MB2 canal (31.5%; 95% CI, 31.5%-36.9%; Table 2). Of the 211 teeth with an MB2 canal, five suffered perforation, six required disclosure of the secondary dentin with the help of an ultrasonic tip, 28 required a deeper trough, and 18 were not negotiable (Table 3).

The distance between MB1 and MB2 was measured, and the tendency of the MB1 and MB2 root canals to be separated or joined at some point on the way down to the apex was recorded. The distance between MB1 and MB2 ranged from 0.3 mm to 3.8 mm. The mean (SD) distance was 1.55 (0.66) mm (95% CI, 1.46 mm-1.64 mm; Table 4). The location of the MB2 canal varied considerably in relation to the main orifices of the mesiobuccal canal. Of the 211 teeth with an MB2 canal, 111 had separated canals (52.6%) and 100 had joined canals (47.4%; Table 5).

Discussion

Morphologic variation in the anatomy of the root canal system should always be considered at the beginning of a treatment. Each case, independent of the type of tooth, should be examined clinically and radiologically in a thorough manner to detect possible anatomic anomalies. Endodontic treatment should be initiated with proper preparation to allow access to the cavity, which can ease the process of investigating and successfully detecting all root canal orifices (13).

The mesiobuccal root of the permanent maxillary first molar may have more than one or two canals; it

may also branch out from various sides and have lateral ramifications (7,14). Weine categorized the position of one or two canals into four groups (8), whereas Vertucci analyzed the anatomy of the root canal and proposed a classification that encompassed eight different types (15-17). However, we did not classify teeth according to either of these classification systems. Only the presence or absence of an MB2 was noted.

The ability to locate and clean all canals in a root canal system determines the eventual success of treatment; therefore, clinicians should consider the possibility that each tooth might have extra canals. All extra canals should be detected, if possible (18,19). The MB2 canal was selected as a model for this study because it is considered to be highly prevalent (11,20), yet can be elusive in many patients (6,21-23).

Of the 308 maxillary first molars studied, 211 had an MB2 canal (68.5%) and 97 did not (31.5%). This high prevalence of MB2 canals (Table 1) in an Indonesian population was comparable to findings published in other studies of similar populations (11,20,23,24). The presence of an MB2 was verified microscopically because detailed exploration of an apparent MB2 sometimes reveals it to be an orifice-like spot (21). However, not all of these secondary orifices lead to a true root canal. In a recent clinical study, 16% of all identified MB2 canals could not be traced beyond the orifice (23).

Negotiating the MB2 canals was much more challenging than locating them, possibly due to the ledge of dentin that frequently covers the orifice (6,22,24-27). Another difficulty is the tortuous pathway of some of these canals, which can include one or two abrupt curves in the coronal portion (11,28). This might explain why *in vitro* studies have generally shown a higher prevalence of MB2 canals than have *in vivo* studies (29).

Of the 211 molars with an MB2, five were perforated, which shows that perforation can occur even when microscopy and ultrasonic devices are used. Clinicians who always work with a microscope have a narrower field of vision and might not have a satisfactory overview. A wise clinician will stop excavating the dentin if a canal orifice cannot be found, as serious errors can arise from overenthusiastic or inappropriate attempts to locate canals.

This *in vitro* study showed that second orifices of six molars were covered by secondary dentin; therefore, such orifices could only be discovered by using an ultrasonic tip. Twenty-eight molars required a deeper trough; however, such procedures may not be recommended clinically due to the risk of perforation. In 18 molars, further negotiation was inhibited by canal occlusion due

to calcification and the teeth were therefore observed microscopically.

The openings of MB2 canals are localized on an imaginary line between the MB1 and palatal orifice (23). The distance between the orifices of the MB1 and MB2 was 0.3 mm to 3.8 mm (mean: 1.55 mm; SD: 0.6 mm). Owing to its proximity to the MB1, it is often difficult to locate the MB2 orifice. Because detection of the MB2 orifice is not easy, root canal treatment should be performed under microscopy with the help of an ultrasonic tip. The microscope provides good visibility and the ultrasonic tip can create a deeper trough in the dentin. Use of these devices increases the likelihood of finding MB2 orifices (10,29-34).

If magnification is not used during root canal treatment, modification of the access site to form a rhomboid shape is indicated (Fig. 2), as it will increase the number of MB2 orifices that can be located and properly treated (35).

The frequency of teeth with two MB canals with separate foramina was 52.6%, whereas the percentage of joined foramina was 47.4%. Clinically, different canal configurations might require varying root canal procedures to facilitate complete cleaning, disinfection, and canal obturation.

The root canal system of the mesiobuccal root of the permanent maxillary first molar frequently has more than one canal. Clinicians need to be mindful of the possible presence of a second mesiobuccal canal, which should motivate change in the routine practice of clinical endodontic treatment. We found that the prevalence of a second mesiobuccal canal in the mesiobuccal root of permanent maxillary first molars was 68.5% in an Indonesian population. The data obtained from this study provide theoretical and experimental evidence that is likely to aid in the clinical management of MB2 canals and increase the success rate for treatment of root canals in permanent maxillary molars.

References

1. Kontakiotis EG, Tzanetakakis GN (2007) Four canals in the mesial root of a mandibular first molar. A case report under the operating microscope. *Aust Endod J* 33, 84-88.
2. Cheung GS (1996) Endodontic failures – changing the approach. *Int Dent J* 46, 131-138.
3. Hoen MM, Pink FE (2002) Contemporary endodontic retreatments: an analysis based on clinical treatment findings. *J Endod* 28, 834-836.
4. Nair PN (2004) Pathogenesis of apical periodontitis and the causes of endodontic failures. *Crit Rev*

- Oral Biol Med 15, 348-381.
5. Pomeranz HH, Fishelberg G (1974) The secondary mesiobuccal canal of maxillary molars. *J Am Dent Assoc* 88, 119-124.
 6. Hartwell G, Bellizzi R (1982) Clinical investigation of in vivo endodontically treated mandibular and maxillary molars. *J Endod* 8, 555-557.
 7. Hess W (1925) The anatomy of the root-canals of the teeth of the permanent dentition. John Bale Sons and Danielsson, London, 32-35.
 8. Weine FS, Healey HJ, Gerstein H, Evanson L (1969) Canal configuration in the mesiobuccal root of the maxillary first molar and its endodontic significance. *Oral Surg Oral Med Oral Pathol* 28, 419-425.
 9. Vertucci FJ, Haddix JE, Britto LR (2006) Tooth morphology and access cavity preparation. In: *Pathways of the pulp*, 9th ed, Cohen S, Hargreaves KM eds, Elsevier Mosby, St Louis, 203.
 10. Bührley LJ, Barrows MJ, BeGole EA, Wenckus CS (2002) Effect of magnification on locating the MB2 canal in maxillary molars. *J Endod* 28, 324-327.
 11. Kulild JC, Peters DD (1990) Incidence and configuration of canal systems in the mesiobuccal root of maxillary first and second molars. *J Endod* 16, 311-317.
 12. Seidberg BH, Altman M, Guttuso J, Suson M (1973) Frequency of two mesiobuccal root canals in maxillary permanent first molars. *J Am Dent Assoc* 87, 852-856.
 13. Christie WH, Thompson GK (1994) The importance of endodontic access in locating maxillary and mandibular molar canals. *J Can Dent Assoc* 60, 527-536.
 14. Eder A, Kantor M, Nell A, Moser T, Gahleitner A, Schedle A, Sperr W (2006) Root canal system in the mesiobuccal root of the maxillary first molar: an in vitro comparison study of computed tomography and histology. *Dentomaxillofac Radiol* 35, 175-177.
 15. Vertucci FJ (1984) Root canal anatomy of the human permanent teeth. *Oral Surg Oral Med Oral Pathol* 58, 589-599.
 16. Vertucci FJ, Gegauff A (1979) Root canal morphology of the maxillary first premolar. *J Am Dent Assoc* 99, 194-198.
 17. Vertucci FJ (1978) Root canal morphology of mandibular premolars. *J Am Dent Assoc* 97, 47-50.
 18. Slowey RR (1979) Root canal anatomy: road map to successful endodontics. *Dent Clin North Am* 23, 555-573.
 19. Weine FS (1995) Non surgical re-treatment of endodontic failures. *Compend Contin Educ Dent* 16, 324-335.
 20. Gilles J, Reader A (1990) An SEM investigation of the mesiolingual canal in human maxillary first and second molars. *Oral Surg Oral Med Oral Pathol* 70, 638-643.
 21. Henry BM (1993) The fourth canal: its incidence in maxillary first molars. *J Can Dent Assoc* 59, 995-996.
 22. Fogel HM, Peikoff MD, Christie WH (1994) Canal configuration in the mesiobuccal root of the maxillary first molar: a clinical study. *J Endod* 20, 135-137.
 23. Stropko JJ (1999) Canal morphology of maxillary molars: clinical observations of canal configurations. *J Endod* 25, 446-450.
 24. Imura N, Hata GI, Toda T, Otani SM, Fagundes MI (1998) Two canals in mesiobuccal roots of maxillary molars. *Int Endod J* 31, 410-414.
 25. Nosonowitz DM, Brenner MR (1973) The major canals of the mesiobuccal root of the maxillary 1st and 2nd molars. *N Y J Dent* 43, 12-15.
 26. Neaverth EJ, Kotler LM, Kaltenbach RF (1987) Clinical investigation (in vivo) of endodontically treated maxillary first molars. *J Endod* 13, 506-512.
 27. Ibarrola JL, Knowles KI, Ludlow MO, McKinley IB Jr (1997) Factors affecting the negotiability of second mesiobuccal canals in maxillary molars. *J Endod* 23, 236-238.
 28. Stabholz A, Goultzschin J, Friedman S, Korenhouser S (1984) Crown-to-root ratio as a possible indicator of the presence of a fourth root canal in maxillary first molars. *Israel J Dent Sci* 1, 85-88.
 29. Alaçam T, Tinaz AC, Genç O, Kayaoglu G (2008) Second mesiobuccal canal detection in maxillary first molars using microscopy and ultrasonics. *Aust Endod J* 34, 106-109.
 30. Yoshioka T, Kikuchi I, Fukumoto Y, Kobayashi C, Suda H (2005) Detection of the second mesiobuccal canal in mesiobuccal roots of maxillary molar teeth ex vivo. *Int Endod J* 38, 124-128.
 31. Smadi L, Khraisat A (2007) Detection of a second mesiobuccal canal in the mesiobuccal roots of maxillary first molar teeth. *Oral Surg Oral Med Oral Pathol Oral Radiol Endod* 103, e77-81.
 32. Nakano K, Kawashima N, Suda H (2008) Usefulness of operative microscope and ultrasonic tip to identify the second mesiobuccal canal of the maxillary first molar. *Nihon Shika Hozongaku*

Zasshi 51, 457-463. (in Japanese)

33. Sempira HN, Hartwell GR (2000) Frequency of second mesiobuccal canals in maxillary molars as determined by use of an operating microscope: a clinical study. *J Endod* 26, 673-674.
34. Görduysus MO, Görduysus M, Friedman S (2001) Operating microscope improves negotiation of second mesiobuccal canals in maxillary molars. *J Endod* 27, 683-686.
35. Weller RN, Hartwell GR (1989) The impact of improved access and searching techniques on detection of the mesiolingual canal in maxillary molars. *J Endod* 15, 82-83.