

Case Report

Management of an extensive invasive root resorptive lesion with mineral trioxide aggregate: a case report

Farzad Danesh¹⁾, Kasra Karamifar²⁾ and Paul V. Abbott³⁾

¹⁾Department of Endodontics, Dental Branch, Islamic Azad University, Tehran, Iran

²⁾Post Graduate Department of Endodontics, Dental Branch, Islamic Azad University, Tehran, Iran

³⁾Clinical Dentistry, School of Dentistry, University of Western Australia, Perth, Australia

(Received 14 February and accepted 17 June 2011)

Abstract: External invasive resorption is an uncommon but aggressive type of external resorption. This report outlines the management of an advanced case of external invasive resorption with mineral trioxide aggregate (MTA). The clinical and radiographic follow-up after 60 months revealed a functional tooth with a stable periodontal condition and no evidence of any further resorption. (*J Oral Sci* 53, 397-401, 2011)

Keywords: invasive cervical root resorption; mineral trioxide aggregate; orthograde treatment.

Introduction

External invasive resorption (EIR) is a localized resorptive process of teeth that commences in the root just below the epithelial attachment (1). It is uncommon and it can be a severe or aggressive pathological condition that resorbs dentin, enamel, and cementum (1). The exact cause of this condition is unknown but a change in the composition of, or damage to, the cementum can alter this protective layer and make it less resistant, which seems to be a prerequisite for initiation of the resorptive process. Several predisposing factors have been suggested for this condition, including trauma, orthodontic treatment, intracoronary bleaching, dento-alveolar

surgery, bruxism, periodontal disease and periodontal treatment (1). The most frequently used classification for EIR is Heithersay's classification (1).

The usual asymptomatic nature of EIR can be explained by the minimal pulp involvement due to the protective activity of the predentin layer (1). However, some advanced cases develop symptoms of pulp disease when this protective layer is invaded and the pulp is exposed to ingress of oral micro-organisms through the resorptive defect (1). The clinical presentation of EIR depends mainly on the extent of the resorption. The crown of the tooth may appear pink if there is a sufficient amount of resorption within the crown, but in most cases, there are no visual signs of resorption (2). Some patients may report an unusual or different sensation when brushing their teeth but many cases are discovered coincidentally during routine examination or when a radiograph has been taken for some other purpose.

EIR is usually diagnosed by clinical and radiographic examination. The differential diagnosis for EIR includes other forms of external root resorption and internal root resorption (3). It is important to differentiate between the different types of resorption since the management of each type is different (4).

The management of EIR includes careful case selection, curettage, cauterization (such as by the application of trichloroacetic acid) and restoration of the defect (1). Root canal treatment is not necessary unless the pulp is exposed during treatment or if there are signs of concurrent pulp disease. Some cases will require surgical exposure of the resorptive defect in order to have sufficient access for the above procedure, but many cases can be managed without surgical access. The resorptive

Correspondence to Dr. Kasra Karamifar, Post graduate Department of Endodontics, Dental Branch, Islamic Azad University, 10th Neyestan Ave., Pasdaran Ave., Tehran, Iran
Tel: +98-21-22564573
Fax: +98-21-22564573
E-mail: kasra.karamifar@gmail.com

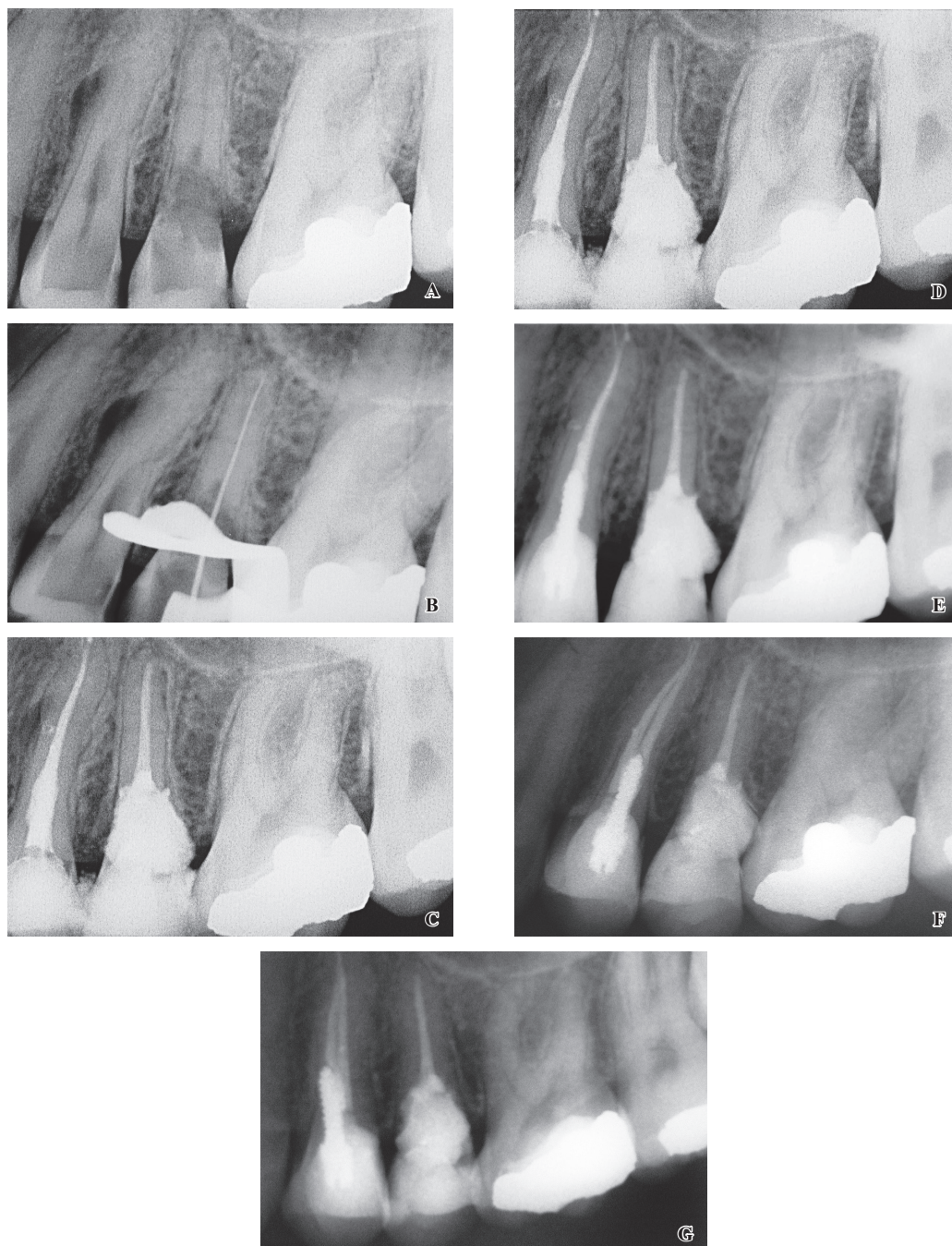


Fig. 1 A, Pre-operative periapical radiograph showing extensive resorption of the upper left second premolar tooth. There is also root resorption and a lateral radiolucent lesion associated with the upper left first premolar tooth. B, Working length determination of the upper left second premolar tooth. C, Calcium hydroxide placement in the upper left second premolar tooth and working length determination of the upper left first premolar tooth. Also, note the instrument separation in the apical part. D, Post-operative periapical radiograph showed the jagged border of MTA in the upper left second premolar tooth. Also, the sealer extruded into the lateral canal of tooth 24 connecting the internal resorptive process with the external inflammatory lesion evidenced by the lateral radiolucency. E, A 12-month follow-up radiograph showing the excellent periodontal condition of the upper left second premolar tooth and clear evidence of healing of the lateral lesion associated with the internal inflammatory resorptive process within the upper left first premolar tooth. F, A 5-year follow-up radiograph showing crestal bone around the upper left second premolar tooth. Complete healing of the lateral radiolucent lesion associated with the upper left first premolar tooth can be seen. G, Another 5-year follow-up radiograph from a different angle.

defect can be restored with various materials but glass ionomer (1) and mineral trioxide aggregate (5) have been recommended.

Mineral trioxide aggregate (MTA) was first introduced as a root-end filling material and later gained popularity for clinical application in pulp-capping, perforation repair and filling of open apex root canals (6). MTA has many favorable properties, including good sealing ability, biocompatibility, mechanical strength, capacity to promote hard tissue formation, radiopacity, ability to set in moist conditions and inhibition of bacteria (7).

This aim of this report is to outline the management and outcome of an advanced case of external invasive root resorption.

Case Report

A 21-year-old healthy woman with non-contributory medical history presented for dental examination. She had not received any orthodontic or periodontal treatment. The patient complained of vague pain in her upper left quadrant. Clinical examination revealed no caries in the teeth and all teeth in the upper left quadrant responded normally to cold pulp sensitivity testing. The teeth were not tender to percussion or palpation and there were no periodontal pockets. The two premolar teeth had no restorations. A periapical radiograph (Fig. 1A) revealed that the first premolar tooth (tooth 24) had caries on the distal aspect, a resorptive lesion in the cervical third of the root and a radiolucency adjacent to the mesial aspect of the root at about mid-root level. This radiograph also showed an extensive resorptive lesion involving the cervical third of the root and the crown of the second premolar (tooth 25).

The extensive nature of the resorption in tooth 25 as seen on the radiograph initially made it difficult to differentiate between internal inflammatory resorption and EIR. However, the pulp response to cold sensitivity testing and the irregular radiolucency extending from mesial to distal in tooth 25 led to the diagnosis of an advanced case of external invasive root resorption. According to the Heithersay classification (1), this lesion was considered to be Class 3. The patient was informed about the condition and its probable effect on the overall prognosis of this tooth. Consent for treatment was received from the patient and treatment was initiated in an attempt to retain this tooth.

Initially, tooth 24 was diagnosed as having EIR, but subsequently this diagnosis was altered once an angled radiograph that was taken to establish the working length of 25 was viewed (Fig. 1B). This angled radiograph indicated that the resorption in tooth 24 had changed

the outline of the buccal canal in the cervical third of the root and hence the diagnosis was changed to internal inflammatory resorption, despite the positive response to pulp testing at the initial examination. However, this was considered to have possibly come from the pulp in the palatal canal. Root canal treatment was recommended for this tooth.

At the first appointment, under local anesthesia and rubber dam isolation, an access cavity was prepared in tooth 25. After coronal root canal preparation using Pre-RaCe (FKG Dentaire, La Chaux-de-Fonds, Switzerland) rotary NiTi rotary instruments, the working length was determined by digital radiography (Ritter, Progeny, Lincolnshire, IL, USA) (Fig. 1B). Excessive bleeding was noted during shaping and cleaning of the root canal and this persisted until all the tissue was removed. The apical root canal was prepared to a size #40, 04 tapered file. Sodium hypochlorite (5.25%) was used as the irrigant. Calcium hydroxide was then placed as an intracanal dressing and the access cavity was filled with Cavit (ESPE America, INC., Norristown, PA, USA).

At the next appointment, root canal treatment was commenced on tooth 24. Working length was established radiographically (Fig. 1C) and the root canals were shaped, cleaned and filled with calcium hydroxide. The access cavity was temporarily filled with Cavit.

Subsequently at another appointment, the calcium hydroxide was removed from both teeth using files with NaOCl and EDTA as irrigants, followed by irrigation with normal saline. No bleeding was noted at this appointment. The root canals were filled with gutta-percha and AH 26 cement (Dentsply, Konstanz, Germany) with a lateral condensation technique. In 25, excess gutta-percha was removed to a level just apical to the resorptive defect. White MTA (Pro-Root, Dentsply Tulsa, Tulsa, OK, USA) was mixed according to the manufacturer's instructions. It was carried to the resorption site with an MTA gun (ProRoot™ MTA Delivery Gun, Dentsply Maillefer) and packed with finger pluggers and indirect ultrasonic application. A moist cotton pellet was placed to help hydrate the MTA during setting. The access cavity was temporarily filled with Cavit and a post-operative radiograph was taken. Despite the proximity of the lesion to the gingival sulcus, no MTA was detected clinically. One day later, the Cavit was removed and MTA hardness was confirmed. The crown of the tooth was then restored with composite resin (Filtek Z250, 3M ESPE, St Paul, MN, USA) (Fig. 1D) and the patient was scheduled for a review of these teeth after 6 months.

The patient was not available for review at 6 months due to relocation, but she returned for review after 12

months. A periapical radiograph was taken (Fig. 1E) and this showed that the width of the periodontal ligament space of 25 had returned to normal and there was no radiolucency associated with the MTA. Tooth 24 displayed good healing of the mesial radiolucency. The next follow up was done 4 years later (that is, 5 years after treatment) and two radiographs (Fig. 1F, G) taken at different angles indicated that both teeth had normal periodontal ligament spaces with distinct crestal bone on both the mesial and distal aspects. No change or resorption of the MTA was seen. Palpation and percussion were in normal limits and there were no periodontal pockets.

Discussion

The management of EIR presents a challenge to clinicians and its prognosis depends highly on the extent of the resorption (1). In the case reported, the resorptive lesion in tooth 25 ceased after the lesion had been curetted to remove all invading cells and the defect was filled with MTA, as confirmed by the follow up radiographs. An internal approach was adopted to manage this lesion rather than a surgical (or external) approach but this necessitated root canal treatment as the pulp was exposed during this procedure. This approach was chosen to avoid patient anxiety, bone removal, time required for healing of the gingiva (8), and the very likely lack of attachment of the tissues following surgery due to the large defect created in the tooth root and the presence of an extensive restoration in this defect. The use of an internal approach can limit the size of the external opening of the lesion to its pre-operative size, which facilitates healing and reduces the loss of attachment.

The differential diagnosis for such lesions includes EIR, external replacement resorption, external inflammatory resorption and internal inflammatory resorption.

Radiography is the main diagnostic tool used to differentiate between these types of resorption and particularly between internal inflammatory and EIR as shown in Table 1. The usual radiographic appearance of EIR is an unchanged pulp space which can be seen to transverse through the resorptive area. The resorptive defect may appear as a uniform radiolucency with a rough outline and a fine radiopaque line that extends coronally and apically in the root and crown dentin (1). In advanced cases, a non-uniform preferential spread of resorption can be seen which may be the result of resorptive tissue penetrating in different directions (1). The adjacent alveolar bone may be resorbed which can simulate an intrabony defect (9), although this is not always visible radiographically. A change in the angulation of the radiograph would show no change in the location of the resorptive lesion with respect to the pulp space. The effects of angulation changes can be seen when Figure 1A is compared to the working length film (Fig. 1B).

MTA can be washed out in the presence of blood, which may lead to changes in the physical and chemical properties of MTA. Also, blood may produce some porosity in MTA (10). Hence, calcium hydroxide was used to ensure removal of any remaining pulp debris, invading tissues, and the invasive root resorptive lesion in the resorbed area as well as for hemostasis. Calcium hydroxide also has stabilizing and alkalizing effects on the intracanal environment, eliminates microorganisms, and inactivates their toxic products (11).

MTA was used in this case because of its excellent properties such as sealing ability, biocompatibility, inhibition of bacterial activity, and moisture resistance (7), which are important for resorption repair since there was a large area to fill and the material may have been exposed to tissue fluids. Although the external opening

Table 1 Diagnostic factors used to help differentiate between external invasive resorption and internal inflammatory resorption

Diagnostic factors	External invasive resorption	Internal inflammatory resorption
Margins	Rough, moth-eaten appearance, vary in density	Smooth and well-defined
Shape	Usually irregular and asymmetrical	Mostly symmetrical
Effect on outline of the root canal	Unaltered canal outline, unless extensive pulp invasion has occurred	Change in root canal anatomic configuration (usually oval-shaped)
Effect of change in radiograph beam angulation	Resorption relationship to the canal alters	Resorption remains associated with canal
Location	Initially occurs immediately below the epithelial attachment, then can spread coronally or apically	Can occur anywhere along the length of the pulp space
Bone resorption	Most have some resorption of adjacent bone especially in advanced lesions	No bone resorption unless the lesion has perforated the root or lateral canals exist

of the resorptive area was close to the gingival sulcus and relatively supracrestal, no transgingival connection resulting in periodontal pockets could be detected. The remaining tooth structure and supporting periodontal tissues served as a matrix for the placement of MTA in the resorptive defect.

The decision to conserve the tooth affected by EIR and to perform endodontic treatment was a matter of debate. As the crown seemed restorable and no communication existed between the gingival crevice and the underlying bone, conservation of the tooth was considered. Furthermore, the defect was accessible through the crown; therefore, surgery seemed unnecessary. Neither Ca(OH)_2 nor MTA are fully effective at stopping EIR although both can play a role. Ca(OH)_2 has some anti-resorptive effect as it can eliminate clastic cells, if any remain (11). MTA is unlikely to have this effect. The most effective way to stop EIR is to curette the lesion and remove and/or kill all invading cells. In addition, removal of the blood supply to any invading/resorbing cells that may remain is needed and therefore, filling of the defect with MTA plays a role in this aspect. MTA was also used as a means of repairing the defect (i.e., replacing lost tooth structure).

In conclusion, orthograde repair can be considered as a treatment modality in the management of EIR if there is no pulp involvement and connection with the gingival crevice. MTA is one material that can be used in these cases because of its excellent characteristics.

References

1. Heithersay GS (2004) Invasive cervical resorption. *Endod Topics* 7, 73-92.
2. Kim E, Kim KD, Roh BD, Cho YS, Lee SJ (2003) Computed tomography as a diagnostic aid for extracanal invasive resorption. *J Endod* 29, 463-465.
3. Smidt A, Nuni E, Keinan D (2007) Invasive cervical root resorption: treatment rationale with an interdisciplinary approach. *J Endod* 33, 1383-1387.
4. Trope M (2002) Root resorption due to dental trauma. *Endod Topics* 1, 79-100.
5. Pace R, Giuliani V, Pagavino G (2008) Mineral trioxide aggregate in the treatment of external invasive resorption: a case report. *Int Endod J* 41, 258-266.
6. Torabinejad M, Chivian N (1999) Clinical applications of mineral trioxide aggregate. *J Endod* 25, 197-205.
7. Pairokh M, Torabinejad M (2010) Mineral trioxide aggregate: a comprehensive literature review – Part I: chemical, physical, and antibacterial properties. *J Endod* 36, 16-27.
8. Ramfjord SP, Engler WO, Hiniker JJ (1966) A radioautographic study of healing following simple gingivectomy. II. The connective tissue. *J Periodontol* 37, 179-189.
9. Patel K, Darbar UR, Gulabivala K (2002) External cervical resorption associated with localized gingival overgrowth. *Int Endod J* 35, 395-402.
10. Fridland M, Rosado R (2003) Mineral trioxide aggregate (MTA) solubility and porosity with different water-to-powder ratios. *J Endod* 29, 814-817.
11. Gulabivala K, Searson LJ (1995) Clinical diagnosis of internal resorption: an exception to the rule. *Int Endod J* 28, 255-260.