

## Case Report

## The usefulness of three-dimensional imaging in the diagnosis and treatment of clinically ambiguous gingival swelling

Hiroaki Kabashima<sup>1)</sup>, Kunitaka Mizobe<sup>1)</sup>, Hiroyoshi Nakamuta<sup>2)</sup>, Hiroaki Fujiwara<sup>1)</sup>, Kazutoshi Okamura<sup>3)</sup>, Masako Unemori<sup>2)</sup>, Akifumi Akamine<sup>2)</sup>, Kazunori Yoshiura<sup>3)</sup> and Katsumasa Maeda<sup>1)</sup>

<sup>1)</sup>Department of Periodontology, Division of Oral Rehabilitation, Faculty of Dental Science, Kyushu University, Fukuoka, Japan

<sup>2)</sup>Department of Endodontology and Operative Dentistry, Division of Oral Rehabilitation, Faculty of Dental Science, Kyushu University, Fukuoka, Japan

<sup>3)</sup>Department of Oral and Maxillofacial Radiology, Faculty of Dental Science, Kyushu University, Fukuoka, Japan

(Received 5 February and accepted 2 May 2011)

**Abstract:** We evaluated and treated a 54-year-old woman with gingival swelling. Conventional intraoral and panoramic radiography did not provide sufficient information for either determining the cause of gingival swelling or planning treatment of clinical symptoms. The 3D Accuitomo XYZ Slice View Tomograph (3DX) is a compact dental computed tomography device that allowed for accurate identification and optimal treatment of the causes of gingival swelling. At four years after treatment, 3DX radiographs showed no abnormalities in treated teeth or healing of surrounding structures. We conclude that high-resolution 3D images obtained with 3DX promise to be very effective for diagnosing oral diseases and determining effective treatment. (J Oral Sci 53, 257-261, 2011)

**Keywords:** gingival swelling; 3DX; conventional radiograph.

Correspondence to Dr. Hiroaki Kabashima, Department of Periodontology, Division of Oral Rehabilitation, Faculty of Dental Science, Kyushu University, 3-1-1 Maidashi, Higashi-ku, Fukuoka 812-8582, Japan  
Tel: +81-92-642-6358  
Fax: +81-92-642-6360  
E-mail: hkabashi@dent.kyushu-u.ac.jp

---

### Introduction

Findings from conventional intraoral and panoramic radiography are routinely used in clinical practice for diagnosis and treatment planning. Conventional intraoral radiographs are two-dimensional (2D) images. However, such images do not always provide sufficient information because buccal and palatal structures in the maxilla are often superimposed. Recently, dental cone-beam computed tomography (CT) was introduced as a diagnostic device in dentistry. The 3D Accuitomo XYZ Slice View Tomograph (J. Morita Mfg. Co., Kyoto, Japan) is called the 3DX Multi-Image Micro CT (3DX) in Japan and has been widely used in various fields of dentistry, including endodontics, for diagnostic imaging, as it is capable of producing detailed, high-resolution, 3D images of oral structures (1-8).

Gingival swelling can be induced by periapical periodontitis, marginal periodontitis, root fracture, or epulis (6-10). Because the signs and symptoms of gingival swelling are often nonspecific and conventional intraoral and panoramic radiographic modalities show no evidence of abnormalities in teeth, the causes of inflammation are often clinically ambiguous.

Herein, we describe a case in which the cause of clinical symptoms of gingival swelling was difficult to identify by means of a general examination that included conventional radiography. We found that 3DX was very effective for

reliable diagnosis of oral disease and that it enabled successful treatment. Furthermore, high-resolution 3DX images were useful in obtaining the patient's informed consent for therapy.

### Case Report

A 54-year-old woman was referred to Kyushu University Dental Hospital for assessment of a painless lump of soft tissue on the buccal gingiva of the right maxillary second molar (Fig. 1A). Her medical history was not contributory, and she reported no allergies or medication use. She had undergone root canal treatment of the right maxillary second molar seven years earlier. Her oral hygiene was good, and periodontal examination revealed no mobility, with probing depth within normal limits. The affected tooth was not tender to percussion or biting.

Conventional intraoral and panoramic radiographic examinations revealed no periapical radiolucency associated with internally affected tipping of the apex of the right maxillary second molar (Fig. 1B, C). The tip of an accessory gutta-percha point that had been inserted into the sinus tract did not reach the root apex. There was no radiolucent area around the root of the second molar. Due to the history of root canal treatment, we tentatively diagnosed asymptomatic apical periodontitis of the right maxillary second molar. However, the gingival swelling remained even after retreatment of the root canal of the second molar, and the patient subsequently underwent CT scanning for further examination.

Sagittal CT images revealed two independent areas of bone resorption in the right maxillary second molar. One periradicular lesion of the palatal root of the right maxillary

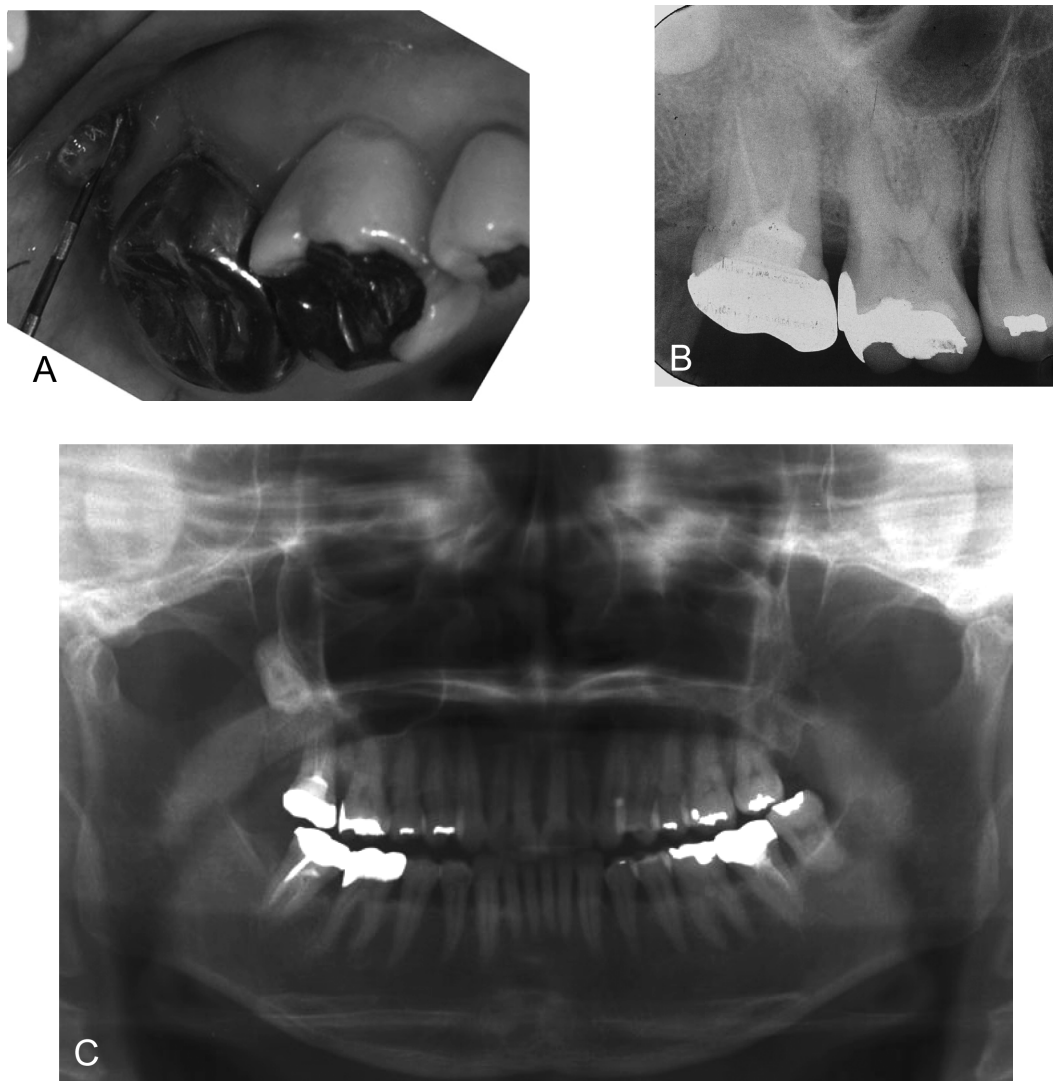


Fig. 1 Pretreatment intraoral clinical photograph (A), conventional intraoral radiograph of the right maxillary molars (B), and panoramic radiograph (C).

second molar expanded toward the crown of the impacted third molar, and another periradicular lesion extended from the mesiobuccal root of the right maxillary second molar to the distobuccal root of the right maxillary first molar (Fig. 2A-C). In addition, the continuity of the floor of the right maxillary sinus was intact, and slight thickening of the mucosa of the maxillary sinus was observed (Fig. 2D). Potential causes of the gingival swelling included periapical periodontitis, marginal periodontitis, root fracture of the second molar, and pericoronitis of the impacted third

molar; however, it was difficult to determine the precise cause. The right maxillary first molar was endodontically treated after an electric pulp tester showed no pulp vitality. The 3DX radiographs showed alveolar osteitis around the impacted maxillary third molar and maxillary sinusitis. Therefore, the impacted maxillary third molar and second molar were extracted. Granulation tissue and debris were removed from the extraction socket, which was then rinsed with sterile saline. Necrotic debris was observed, but there was no fracture line or perforation on the root surface of

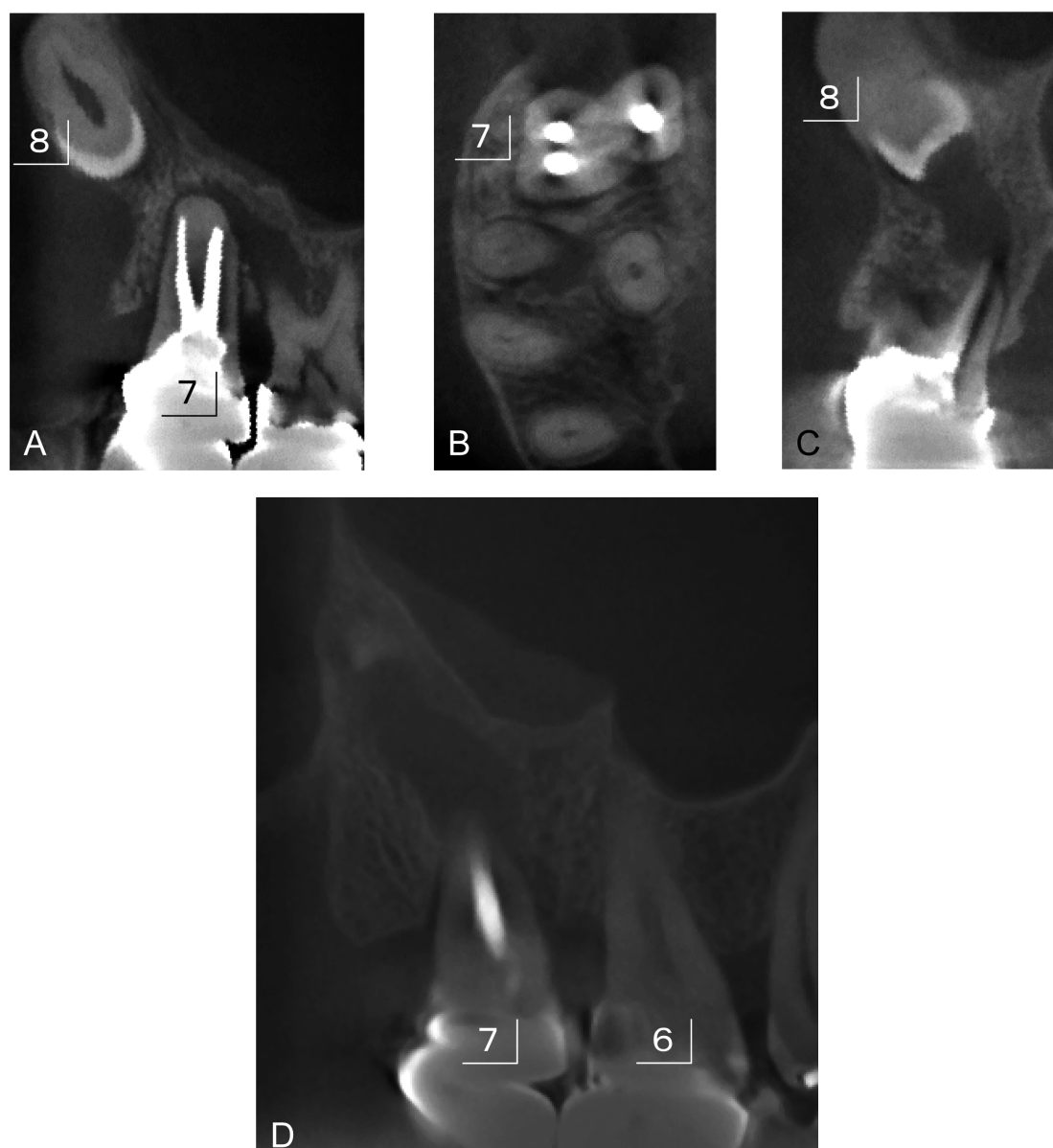


Fig. 2 High-resolution 3DX sagittal, axial, and coronal images of the right maxillary molars. (A) Sagittal image of the buccal root of the maxillary right first and second molars shows presence and expansion of a periradicular lesion in the buccal root. (B) Axial image of the second molar. (C) Coronal image of the second molar shows the expansion of the periradicular lesion. (D) Sagittal image of the right maxillary sinus shows thickening of the right maxillary sinus mucosa.

the second molar. The root of the third molar was intact. The impacted maxillary third molar was transplanted immediately after extraction of the second molar. Histological findings of the gingival tissue were suggestive of a polypoid lesion consisting of granulation tissue with neutrophil infiltration and vascularization (data not shown). Conventional endodontic and surgical treatment of the maxillary molars was performed, and the outcome was satisfactory.

Clinical and radiographic follow-up has continued for four years, and she has remained clinically asymptomatic with normal occlusal function after three years of treatment, including tooth autotransplantation. In addition, the treated tooth shows no radiographic evidence of root resorption or ankylosis (Fig. 3). The continuity of the floor of the maxillary sinus has been maintained, and thickening of the sinus mucosa is not present, even on 3DX images, four years after treatment (Fig. 4).

### Discussion

We reported an unusual case in which conventional intraoral and panoramic radiographic imaging did not provide sufficient information for diagnosis or treatment planning.

Routine intraoral radiography is essential for clinical diagnosis and treatment planning. However, conventional intraoral radiographs are 2D images. The buccal structure affects the representation of the palatal structure in such images, and information on anatomy is limited by the fact

that is shown in two dimensions. For these reasons, a 3D diagnostic approach is believed to be more effective in evaluating periradicular lesions, particularly those in multirooted maxillary molar teeth. Several investigators have reported the usefulness of dental CT in various fields of dentistry, including endodontics (1-8). In the present case, 3DX images revealed periapical lesions and the extent of their expansion. These findings were undetectable in conventional radiographic images of each root of the multirooted maxillary right first and second molars. However, a radiolucent area around the crown of the impacted maxillary right third molar was visible in 3D images, as was thickening of the mucosa of the maxillary sinus.

Clinical use of 3DX in endodontics has proven especially useful in observing the expansion of periapical lesions of each root of multirooted teeth, revealing the three-dimensional relationships between the periapical lesion and the maxillary sinus or mandibular canal, and confirming the presence and position of fenestration, root fracture, root resorption, and perforation.

In our patient with gingival swelling, conventional intraoral and panoramic radiography did not show a radiolucent area around the root apex of the first and second maxillary molars. In addition, conventional radiography showed that the tip of an accessory gutta-percha point inserted into the sinus tract did not reach the root apex. The patient's oral hygiene condition was good, and the tooth

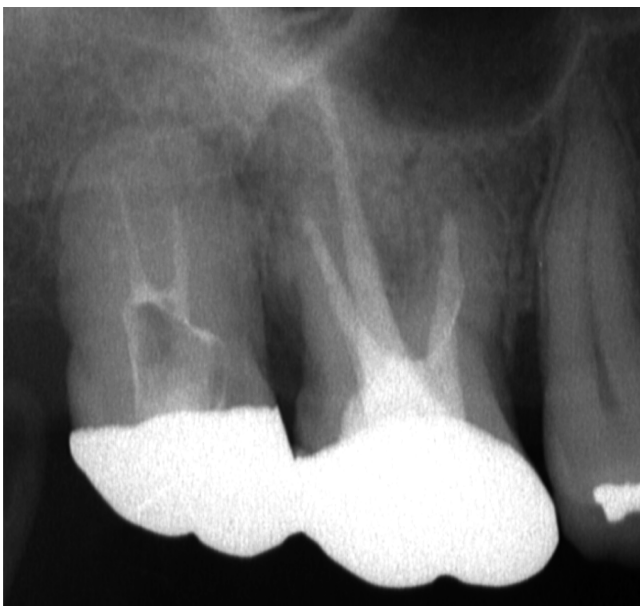

Fig. 3 A 3-yr post-treatment conventional intraoral radiograph of the right maxillary molars.

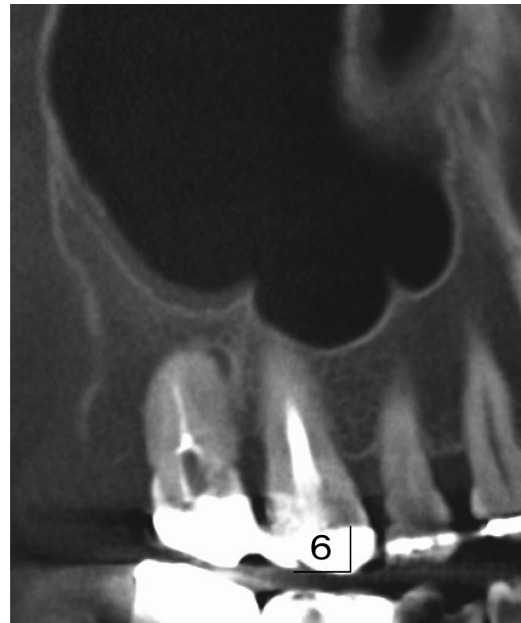


Fig. 4 A 4-yr post-treatment sagittal image of the right maxillary molars and sinus.

was not mobile. Probing depth was within normal limits, and the tooth was not tender to percussion or biting. Gingival swelling in our patient was attributable to several causes, including periodontitis and a root fracture (7-10).

The above findings from general examination and conventional intraoral and panoramic radiography were not sufficient for determining the cause of gingival swelling. From the perspective of diagnosis, it is safe to assume that 3DX will become an essential tool for diagnosing oral diseases and determining optimal treatment because it produces high-resolution 3D images at any tomographic layer.

In conclusion, the newly developed 3DX proved very useful in detecting the presence and expansion of bone resorption that might be overlooked by clinicians relying on conventional intraoral radiography. The use of 3DX will assist dentists in performing optimal examination and accurate diagnosis, avoiding redundant interventions in treatment, and developing appropriate treatment plans. Because accurate diagnostic information is likely to lead to better outcomes, 3DX might become an indispensable tool in clinical practice.

### References

1. Honda K, Larheim TA, Johannessen S, Arai Y, Shinoda K, Westesson PL (2001) Ortho cubic super-high resolution computed tomography: a new radiographic technique with application to the temporomandibular joint. *Oral Surg Oral Med Oral Pathol Oral Radiol Endod* 91, 239-243.
2. Ito K, Yoshinuma N, Goke E, Arai Y, Shinoda K (2001) Clinical application of a new compact computed tomography system for evaluating the outcome of regenerative therapy: a case report. *J Periodontol* 72, 696-702.
3. Nakata K, Naitoh M, Izumi M, Inamoto K, Arijji E, Nakamura H (2006) Effectiveness of dental computed tomography in diagnostic imaging of periradicular lesion of each root of a multirrooted tooth: a case report. *J Endod* 32, 583-587.
4. Simon JH, Enciso R, Malfaz JM, Roges R, Bailey-Perry M, Patel A (2006) Differential diagnosis of large periapical lesions using cone-beam computed tomography measurements and biopsy. *J Endod* 32, 833-837.
5. Nair MK, Nair UP (2007) Digital and advanced imaging in endodontics: a review. *J Endod* 33, 1-6.
6. Cotton TP, Geisler TM, Holden DT, Schwartz SA, Schindler WG (2007) Endodontic applications of cone-beam volumetric tomography. *J Endod* 33, 1121-1132.
7. Walter C, Kaner D, Berndt DC, Weiger R, Zitzmann NU (2009) Three-dimensional imaging as a pre-operative tool in decision making for furcation surgery. *J Clin Periodontol* 36, 250-257.
8. Nakata K, Naitoh M, Izumi M, Arijji E, Nakamura H (2009) Evaluation of correspondence of dental computed tomography imaging to anatomic observation of external root resorption. *J Endod* 35, 1594-1597.
9. Kabashima H, Nagata K (2001) Presence of interleukin-4-producing cells for human bone regeneration after application of guided tissue regeneration membranes. *J Endod* 27, 444-448.
10. Vilmann A, Vilmann P, Vilmann H (1986) Pyogenic granuloma: evaluation of oral conditions. *Br J Oral Maxillofac Surg* 24, 376-382.