Journal of Oral Science, Vol. 53, No. 2, 203-211, 2011

Original

Oral manifestations of HIV infection and their correlation with CD4 count

Ashish S. Bodhade[1)], Sindhu M. Ganvir[2)] and Vinay K. Hazarey[2)]

[1)]Department of Oral and Maxillofacial Pathology, VSPM'S Dental College and Research Center, Nagpur, Maharashtra, India
[2)]Department of Oral and Maxillofacial Pathology, Government Dental College and Hospital, Nagpur, Maharashtra, India

(Received 26 November 2010 and accepted 5 April 2011)

Abstract: Human Immunodeficiency Virus (HIV)-related oral lesions can be used as markers of the immune status. The present cross-sectional study was conducted to identify the oral manifestations in HIV-infected individuals and their association with reduced Cluster of Differentiation 4 (CD4) count. The study population included known HIV-positive patients. A detailed case history of 399 HIV-positive patients was obtained and general examination was carried out. Diagnosis of oral lesions was done based on presumptive criteria of EEC Clearinghouse, 1993. The CD4 count was determined in 369 patients and correlated with oral manifestations. The prevalence of oral lesions was found to be 76.70% (*n* = 306). Oral candidiasis (157 (39.3%)) was the most common oral lesion associated with HIV infection. Amongst various forms of oral candidiasis, erythematous candidiasis (122 (39.3%)) outnumbered the other forms. The mean CD4 count of patients with oral lesions (207 cells/mm^3) was less than in patients without oral lesions (291 cells/mm^3) (*P* = 0.002). Oral candidiasis was found to be significantly correlated to a reduced CD4 cell count below 200 cells/mm^3 (*P* = 0.000; Odds ratio = 3.1; 95% Confidence interval 1.9-4.9) with good sensitivity, best specificity and positive predictive value. Oral manifestations may be used as an alternative to CD4 count at field-based settings to diagnose the immune compromised status of HIV-infected individuals. (J Oral Sci 53, 203-211, 2011)

Keywords: HIV; Oral manifestations; CD4 count; Oral candidiasis.

Correspondence to Dr. Ashish S. Bodhade, Department of Oral & Maxillofacial Pathology, VSPM'S Dental College and Research Center, Digdoh Hills, Hingana Road, Nagpur 440019, Maharashtra, India
Tel: +91-9422475735
Fax: +91-7104-2362904
E-mail: drbodhade55@rediffmail.com

Introduction

Acquired immunodeficiency syndrome (AIDS) is an infectious disease caused by the HIV, and is characterized by profound immunosuppression that leads to opportunistic infections, secondary neoplasm and neurologic manifestations (1). The magnitude of this modern plague is truly staggering. India is one of those countries where the HIV epidemic is growing rapidly. The National AIDS Control Organization (NACO) estimated that 1.8-2.9 million HIV-positive individuals were living with HIV/AIDS in India in 2007. Oral manifestations are common in HIV-positive patients and can be used to diagnose the immune status of patients. The fact that oral lesions can be readily detected by a trained clinician in a standardized, objective fashion without any complicated or expensive diagnostic technique has increased their utility (2-5).

The present cross-sectional study was carried out with the aim to introduce oral manifestations in HIV-infected individuals as a marker of immune status for field-based settings in developing countries like India where CD4 count and HIV viral RNA load estimation cannot be routinely performed in a large population due to its high cost.

Materials and Methods

The present cross-sectional study was approved by the institutional ethics committee of the Government Dental College and Hospital, Nagpur, Maharashtra, India. A total of 399 known HIV-positive individuals were selected irrespective of age and sex, and blood samples were drawn from the patients for CD4 count estimation, after obtaining informed consent. For the study purpose, these patients were divided into two groups: patients with oral manifestations and patients without oral manifestations.

Detailed case history was taken from each patient on a case history proforma which included demographic information, mode of transmission of disease, and presence of systemic co infections. Patients on antiretroviral therapy (ART) were excluded from the study. Oral examination was carried out in natural light using disposable wooden spatula, gloves, masks, brightly illuminating torch and sterile pieces of cotton and gauze. The oral lesions associated with HIV infection were diagnosed based on presumptive criteria given by the EEC Clearinghouse on oral problems related to HIV infection and the WHO collaborating centre on oral manifestations of the human immunodeficiency virus (6). Proper investigations were carried out whenever required to arrive at final diagnosis. For oral candidiasis, a cytologic smear was taken by scraping the oral surface. The smear was then stained with potassium hydroxide (KOH) mount followed by gram staining. For lesions where biopsy was necessary, specimens were taken after obtaining informed consent of the patient and stained with routine hematoxylin and eosin and PAS stain.

CD4 count was estimated in 369 out of the 399 patients. These 369 patients were again divided into two groups, patients with oral manifestations and patients without oral manifestations and their correlation with CD4 count was determined using a *t*-test and chi-square test. CD4 count was estimated using BD FACS Caliber system™ (BD, Franklin Lakes, NJ, USA). The BD FACS Calibur multicolor flow cytometer is designed specifically to support a wide range of applications. The BD FACS Calibur system combines unique dual-laser technology, an automated sample loader option, and powerful software to provide the high throughput necessary to meet productivity requirements of clinical laboratories. The sensitivity, specificity, positive predictive value (PPV) and negative predictive value (NPV) were assessed for individual oral lesions and oral lesions in general when used as markers of immune suppression (CD4 count < 200 cells/mm^3). Statistical analysis was done using SPSS 8.0 software.

Results

The age of the 399 patients ranged from 2 to 78 years, with a mean age of 33 years. The oral lesions mainly developed in the second and third decade of life. There was a slight male predominance with a male to female ratio of 1.2:1. The predominant mode of transmission of HIV infection was found to be heterosexual contact (341 (85.46%)); followed by blood transfusion, vertical transmission and bisexual contact.

Tuberculosis was found to be the most common systemic disease associated with HIV infection (132 (33.08%)) in the present study population. This was followed by herpes zoster infection, pruritic papular eruption, pneumonia, genital ulcers and splenomegaly in decreasing order of occurrence. (Table 1)

The prevalence of oral lesions in the present study was found to be 76.70% (n = 306). Large varieties of oral

Fig. 1 Pseudomembranous candidiasis.

Fig. 2 Erythematous candidiasis.

lesions were observed in our study patients (Figs. 1-7). Oral candidiasis (157 (39.3%)) was found to be the most common oral lesion amongst the 399 HIV-infected patients. Erythematous candidiasis (122 (30.6%)) outnumbered other forms of oral candidiasis. This was followed by pseudomembranous candidiasis in 49 (12.3%) and angular

Table 1 Distribution of systemic diseases associated with HIV infection

Systemic diseases associated with HIV infection	No. of patients	%
Tuberculosis	132	33.08
Malaria	1	0.25
Chancroid	1	0.25
Dermatitis	6	1.5
Genital ulcers	3	0.75
Herpes zoster	17	4.26
Pruritic popular eruption	12	3.0
Pneumonia	5	1.25
Hemorrhoids	2	0.5
Splenomegaly	3	0.75
Hepatomegaly	1	0.25
Jaundice	1	0.25
Leprosy	1	0.25
Lichen nitiden	1	0.25
Meningitis	2	0.5
Oesoghegal diverticulitis	2	0.5
Onychomycosis	1	0.25
Ottitis externa	1	0.25
Genital candidiasis	2	0.5
Pityriasis	1	0.25
Psychotic disorder	1	0.25
Pyoderma	2	0.5
Systemic histoplasmosis	1	0.25
Scabies	2	0.5
Seizure	1	0.25
Tinia carporis	1	0.25
Molluscum contagiosum	9	2.3

Fig. 3 Angular cheilitis.

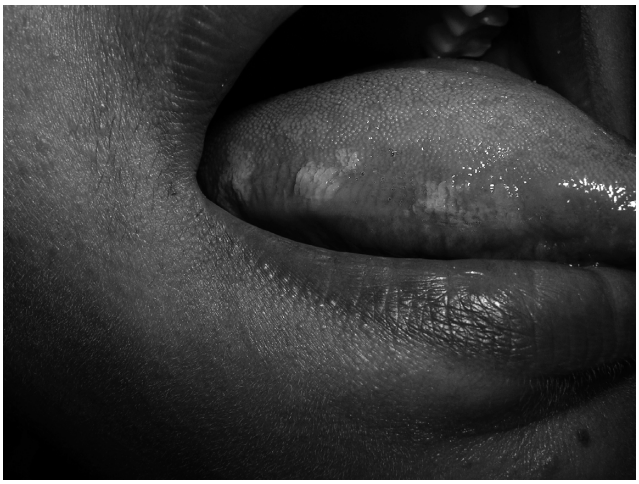

Fig. 4 Oral hairy leukoplakia.

Fig. 5 Melanotic hyperpigmentation.

Fig. 6 Linear gingival erythema.

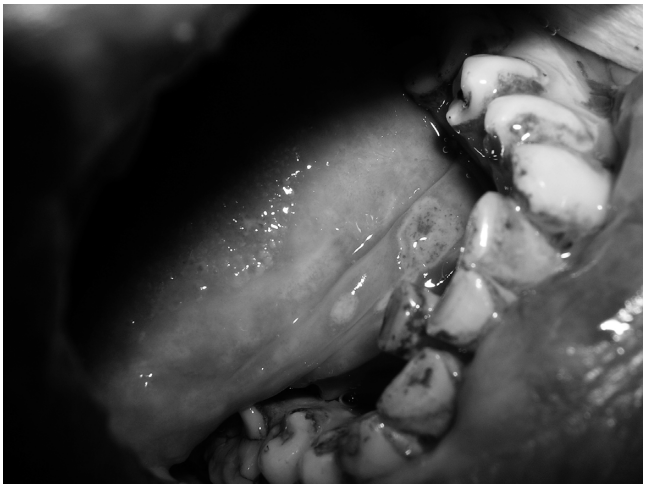

Fig. 7 Non-specific ulcerations.

cheilitis in 17 (4.3%) patients. These lesions were Group I lesions most commonly associated with HIV infection, according to EEC Clearinghouse criteria.

In 78 (19.5%) patients, melanotic hyperpigmentation was found to be the most prevalent oral lesion next to oral candidiasis. This is a group II lesion which is supposed to be less commonly associated with HIV infection, according to ECC Clearinghouse criteria.

Other lesions in decreasing order of their prevalence were ulcers not otherwise specified (UNOS), oral hairy leukoplakia, linear gingival erythema, necrotizing gingivitis, necrotizing periodontitis, molluscum contagiosum, Herpes simplex infection, non-Hodgkin's lymphoma, herpes zoster, decreased salivary flow rate, lichenoid reaction, facial palsy, erythema multiforme (Table 2).

Out of 399 HIV-positive patients, the CD4 count was estimated in 369 patients. The mean CD4 count of these 369 patients was found to be 226 cells/mm^3 with a range of 3 to 2038 cells/mm^3 (SD = 224 cells/mm^3) (Table 3).

The statistical analysis showed that the mean CD4 count of patients with oral manifestations (207cells/mm^3) was less than patients without oral manifestations (291cells/mm^3). This difference was found to be statistically significant (P = 0.002, t-test). From the above findings, it can be inferred that oral manifestations have a definite association with reduced CD4 count in HIV patients.

When the presence of oral lesions was correlated with CD4 count < 200 cells/ mm^3, a statistically significant association was found between occurrence of oral lesions in HIV-positive patients and reduction in CD4 count < 200 cells/mm^3 (P < 0.009; chi-square test, 95% Confidence interval (CI) 1.1-3.0).

When the correlation of individual oral lesions with CD4 count was examined using chi-square test, oral candidiasis was found to be significantly correlated with reduced CD4 cell count below 200 cells/mm^3 (P = 0.000; Odds ratio (OR) = 3.1; 95% CI 1.9-4.9). Amongst the various forms of oral candidiasis, both pseudomembranous and erythematous candidiasis showed highly significant association with reduced CD4 count, pseudomembranous candidiasis being highly associated with CD4 count < 200 cells/mm^3 than erythematous.

Other than these, no other oral lesion from group 1, group 2 and group 3 were found to be significantly associated with CD4 cell count < 200 cells/mm^3.

The OR which related presence of oral lesion to that of immune suppression (CD4 count < 200 cells/mm^3) was highest for pseudomembranous candidiasis, 18.6 (95% CI 3.9-76.9). This suggested that the odds of a patient with pseudomembranous candidiasis with CD4 count < 200 cells/mm^3 was 18.6 times more than any other patient

Table 2 Distribution of oral lesions in 399 HIV-positive patients
Oral manifestations associated with HIV infection were grouped according to the classification of EEC Clearinghouse (7)

Oral lesions	No. of patients	%
Group 1: Lesions most commonly associated with HIV infection		
Oral candidiasis	157	39.3
Erythematous candidiasis	122	30.6
Pseudomembranous candidiasis	49	12.3
Angular cheilitis	17	4.3
Oral hairy leukoplakia	46	11.5
Linear gingival erythema	41	10.3
Necrotizing gingivitis	34	8.5
Necrotizing periodontitis	21	5.3
Non Hodgkin's lymphoma	3	0.8
Group 2: Lesions less commonly associated with HIV infection		
Melanotic hyper pigmentation	78	19.5
Ulcers not otherwise specified	47	11.8
Herpes simplex virus infection	8	2
Herpes zoster	1	0.3
Decreased salivary flow rate	1	0.3
Group 3: Lesions associated with HIV infection		
Recurrent apthous ulcers	10	2.5
Molluscum contagiosum	9	2.3
Lichenoid reaction	1	0.3
Facial palsy	1	0.3
Erythema multiforme	1	0.3

Table 3 CD4 count in 369 HIV-positive patients

CD4 count	*n*	Range	Min	Max	Mean	Std. deviation
Total	369	2035	3	2038	226	224

with CD4 count < 200 cells/mm^3.

The sensitivity of oral lesions in general was found to be very high (81.30%) as compared to specificity (30.32%). The positive predictive value of oral lesions in general was 61.70% and negative predictive value was 54.02%. The sensitivity of oral candidiasis was found to be higher (50%) than any other oral lesion. Specificity (98.70%) and positive predictive value (95.45%) of pseudomembranous candidiasis were found to be higher than erythematous candidiasis (78.06% and 70.43% respectively). (Table 4)

The above observations indicated that oral candidiasis in general and pseudomembranous and erythematous candidiasis individually were good markers of immune suppression than any other oral lesions in seropositive patients.

Discussion

Human immunodeficiency virus is a retrovirus, which has specific affinity for CD4 cells (T helper cells). On entry into the host's body, the HIV attacks and disturbs the delicate balance, thereby rendering the host susceptible to a lot of life-threatening opportunistic infections, neurological disorders, unusual malignancies and oral lesions (7).

Some specific, common oral manifestations in HIV infection were found to be associated with immune suppression. These oral disorders may be implicated in the diagnosis and prognosis of HIV-infected patients.

We observed that the peak age of occurrence of HIV infection was the third decade of life and that there was slight male predilection. This is similar to reported findings from South India (8-9) and other parts of the world (10-13). However, a female predominance has been reported mostly in studies in the African region (14).

In the present study, heterosexual route was the most common mode of transmission. This may be the reason why there was a higher number of female HIV patients in our study population compared to developed countries

Table 4 Determination of sensitivity, specificity, positive and negative predictive value of individual oral lesions

Oral lesions (306)	Sensitivity (%)	Specificity (%)	PPV (%)	NPV (%)
Oral candidiasis	50	76.1	74.1	47.78
Erythematous candidiasis	37.8	78.06	70.43	47.63
Pseudomembranous candidiasis	19.62	98.70	95.45	47.07
Angular cheilitis	5.1	98	78	42
Oral hairy leukoplakia	12.1	89	60	42.3
Linear gingival erythema	9.3	88.38	52.63	44
Necrotizing gingivitis	8.4	90.32	54.54	41.66
Necrotizing periodontitis	6.04	95.48	65	42
Non Hodgkin's lymphoma	1.4	100	100	42.34
Melanotic hyper pigmentation	21.49	82.52	63.01	43.24
Ulcers not otherwise specified	11.21	90.32	61.33	42
Herpes simplex virus infection	2.33	98.06	62.5	42.1
Herpes zoster	0.46	100	100	42
Decreased salivary flow rate	0	100	0	41
Recurrent apthous ulcers	1.86	961	40	40.5
Molluscum contagiosum	3.2	99.35	87.5	42.65
Lichenoid reaction	0.4	100	100	42.1
Facial palsy	0.4	100	100	42.1
Erythema multiforme	0.4	100	100	42.1

PPV = Positive predictive value, NPV = Negative predictive value

where homosexuality and intravenous drug use were the common routes of HIV transmission (4,15).

In the present study, tuberculosis (TB) was found to be the most frequently occurring systemic co-infection (33.85%). HIV and *Mycobacterium tuberculosis* have a synergistic interaction; each accentuates progression of the other. Out of the 5.1 million HIV-infected people in India, about half of them are co-infected with *M. tuberculosis*; approximately 200,000 of these co-infected individuals develop active TB each year in association with HIV infection (8,16,17).

In the present study, 306 (76.70%) patients exhibited oral lesions associated with HIV infection. Comparable prevalence has been reported in other studies from India, South East Asia and rest of the world (8,12,18,19). However, most of these studies do not reflect the prevalence of lesions found in the general HIV-infected population because they are mostly hospital-based studies (20).

A wide range of oral lesions were reported in the present study. Oral candidiasis was the most frequently found oral lesion, which was consistent with many studies (5,12,21,22). Among oral candidiasis, the cases of erythematous candidiasis outnumbered those of pseudomembranous candidiasis (122 (39.3%)). This finding was in accordance with Moniaci et al. (35.5%) (12) and Sharma et al. (44.5%) (23). Ranganathan et al. (8) had reported pseudomembranous candidiasis as the predominant lesion (33%) rather than erythematous candidiasis (14%) in patients from South India, which was in contrast with the present study. The reason for this difference cannot be inferred from these studies; further investigations should be carried out to identify the strain of Candida prevalent in the two regions. Erythematous candidiasis may develop in patients taking broad-spectrum antimicrobials. It is common in HIV patients who take antibiotics and anti microbial agents for other associated infections. Moreover, smoking is one of the prevalent habits in India which may lead to an increased incidence of erythematous candidiasis.

Melanotic hyperpigmentation has been reported to be the second largest lesion associated with HIV infection (78 (19.54%)). Ranganathan et al. (8,9) had found it to be the third most common lesion in their study (23%). The possible reasons for occurrence of this pigmentation may be the increased release of ά-melanocyte stimulating hormone (ά-MSH) due to deregulated release of cytokines in HIV disease, use of melanocyte stimulating drugs like certain antiviral or antifungal agents and Addison's disease.

Ulcers not otherwise specified (UNOS) comprised

11.8% of oral lesions associated with HIV in our study. A similar frequency (12.3%) was reported by Tsang and Samaranayake (24). These ulcers usually appear in acute periods of HIV infection. Pharmacologic agents are among the most common causes of recurrent aphthous lesions, commonly known as canker sores. Some common culprits include non-steroidal anti-inflammatory drugs (NSAIDs), nicorandil, ACE inhibitors, but any drug can potentially produce an aphthous-like reaction. In the acute stage of HIV disease, the patient may be prescribed many of the above-mentioned medications; so there might be an increased prevalence in aphthous ulcers in this stage of HIV. Others were of iatrogenic origin caused by Azidothymidine (AZT), Interferon or Neutropenia (25).

Oral hairy leukoplakia (OHL) was less frequently reported in previous studies in India. Ranganathan et al. (8,9) reported one case (0.33%) and 21 (2.7%) cases among 300 and 1000 HIV patients, respectively. In contrast, the present study reported 46 (11.52%) cases amongst 399 patients. The overall prevalence of OHL in the Indian subcontinent was found to be low. This low prevalence could be the result of its strong association with homosexual men in the studies from the developed countries (26); differences in diagnostic capabilities amongst investigators could also contribute to the differences in prevalence. The exact reason, however, is not known. Further studies should be planned to correlate the prevalence of OHL and Kaposi's sarcoma in Southeast Asia and the rest of the world population along with molecular analysis of the two populations.

In the present study, 10.27% of patients had linear gingival erythema, 8.52% had necrotizing gingivitis, and 5.26% had necrotizing periodontitis. Gingival and periodontal diseases were the predominant oral lesions in patients from South India (8,9). The reported prevalence of periodontal diseases in HIV-infected patients varies greatly in the literature as it depends on many factors, such as the stage of the disease, the risk group to which the patient belongs and criteria used for periodontal diagnosis.

One of the interesting findings in our study was the presence of three oral non-Hodgkin's lymphomas, involving palate, gingiva and buccal mucosa. Two cases showed regression of lesions with chemotherapeutic agents and ART, while one patient was lost to follow up.

One finding consistent with other studies from South East Asia was the absence of Kaposi's sarcoma (KS). Homosexuality is considered to be a possible risk factor for Kaposi's sarcoma (12,15,22,27,28). In Asia, where heterosexual practice is the main risk behavior of HIV transmission, the low prevalence of Kaposi's sarcoma in the present study is justifiable. The absence of Kaposi's sarcoma in Chinese patients has also been reported (24).

From the above discussion, it is clear that not a single study follows a common pattern. Oral lesions in HIV-infected patients differ in different parts of the country as well as the world.

A statistically significant difference was found between the mean CD4 count of patients with oral manifestations and without oral manifestations ($P = 0.002$). This shows that oral manifestations in HIV infection were commonly seen in patients with a reduced CD4 count less than 200 cells/mm^3, i.e., depressed immune status (4,5).

Amongst various forms of oral candidiasis, pseudomembranous candidiasis showed a highly significant association with CD4 count < 200 cells/mm^3 compared to erythematous candidiasis. A significant relation between oral candidiasis and CD4 count < 200 cells/mm^3 has been reported in North and South Thailand patients (29).

The sensitivity (81.30%) and positive predictive value (61.70%) of oral lesions in general were very high, while specificity (30.32%) was very low in the present study. Patton LL (5) reported a positive predictive value of 60.5%, which was in accordance with present study. However, there was a lower sensitivity (58.2%) compared to specificity (70.8%) for oral lesions in general in their study, which was not in agreement with the present study.

The present study demonstrated the highest sensitivity for oral candidiasis than any other oral lesion. Amongst various forms of oral candidiasis, pseudomembranous candidiasis had the highest specificity (98.70%).

Pseudomembranous candidiasis had a higher positive predictive value (PPV) (95.45%) than erythematous candidiasis (70.43%), when compared individually. Patton LL (5) had reported highest specificity and positive predictive value for pseudomembranous candidiasis (96% and 98%, respectively), which is in accordance with the present study.

For HIV-infected patients who attend clinics where CD4 monitoring is not possible, the presence of oral candidiasis suggests severe immunosuppression and that it is time to initiate ART. CD4 monitoring is not possible in all clinics. However, the absence of oral candidiasis does not imply that a patient does not have severe immunosuppression. This approach may help to decide whether to initiate ART or not, particularly in rural settings where laboratory monitoring is often not possible.

For this reason, medical and dental professionals should be trained in diagnosing oral lesions more efficiently, and they should develop the habit of examining the oral cavity thoroughly. Findings of the present study and previous studies support the initiation of ART on diagnosis of specific oral lesions in HIV-infected patients. Follow up

studies are required to monitor the progression of HIV disease staged on basis of oral manifestations and treated with ART.

It can be concluded from the present study that oral candidiasis in general; pseudomembranous and erythematous candidiasis specifically are supposed to be good markers of immune suppression than any other oral lesions, as indicated by reduction of the CD4 count < 200 cells/mm^3 in patients. Therefore, these oral manifestations may be used as an alternative to CD4 count, with good sensitivity, best specificity and positive predictive value at field-based settings in developing countries.

Acknowledgments

The authors would like to express their gratitude to all members of the Department of Oral Pathology and Microbiology, Government Dental College and Hospital, Nagpur and Anti Retroviral Therapy (ART) Clinic, Department of Medicine and Department of Microbiology, Government Medical College and Hospital, Nagpur for their valuable help.

References

1. Abbas AK (2004) Diseases of immunity. In: Robbins and Cotran pathologic basis of diseases, 7th ed, Kumar V, Abbas AK, Fausto N, Robbins SL, Cotran RS eds, Saunders, Philadelphia, 193-267.
2. Hilton JF (1995) Staging the natural history of HIV disease. In: Oral manifestations of HIV infection, Greenspan JS, Greenspan D eds, Quintessence, Carol Stream, 42-48
3. Glick M, Muzyka BC, Lurie D, Salkin LM (1994) Oral manifestations associated with HIV-related disease as markers for immune suppression and AIDS. Oral Surg Oral Med Oral Pathol 77, 344-349.
4. Margiotta V, Campisi G, Mancuso S, Accurso V, Abbadessa V (1999) HIV infection: oral lesions, CD4$^+$ cell count and viral load in an Italian study population. J Oral Pathol Med 28, 173-177.
5. Patton LL (2000) Sensitivity, specificity and positive predictive value of oral opportunistic infections in adults with HIV/AIDS as markers of immune supression and viral burden. Oral Surg Oral Med Oral Pathol Oral Radiol Endod 90, 182-188.
6. EC-Clearinghouse on Oral Problems Related to HIV Infection and WHO Collaborating Centre on Oral Manifestations of the Immunodeficiency Virus (1993) Classification and diagnostic crieteria for oral lesions in HIV infection. J Oral Pathol Med 22, 289-291.
7. Adurogbangba MI, Aderinokun GA, Odaibo GN, Olaleye OD, Lawoyin TO (2004) Oro-facial lesions and CD4 counts associated with HIV/AIDS in an adult population in Oyo State, Nigeria. Oral Dis 10, 319-326.
8. Ranganathan K, Reddy BV, Kumarasamy N, Solomon S, Viswanathan R, Johnson NW (2002) Oral lesions and conditions associated with human immunodeficiency virus infection in 300 South Indian patients. Oral Dis 6, 152-157.
9. Ranganathan K, Umadevi M, Saraswathi TR, Kumarasamy N, Solomon S, Johnson N (2004) Oral lesions and conditions associated with human immunodeficiency viral infection in 1000 South Indian patients. Ann Acad Med Singapore 33, Suppl 4, 37-42.
10. Ramírez V, González A, de la Rosa E, González M, Rivera I, Hernández C, Ponce de León S (1990) Oral lesions in Mexican HIV-infected patients. J Oral Pathol Med 19, 482-485.
11. Schulten EA, ten Kate RW, van der Waal I (1989) Oral manifestations of HIV infection in 75 Dutch patients. J Oral Pathol Med 18, 42-46.
12. Moniaci D, Greco D, Flecchia G, Raiteri R, Sinicco A (1990) Epidemiology, clinical features and prognostic value of HIV-1 related oral lesions. J Oral Pathol Med 19, 477-481.
13. Anil S, Challacombe SJ (1997) Oral lesions of HIV and AIDS in Asia: an overview. Oral Dis 3, Suppl 1, S36-40.
14. Tukutuku K, Muyembe-Tamfum L, Kayembe K, Odio W, Kandi K, Ntumba M (1990) Oral manifestations of AIDS in a heterosexual population in a Zaire hospital. J Oral Pathol Med 19, 232-234.
15. Porter SR, Luker J, Scully C, Glover S, Griffiths MJ (1989) Orofacial manifestations of a group of British patients infected with HIV-1. J Oral Pathol Med 18, 47-48.
16. Sharma SK, Mohan A, Kadhiravan T (2005) HIV-TB co-infection: epidemiology, diagnosis and management. Indian J Med Res 121, 550-567.
17. Nittayananta W, Chanowanna N, Winn T, Silpapojakul K, Rodklai A, Jaruratanasirikul S, Liewchanpatana K (2002) Co-existence between oral lesions and opportunistic systemic diseases among HIV-infected subjects in Thailand. J Oral Pathol Med 31, 163-168.
18. Ramirez-Amador V, Esquivel-Pedraza L, Sierra-Madero J, Ponce-de-Leon S, Ponce-de-Leon S (1998) Oral manifestations of HIV infection by gender and transmission category in Mexico City. J Oral Pathol Med 27, 135-140.

19. Chiang CP, Chueh LH, Lin SK, Chen MY (1998) Oral manifestations of human immunodeficiency virus-infected patients in Taiwan. J Formos Med Assoc 97, 600-605.
20. Silverman S Jr, Migliorati CA, Lozada-Nur F, Greenspan D, Conant MA (1986) Oral findings in people with or at high risk for AIDS: a study of 375 homosexual males. J Am Dent Assoc 112, 187-192.
21. Nittayananta W, Chungpanich S (1997) Oral lesions in a group of Thai people with AIDS. Oral Dis 3, Suppl 1, S41-45.
22. Laskaris G, Hadjivassiliou M, Stratigos J (1992) Oral signs and symptoms in 160 Greek HIV-infected patients. J Oral Pathol Med 21, 120-123.
23. Sharma G, Pai KM, Suhas S, Ramapuram JT, Doshi D, Anup N (2006) Oral manifestations in HIV/AIDS infected patients from India. Oral Dis 12, 537-542.
24. Tsang PCS, Samaranayake LP (1999) Oral manifestations of HIV infection in a group of predominantly ethnic Chinese. J Oral Pathol Med 28, 122-127.
25. Expósito-Delgado AJ, Vallejo-Bolaños E, Martos-Cobo EG (2004) Oral manifestations of HIV infection in infants: a review article. Med Oral Pathol Oral Cir Bucal 9, 410-420.
26. Chidzonga MM (2003) HIV/AIDS orofacial lesions in 156 Zimbabwean patients at referral oral and maxillofacial surgical clinics. Oral Dis 9, 317-322.
27. Barone R, Ficarra G, Gaglioti D, Orsi A, Mazzotta F (1990) Prevalence of oral lesions among HIV-infected intravenous drug abusers and other risk groups. Oral Surg Oral Med Oral Pathol 69, 169-173.
28. Schmidt-Westhausen A, Grünewald T, Reichart PA, Pohle HD (1997) Oral manifestations in 70 German HIV-infected women. Oral Dis 3, Suppl 1, S28-30.
29. Kerdpon D, Pongsiriwet S, Pangsomboon K, Iamaroon A, Kampook, Sretrirutchi S, Geater A, Robinson V (2004) Oral manifestations of HIV infection in relation to clinical and CD4 immunological status in northern and southern Thai patients. Oral Dis 10, 138-144.