Journal of Oral Science, Vol. 53, No. 2, 137-141, 2011

Review

Elastography: the next step

Debdutta Das[1)], Monika Gupta[1)], Harkamal Kaur[1)] and Aman Kalucha[2)]

[1)]Department of Oral and Maxillofacial Surgery, M. M. College of Dental Sciences and Research, Haryana, India

[2)]Department of Oral Medicine and Radiology, M. M. College of Dental Sciences and Research, Haryana, India

(Received 24 September 2010 and accepted 28 February 2011)

Abstract: In the past few decades, various tools have emerged that claim to enhance detection of oral cancer. The most important prognostic factor in patients with oral cancer is lymph node status: the presence of nodal spread decreases the 5-year survival rate by approximately 50%. Differentiation between reactive and metastatic lymphadenopathy is thus vital, and one differentiating criterion is hardness (elasticity) of the lymph node. The purpose of this review is to highlight a promising new ultrasound technique, known as elastography, which measures the characteristics of tissue compliance. The principles underlying elastography are that tissue compression produces strain (displacement) within the tissue – which is lower in harder tissues than in softer tissues – and that malignant tissues are generally harder than normal surrounding tissue. Therefore, elastography might yield clinical information useful in diagnosing cervical metastasis and improving prognosis in oral cancer. It has long been used for cancers of the breast, pancreas, and thyroid, and its use in cervical lymphadenopathy is now being explored, which could lead to great advancements in the diagnosis and prognosis of oral cancer. (J Oral Sci 53, 137-141, 2011)

Keywords: oral cancer; elastography; cervical lymphadenopathy.

Correspondence to Dr. Harkamal Kaur, Department of Oral and Maxillofacial Surgery, M. M. College of Dental Sciences and Research, Mullana, Ambala, Haryana, Pin 133203, India
Tel: +91-9355687234
Fax: +91-1731-304111
E-mail: gigu_84@yahoo.co.in

Introduction

Oral cancer remains a public health problem, and approximately 8,500 people die from this cancer each year in the United States (1). Around the globe, both medical and dental professionals face difficulties in the early detection and diagnosis of such cancers. Fortunately, in the last decade there has been a dramatic increase in the development of potential cancer screening and case-finding tools (2). Despite this progress, however, overall survival has not significantly improved during the last 40 years (1).

Cervical metastasis is the most important prognostic factor in patients with oral cancer, and the presence of nodal spread decreases the 5-year survival rate by approximately 50%. Thus, management of oral cancer requires careful staging of regional lymphatics to accurately determine disease progression (3). Of the 400 to 450 lymph nodes in the human body, the head and neck contain 60 to 70 (4). Lymph node enlargement is part of our body's normal immune response and can be caused by drug reactions, infection, immunologic disorders, malignancies, and several other disorders of unknown etiology (5). Sometimes metastatic cervical lymphadenopathy is the first symptom in patients with malignancies of the head and neck, lung, breast, and other sites. Hence, differentiation between reactive and metastatic lymphadenopathy is vital, and one of the differentiating criteria is lymph node hardness (elasticity) (4).

Ultrasound (US) imaging is a dynamic, readily available, and patient-friendly technique that is particularly useful in the examination of superficial structures (Fig. 1). Improvements in ultrasound resolution have led to the use of this nonionizing imaging modality in the diagnosis of soft-tissue disorders of the head and neck. Ultrasound

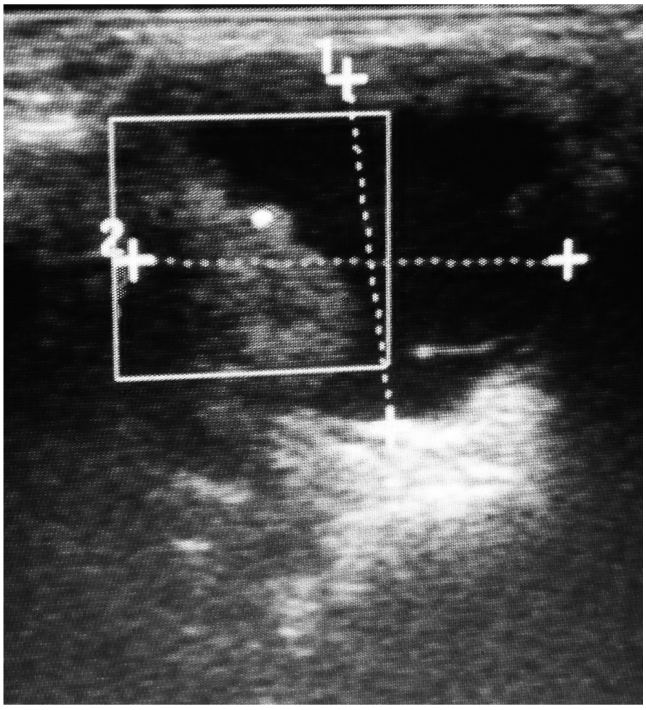

Fig. 1 Lymph node with a necrotic area and soft-tissue component suggestive of metastatic lymph node. The patient was later diagnosed with cancer of the larynx.

Table 1 Indications for use of ultrasound in head and neck region

Assessment of glands (Salivary, thyroid)
Assessment of lymph nodes
Vascular malformations
Soft tissue cysts
Intraoral use (tumor thickness in tongue carcinoma)

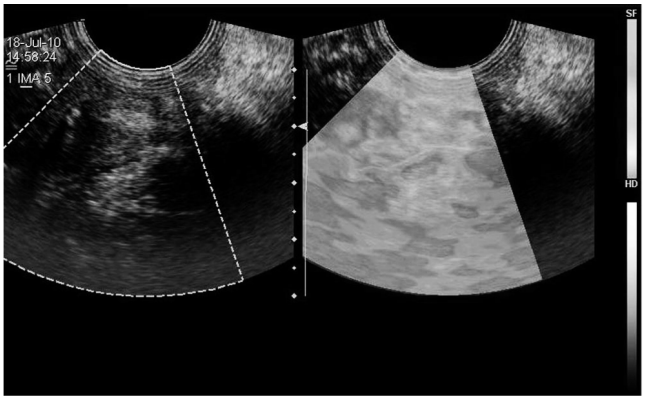

Fig. 2 Images displayed during elastographic examination of the prostate of a 55-year-old man. The right panel shows the elastogram.

imaging results in rapid acquisition of images with minimal artifacts and can be used to guide needle biopsies (fine needle and core biopsies), thus making it a highly specific diagnostic tool (6). It is also useful in preoperative localization of impalpable neck masses (7). Other indications for the use of ultrasound in the head and neck region are listed in Table 1. In the last three decades, US imaging has changed from a cumbersome and expensive system that produced coarse, static, and bistable images to fully digital, handheld devices capable of high-resolution, real-time, grey-scale and color Doppler imaging (8).

In 1991, Ophir et al. described a promising new ultrasound technique, known as elastography, that measures the characteristics of tissue compliance (9). It allows assessment of elasticity distribution and shows differences in hardness between diseased tissue and normal tissue. This technique has had promising results in the differential diagnosis of diseases of the thyroid, breast, liver, prostate (Fig. 2), and pancreas (10) and may prove to be immensely useful in assessing lymph nodes in the maxillofacial region.

The aim of this review is to highlight possible applications of elastography in examining cervical lymph nodes and describe the mechanics of this method. The limitations of this technique are also briefly discussed.

Principles

The principles underlying elastography are that tissue compression produces strain (displacement) within the tissue and that this strain is lower in harder tissues than in softer tissues. Therefore, by measuring tissue strain induced by compression, we can estimate tissue hardness (11). Tissue elasticity resulting from compression is displayed as an image called an elastogram, on which hard areas are blue and soft areas are red. Because malignant tissue is generally harder than normal surrounding tissue, elastography might provide clinical information that permits observation of tissue stiffness, which would be a helpful addition to findings on palpation (10).

Mechanics of Elastography

Elastography allows assessment of the elastic properties of tissues, and the images obtained are compared before and after compression (12). Elasticity varies in different tissues (fat, collagen, etc.) and in the same tissue during different pathologic states (inflammatory, malignancy) (4). Tissue stiffness tends to change (usually increase) with disease and can be imaged by measuring the tissue distortion under an applied stress (13). The resulting high-contrast images can lead to early detection of disease processes. The data are then compared using a cross-correlation technique to determine the amount of

displacement each small region of tissue undergoes in response to the compression applied by the ultrasound transducer (12).

The development of elastography has been the result of interdisciplinary research (Fig. 3). Upon application of stress (or displacement), all points in the elastic medium experience a resulting level of longitudinal strain, although the greatest effect is observed in components along the axis of compression. If one or more of the tissue elements has a different stiffness parameter than the others, the level of strain in that element will be higher or lower, and a stiffer tissue element will generally experience less strain than one that is less stiff. The longitudinal (axial and lateral) strains are estimated from the analysis of ultrasonic signals obtained from standard diagnostic ultrasound equipment (14). This is accomplished by acquiring a set of digitized radio-frequency echo lines from the tissue, compressing the tissue by a small amount with the ultrasonic transducer along the axis of ultrasonic radiation, and acquiring a second, post-compression, set of echo lines from the same region of interest (4,13).

The data from these two echo lines undergo processing, and an elastographic image (elastogram) ultimately appears on the monitor. There are two types of elastograms: gray-scale and color. The hard and soft areas (ie, areas of high and low elasticity, respectively) appear in the gray-scale elastogram as dark and bright, respectively (4). In a color elastogram of a general device, increasing tissue hardness appears, in ascending order, as red, yellow, green, and blue (Fig. 4). These colors represent the relative hardness of the tissues in the elastogram (4).

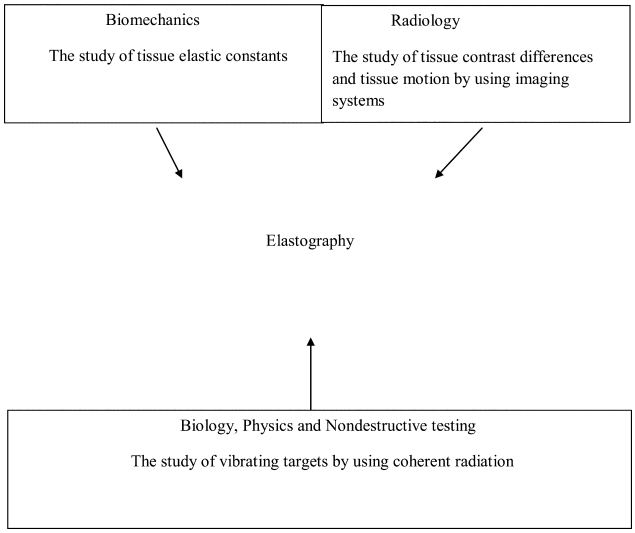

Fig. 3 Interdisciplinary development of elastography.

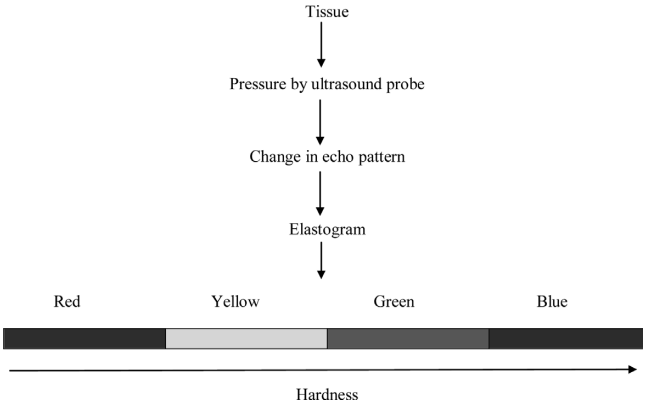

Fig. 4 The devices made by Hitachi and Toshiba use the above color scheme. However, the color scheme used by Siemens device is reversed.

Elastography in Cervical Lymphadenopathy

Assessment of cervical lymph nodes is essential for patients with head and neck carcinomas, as it helps to assess prognosis and select appropriate treatment. Anamnesis and clinical investigations are also performed beforehand; however, their accuracy is suspect because tumor cells spread into adjacent tissues before any clinical symptoms appear (15). The presence of a metastatic node in one side of the neck reduces five-year survival to half that of a patient without such metastasis, and the presence of a metastatic node in both sides reduces survival by 75% (16). Lymph node status is used as a criterion to determine if radical neck dissection, conservative neck dissection, or suprahyoid lymph node extirpation is indicated (15).

To date, open cervical lymph node biopsy combined with pathologic examination remains the gold standard in confirming the presence of lymph node metastases. However, this procedure can alter patterns of lymphatic drainage for up to one year after surgery, especially in patients who present late for treatment (10). Fine-needle aspiration cytology has proven effective in diagnosis, but it is invasive and subject to sampling and analytic error. In response to these limitations, significant research has been directed toward identifying noninvasive methods for diagnosing enlarged lymph nodes. Such techniques need to be safe, accurate, and straightforward, as is the case for most standard medical screening tests (10).

Although elastography is not yet used in routine clinical practice, it has been shown to be useful in the differential diagnosis of breast, thyroid, and prostate cancers. Neck lymph nodes are well positioned for elastographic examination. They are easily accessible and can be efficiently compressed against underlying anatomic

structures with the use of an ultrasound probe (10,17). Information on lymph node stiffness would likely be clinically useful for guidance of percutaneous biopsy and/or nodal dissection. Such information might also improve patient follow-up by enabling early detection of cancer recurrence (depicted as stiffness) (17).

Lyshchik et al. (17) studied the accuracy of sonoelastography in differentiating benign and metastatic cervical lymph nodes in patients suspected of having thyroid or hypopharyngeal cancer. Histologic nodal findings were used as the reference standard for comparison. They found that most benign nodes had the same brightness as surrounding anatomic structures and were therefore not clearly visible on ultrasound elastograms. In contrast, most metastatic lymph nodes appeared darker on ultrasound elastograms. Also, margin delineation was better on elastograms, as the margins of metastatic lymph nodes were more regular and distinct than those of benign lymph nodes.

In another study, Alam et al. (4) evaluated the diagnostic performance of sonographic elastography and B-mode sonography of enlarged cervical lymph nodes and found that elastography significantly improved the performance of sonography in the diagnosis of enlarged metastatic cervical lymph nodes.

There is a risk of over- or understaging lymph nodes in the head and neck (18). Elastography may assist in preventing such misdiagnoses. Elastography has also been used to measure masseter stiffness (19) for the purpose of massage and to evaluate focal lesions in major salivary glands (20).

Limitations and Future Perspectives

The main pitfall of elastography is the inability to control the extent of tissue compression by the ultrasound transducer. This was shown to be extremely difficult in external ultrasound elastography, where images obtained during application of strong pressure can lead to misdiagnosis (11). Recently, investigators have used acoustic radiation force impulse (ARFI) imaging to overcome this fault (21). ARFI imaging uses radiation impulses to induce localized displacement of tissues, then monitors the dynamic response of tissues to the induced displacement (22). The use of volumetric measurement to assess the stiffness of the whole lymph node might increase the diagnostic performance of elastography. Also, further studies of the use of elastography in the characterization of small lesions are necessary (11).

Some strain images of large lymph nodes are suboptimal because probe contact over large lesions may not be adequate and because the movement of surrounding tissues and vessels during compression scanning can result in artifacts. In addition, regions of interest in large lymph nodes include only the nodes themselves, thereby excluding surrounding tissue, which affects the strain presentation of both normal and abnormal structures. Also, some cervical lymph nodes are close to great vessels, the pulse of which can affect the technique of the sonographer (10). Hence, a suspicious area should be re-examined after tilting the US probe (23).

To further decrease interobserver variability, the force can be adjusted by using a visual compression indicator on the video screen. Secondly, to equalize the necessary pressure, balloon systems indicating the force of compression can be integrated into the probes (23).

As historians of science have pointed out, good techniques are instrumental in producing desirable results, which then eventually require a new technique to address them. With its high specificity, elastography can improve the performance of sonography in the diagnosis of enlarged metastatic cervical lymph nodes. Although elastography has progressed rapidly in the past several years, much progress is needed before it becomes a viable clinical tool. The images displayed consist of various colors, which might make it easier for general dental practitioners to diagnose oral cancers. Thus, we have every reason to believe that, with continued development, ultrasonography will become a more objective diagnostic tool. Elastography has a bright future in detecting cervical lymphadenopathy, thereby improving the diagnosis and prognosis of oral cancer.

References

1. Peacock ZS, Pogrel MA, Schmidt BL (2008) Exploring the reasons for delay in treatment of oral cancer. J Am Dent Assoc 139, 1346-1352.
2. Lingen MW, Kalmar JR, Karrison T, Speight PM (2008) Critical evaluation of diagnostic aids for the detection of oral cancer. Oral Oncol 44, 10-22.
3. Shellenberger TD (2006) Sentinel lymph node biopsy in the staging of oral cancer. Oral Maxillofacial Surg Clin North Am 18, 547-563.
4. Alam F, Naito K, Horiguchi J, Fukuda H, Tachikake T, Ito K (2008) Accuracy of sonographic elastography in the differential diagnosis of enlarged cervical lymph nodes: comparison with conventional B-mode sonography. AJR Am J Roentgenol 191, 604-610.
5. Parisi E, Glick M (2005) Cervical lymphadenopathy in the dental patient: a review of clinical approach. Quintessence Int 36, 423-436.
6. Oeppen RS, Gibson D, Brennan PA (2010) An update on the use of ultrasound imaging in oral and

maxillofacial surgery. Br J Oral Maxillofac Surg 48, 412-418.
7. Breeze J, Williams MD, Howlett DC (2008) Ultrasound guided localisation during the excision of an impalpable branchial cyst. Br J Oral Maxillofac Surg 46, 686-687.
8. Whittingham TA (1997) New and future developments in ultrasonic imaging. Br J Radiol 70, S119-132.
9. Ophir J, Céspedes I, Ponnekanti H, Yazdi Y, Li X (1991) Elastography: a quantitative method for imaging the elasticity of biological tissues. Ultrason Imaging 13, 111-134.
10. Tan R, Xiao Y, He Q (2010) Ultrasound elastography: its potential role in assessment of cervical lymphadenopathy. Acad Radiol 17, 849-855.
11. Itoh A, Ueno E, Tohno E, Kamma H, Takahashi H, Shiina T, Yamakawa M, Matsumura T (2006) Breast disease: clinical application of US elastography for diagnosis. Radiology 239, 341-350.
12. Giovannini M, Hookey LC, Bories E, Pesenti C, Monges G, Delpero JR (2006) Endoscopic ultrasound elastography: the first step towards virtual biopsy? Preliminary results in 49 patients. Endoscopy 38, 344-348.
13. Harvey CJ, Pilcher JM, Eckersley RJ, Blomley MJ, Cosgrove DO (2002) Advances in ultrasound. Clin Radiol 57, 157-177.
14. Ophir J, Garra B, Kallel F, Konofagou E, Krouskop T, Righetti R, Varghese T (2000) Elastographic imaging. Ultrasound Med Biol 26, S23-29.
15. Jank S, Robatscher P, Emshoff R, Strobl H, Gojer G, Norer B (2003) The diagnostic value of ultrasonography to detect occult lymph node involvement at different levels in patients with squamous cell carcinoma in the maxillofacial region. Int J Oral Maxillofac Surg 32, 39-42.
16. Ahuja A, Ying M (2002) An overview of neck node sonography. Invest Radiol 37, 333-342.
17. Lyshchik A, Higashi T, Asato R, Tanaka S, Ito J, Hiraoka M, Insana MF, Brill AB, Saga T, Togashi K (2007) Cervical lymph node metastases: diagnosis at sonoelastography – initial experience. Radiology 243, 258-267.
18. Krestan C, Herneth AM, Formanek M, Czerny C (2006) Modern imaging lymph node staging of the head and neck region. Eur J Radiol 58, 360-366.
19. Ariji Y, Katsumata A, Hiraiwa Y, Izumi M, Iida Y, Goto M, Sakuma S, Ogi N, Kurita K, Ariji E (2009) Use of sonographic elastography of the masseter muscles for optimizing massage pressure: a preliminary study. J Oral Rehabil 36, 627-635.
20. Bhatia KS, Rasalkar DD, Lee YP, Wong KT, King AD, Yuen HY, Ahuja AT (2010) Evaluation of real-time qualitative sonoelastography of focal lesions in the parotid and submandibular glands: applications and limitations. Eur Radiol 20, 1958-1964.
21. Yoneda M, Suzuki K, Kato S, Fujita K, Nozaki Y, Hosono K, Saito S, Nakajima A (2010) Nonalcoholic fatty liver disease: US-based acoustic radiation force impulse elastography. Radiology 256, 640-647.
22. Fahey BJ, Nightingale KR, Nelson RC, Palmeri ML, Trahey GE (2005) Acoustic radiation force impulse imaging of the abdomen: demonstration of feasibility and utility. Ultrasound Med Biol 31, 1185-1198.
23. Pallwein L, Aigner F, Faschingbauer R, Pallwein E, Pinggera G, Bartsch G, Schaefer G, Struve P, Frauscher F (2008) Prostate cancer diagnosis: value of real-time elastography. Abdom Imaging 33, 729-735.