

Craniofacial and dental characteristics of Goldenhar syndrome: a report of two cases

Elif B. Tuna^{1,2}), Daisuke Orino²), Kei Ogawa²), Mine Yildirim¹), Figen Seymen¹),
Koray Gencay¹) and Takahide Maeda²)

¹)Department of Pedodontics, Istanbul University Faculty of Dentistry, Istanbul, Turkey

²)Department of Pediatric Dentistry, Nihon University School of Dentistry at Matsudo, Chiba, Japan

(Received 8 October 2010 and accepted 11 January 2011)

Abstract: We describe the dental and craniofacial anomalies of 2 ethnically distinct patients with Goldenhar syndrome, which is characterized by hemifacial microsomia, facial asymmetry, and ear and dental abnormalities. A 7-year-old Japanese girl and 12-year-old Turkish boy with Goldenhar syndrome were examined clinically and radiographically; both had symptoms of hemifacial microsomia. Multiple organ involvement can limit surgical correction of deformities and affect patient management. Therefore, long-term regular follow-up by a multidisciplinary team is important to monitor the growth and development of patients. (J Oral Sci 53, 121-124, 2011)

Keywords: Goldenhar syndrome; dental findings; oculoauriculovertebral dysplasia.

Introduction

Goldenhar syndrome (hemifacial microsomia, OMIM 164210) is a rare hereditary condition characterized by numerous anomalies affecting the first and second branchial arches of the first pharyngeal pouch, the first branchial cleft, and the primordia of the temporal bone (1). The incidence of this condition, also known as oculoauriculovertebral dysplasia or hemifacial microsomia, varies from 1 in 3,500 to 1 in 5,600 live births (1,2), and it is present in 1 in 1,000

children with congenital deafness. The male:female ratio of patients is approximately 3:2 (1-3).

Goldenhar syndrome is characterized by abnormalities of the face (hemifacial microsomia, unilateral facial hypoplasia, and lateral facial cleft), eyes (epibulbar dermoid or lipodermoid [mostly bilateral]; colobomas of the upper eyelid, iris, choroidea, and retina; and other eye anomalies), and ears (microtia, anotia, preauricular skin tags or blind fistulas, and other external ear malformations) (1,4,5). These clinical features are also found in combination with other malformations (6,7).

The clinical characteristics of Goldenhar syndrome vary from minor facial asymmetry to severe underdevelopment of one half of the face, with orbital deformation and microtia, or sometimes total absence of the ear (2). Goldenhar syndrome consists of the complete triad of epibulbar dermoids, accessory auricular appendages, and pretragal fistulae (6). Microtia and/or auricular tags are present in 100% of cases. Combined conductive and sensorineural hearing loss is present in approximately 50% of cases (7). A number of cases have been reported in the literature, often with other malformations, such as cardiac, renal, and central nervous system disturbances and vertebral and other skeletal anomalies. A few cases with orodontal anomalies have also been described (1,5,8).

In the present report, we describe and compare the clinical and craniofacial characteristics of a Japanese girl and Turkish boy with Goldenhar syndrome.

Case Reports

Case 1

A girl aged 7 years 7 months was referred to the Department of Pediatric Dentistry, Nihon University School

Correspondence to Dr. Elif Bahar Tuna, Department of Pedodontics, Istanbul University Faculty of Dentistry, Capa, Istanbul 34093, Turkey
Tel: +90-212-414-2020
Fax: +90-212-531-0515
E-mail: ebtuna@istanbul.edu.tr

of Dentistry at Matsudo, Chiba, Japan. She had received a diagnosis of Goldenhar syndrome at age 2 weeks. At 6 months, she underwent surgery for cleft lip repair and bilateral preauricular tags. At age 3 years, she underwent surgery for reconstruction of both auricles. At age 5 years, she underwent surgical treatment for a limbal dermoid on the left eye. Her parents were non-consanguineous, and there was no family history of this syndrome. Examination revealed no evidence of mental or developmental disability.

Clinical investigation showed asymmetry of the lower half of the face, with macrostomia and facial hypoplasia. Her chin deviated to the left side, and her profile was convex due to micrognathia (Fig. 1). During clinical examination, hearing impairment of the left ear and diminished visual acuity (right eye: 0.6; left eye: 0.3) were also diagnosed.

Intraoral examination showed contraction of the lower jaw, with midline deviation to the affected side, and protrusion of the upper incisors. Analysis of a panoramic radiograph confirmed that both mandibular second premolar teeth were congenitally missing. There was also a delayed eruption of mandibular permanent first molar teeth, and she was missing the left mandibular condylar head (Fig. 2). She had Class II malocclusion in the mixed dentition, with increased overjet and crowded maxillary and mandibular incisors.

Cephalometric analysis revealed a convex skeletal profile with an increased mandibular plane (SNA: 70°; SNB: 60°; ANB: 10°), severe Class II malocclusion, and a mandibular retrusion (Table 1).



Fig. 1 Frontal, left, and right extraoral views of case 1.

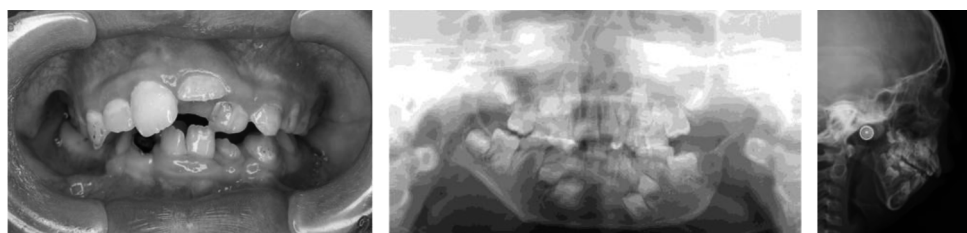


Fig. 2 Photograph and panoramic and cephalometric radiographs show intraoral view of crowding and skeletal Class II malocclusion in Case 1.

Dental treatment included extraction of the lower primary anterior teeth, and composite resin restoration for the upper and lower primary molars were performed. Permanent first molars were sealed by fissure sealant.

Case 2

A 12-year-old Turkish boy who had received a diagnosis of Goldenhar syndrome and was the child of a consanguineous marriage between 2 first-degree cousins was examined at the Department of Pedodontics, Istanbul University Faculty of Dentistry, Istanbul, Turkey. He was born at full term after a normal delivery, and there was no history of any maternal illness during pregnancy. He had 1 sibling, who had no signs of congenital anomalies. The remaining family history was unremarkable. Mental and developmental disabilities were present. There were no vertebral, skeletal, or cardiovascular anomalies.

An extraoral examination showed marked left facial hypoplasia, with the chin deviated to the affected side. Mandibular hypoplasia, hypertelorism, and bilateral microtia were also present (Fig. 3). Both of the patient's auricles were attached at birth. He had undergone 2 ear reconstruction surgeries and is scheduled for treatment of obstruction of the auditory canal. Bilateral hearing loss (hypoacusia) was 56.6%. An ophthalmic examination revealed obstruction anomalies in both eyes.

Table 1 Results of cephalometric analysis of cases

Parameter	Case I	Case II
SNA (°)	70.0	86.5
SNB (°)	60.0	81.0
ANB (°)	10.0	5.5
Upper incisor-NA (°)	14.0	24.0
Lower incisor-NB (°)	17.5	30.0
Pg-NB (°)	2.5	1.5
Interincisal angle (°)	140.0	122.0
GoGn/SN (°)	54.0	37.0
Steiner's line to upper lip/lower lip (mm)	5 / 5.5	0.5 / 4.5

Intraoral examination showed a mixed dentition stage with severe asymmetric occlusion, crowding, and severe anterior crossbite. There was no cleft lip or palate. The anatomy of the tongue and the level of attachment of the maxillary and mandibular frenula appeared normal.

Panoramic radiograph examination confirmed that all permanent teeth were present, including the third molars. The left mandibular second premolar was rotated because of early extraction of the primary left molar in the same region. The left mandibular first permanent molar and left maxillary primary molar teeth had deep dental caries (Fig. 4). Cephalometric analysis showed a retrognathic facial pattern with skeletal Class II occlusion (SNA: 86.5°; SNB: 81°; ANB: 5.5°; Table 1).

The dental treatment plan was based on the patient's caries risk and consisted of restoration of carious teeth and extraction of the infected primary tooth. Sealants and topical fluoride products were also applied. For esthetic concerns, the patient was referred to the orthodontic department for alignment of the teeth.

Discussion

Goldenhar syndrome was first described in 1952 by Maurice Goldenhar and is characterized by microtia, hemifacial microsomia, dermoids, and vertebral anomalies (9). Abnormalities are unilateral in 85% of cases and bilateral in 10% to 33% of cases, and the right side is more frequently affected (2). In contrast to most previously

reported cases, both our patients had marked left facial hypoplasia with the chin slightly deviated to the affected side.

It is believed that Goldenhar syndrome is part of a more complex clinical presentation of defects of the first and second branchial arches. The etiology of this rare disease is not fully understood, as it is genetically variable. Although the majority of Goldenhar syndrome cases are sporadic, there are reports of familial cases with autosomal dominant inheritance and varied expression. Some cases are the product of consanguineous marriage, which suggests autosomal recessive inheritance (10). Recent research has investigated the potential interaction of environmental factors with genes, and the findings suggest the possibility of multifactorial inheritance. In our first case, the etiology was unclear, and there was no history of drug use or illness during pregnancy. In our second case, the anomalies may have been the result of a consanguineous marriage, since consanguinity is an important contributing factor in congenital malformations.

Dentofacial anomalies may include cleft lip and palate, a crease over the lateral commissure of the mouth, a highly arched palate, hypoplasia of the maxillary and mandibular arches, micrognathia, gingival hypertrophy, supernumerary teeth, enamel and dentin malformations, and delayed tooth development (2). Malocclusion and macrostomia due to the presence of an underdeveloped lower jaw have also been observed. Moreover, patients often show asymmetric development of the muscles of the masticatory system and agenesis of salivary glands (2). In case 1, the patient had malocclusion, agenesis of the third and second premolars on the affected side, malformed teeth, and delayed tooth development. Severe anterior malocclusion and malformed teeth were also seen in case 2.

Facial asymmetry and hypoplasia of the mandible are typical features of Goldenhar syndrome (8). Craniofacial anomalies, including hemifacial microsomia and malar and maxillary hypoplasias, are present in 50% of patients with

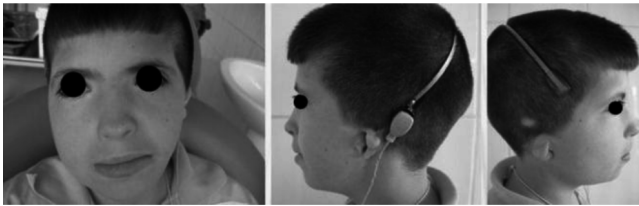

Fig. 3 Frontal, left, and right extraoral views of case 2.

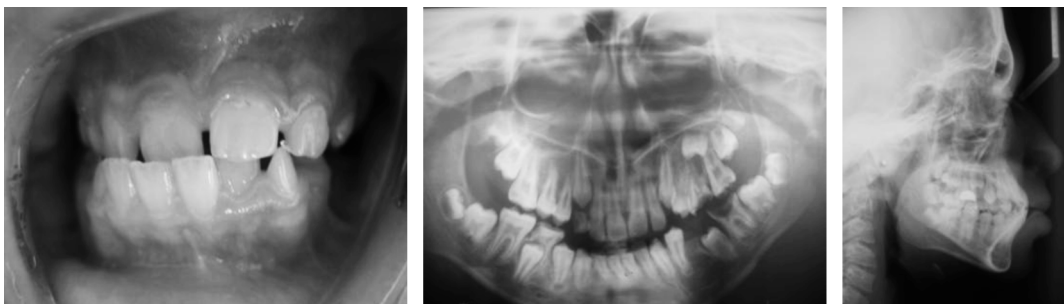


Fig. 4 Photograph and panoramic and cephalometric radiographs show intraoral view of normal permanent dentition development with anterior crossbite in case 2.

this disorder. Unilateral facial involvement is more common (1,6). Hemifacial microsomia is a flattening of the face due to an underdeveloped mandible (micrognathia), maxilla, and zygomatic bones with hypoplastic muscles for mastication and facial expression (11). Cephalometric analysis of case 1 showed a convex profile, skeletal Class II malocclusion, and a high-angle growth pattern with maxillary and mandibular bradyauxesis. In case 2, a moderate facial pattern, bimaxillary protrusion, skeletal Class I occlusion, and an anterior crossbite were observed.

The effect of Goldenhar syndrome is more evident as the child grows, because of delays in the growth and development of the affected areas. The lack of development of the upper and lower jaws can cause breathing problems, as well as dental malocclusion, which require surgical and/or orthodontic treatment. There are several methods of surgical treatment, such as conventional surgical procedures (costochondral rib graft and classical osteotomy) and the distraction technique. Using the distraction technique, it is possible to lengthen the jaw and the ramus of the mandible to the desired size; however, this technique does not result in normal growth and function of the temporomandibular joint. In addition, there is a risk of mild infection during the period of lengthening (2).

Taken together, our findings indicate that multiple-organ involvement can limit surgical correction of deformities and affect the management of patients with Goldenhar syndrome. Treatment of deformities requires multiple procedures performed by a multidisciplinary team, and long-term regular follow-up is important to monitor the growth and development of patients.

References

1. Kokavec R (2006) Goldenhar syndrome with various clinical manifestations. *Cleft Palate Craniofac J* 43, 628-634.
2. Bielicka B, Necka A, Andrych M (2006) Interdisciplinary treatment of patients with Goldenhar syndrome – clinical reports. *Dent Med Probl* 43, 458-462.
3. Kulkarni VV, Shah MD, Parikh AA (1985) Goldenhar syndrome: a case report. *J Postgrad Med* 31, 177-179.
4. Garcia de Paula e Silva FW, de Carvalho FK, Diaz-Serrano KV, de Freitas AC, Borsatto MC, de Queiroz AM (2007) Solitary median maxillary central incisor in association with Goldenhar's syndrome: a case report. *Spec Care Dentist* 27, 105-107.
5. Vinay C, Reddy RS, Uloopi KS, Madhuri V, Sekhar RC (2009) Craniofacial features in Goldenhar syndrome. *J Indian Soc Pedod Prev Dent* 27, 121-124.
6. Jena AK, Duggal R (2006) Atypical goldenhar syndrome: a case report. *J Clin Pediatr Dent* 31, 118-122.
7. Ottaviano G, Calzolari F, Martini A (2007) Goldenhar syndrome in association with agenesis of the internal carotid artery. *Int J Pediatr Otorhinolaryngol* 71, 509-512.
8. Pinheiro AL, Araújo LC, Oliveira SB, Sampaio MC, Freitas AC (2003) Goldenhar's syndrome – case report. *Braz Dent J* 14, 67-70.
9. Goldenhar M (1952) Associations malformatives de l'oeil et de l'oreille, in particulier le syndrome dermoide epibulbaire-appendices auriculaires fistule auris congenita et ses relations avec la dysostose mandibulofaciale. *J Genet Hum* 1, 243-282. (in French)
10. Regenbogen L, Godel V, Goya V, Goodman RM (1982) Further evidence for an autosomal dominant form of oculoauriculovertebral dysplasia. *Clin Genet* 21, 161-167.
11. Das A, Ray B, Das D, Das S (2008) A case of Goldenhar-Gorlin syndrome with unusual association of hypoplastic thumb. *Indian J Ophthalmol* 56, 150-152.