

Cemento-osseous dysplasia in an elderly Asian male: a case report

Takashi Komabayashi¹⁾ and Qiang Zhu²⁾

¹⁾Department of Endodontics, Texas A&M Health Science Center Baylor College of Dentistry,
Dallas, TX, USA

²⁾Division of Endodontology, Department of Oral Health and Diagnostic Sciences, School of Dental Medicine,
University of Connecticut, Farmington, CT, USA

(Received 8 September and accepted 24 November 2010)

Abstract: Cemento-osseous dysplasia is a disorder typically found in middle-aged black women. However, the present report describes a case in a 61-year-old Vietnamese male. Without proper pulp testing and diagnosis, the radiographic presentation can easily be misdiagnosed as periapical periodontitis. On the basis of pulp vitality, lack of clinical symptoms and radiographic features, the diagnosis in this case was periapical cemento-osseous dysplasia at the mixed stage, which generally requires no treatment. At the 18-month follow-up, the patient was still asymptomatic and none of the clinical signs had changed. This case highlights the importance of careful clinical examination, including a pulp vitality test, and of having an unbiased view of age, gender, and ethnicity when diagnosing this condition. (*J Oral Sci* 53, 117-120, 2011)

Keywords: cemento-osseous dysplasia; pulp test; periapical periodontitis.

Introduction

Cemento-osseous dysplasia (COD) is an asymptomatic benign condition whose etiology and pathogenesis are unknown. No treatment is necessary for COD unless symptoms are noted. COD is classified by the World

Health Organization into three subtypes: periapical, focal, and florid. All three subtypes demonstrate three stages of maturation in accordance with unique periapical radiographic findings: early (radiolucency without radiopacity inclusion), mixed (radiolucency with radiopacity inclusion), and mature (radiopacity) (1). Periapical cemento-osseous dysplasia (PCOD) occurs most frequently in the lower anterior teeth of middle-aged black women (2,3). Even though the lesion may be solitary, in most cases multiple foci are present. PCOD is asymptomatic and the involved teeth are vital. Focal cemento-osseous dysplasia (focal COD) appears as a single lesion, and the posterior mandible is the most commonly affected site. Like PCOD, most cases of focal COD occur in middle-aged women, but more frequently in whites. Florid cemento-osseous dysplasia (florid COD) shows multifocal involvement. The lesions are often bilateral and occur in both jaws (1). A systematic review of the literature on COD indicates an ethnicity distribution of 59%, 37%, and 3% for blacks, Asians (Japanese, Chinese, and Korean), and Caucasians (including Indian cases), respectively, in case reports (4). The epidemiology of florid COD is similar to that of PCOD (1). Up to now, no Vietnamese case has been reported. There have been many reports of COD cases that were subjected to inappropriate root canal treatment, for which the authors regretted having misdiagnosed. However, reports of cases for which unnecessary treatment was avoided, and were followed up for a long period, are scarce. Here we present a case of mixed-stage PCOD in a 61-year-old Vietnamese male with the results of 18-month follow-up.

Correspondence to Dr. Takashi Komabayashi, Department of Endodontics, Texas A&M Health Science Center Baylor College of Dentistry, 3302 Gaston Avenue, Dallas, TX 75246 USA
Tel: +1-214-828-8365
Fax: +1-214-874-4507
E-mail: tkomabayashi@bcd.tamhsc.edu & ICD38719@nifty.com

Case Report

A 61-year-old Vietnamese male (Fig. 1) was referred from a general dentist to the University of Connecticut endodontic clinic for diagnosis and possible root canal treatment of tooth #24 (left mandibular incisor). He had been advised by his previous dentist that his lower teeth required root canal work. There was no history of trauma to this area, and the patient was asymptomatic upon presentation.

The patient’s blood pressure was 130/90 in the right arm when seated, and the heart rate was 72 beats per minute and regular. His medical history included surgery on the right knee to remove a bullet in 1988, and since then had suffered some knee discomfort. There was no known drug allergy. The patient was taking Zyrtec (10 mg, qd) for seasonal allergies and Mobic (7.5 mg, qd) for arthritis of the knee. There were no contraindications to dental treatment. The American Society of Anesthesiologists Physical Status Scale was Class I.

Clinical examination revealed no lymphadenopathy of the submandibular and neck areas. The perioral and intraoral soft tissue appeared normal. No popping/clicking or deviation was observed on opening the temporomandibular joint. Upon intraoral examination, palpation of the buccal and lingual cortical plates revealed no expansion or sensitivity. The dentition was generally healthy, although attrition and cervical abrasion were significant (Figs. 2A

and 2B). Cervical abrasion was evident on teeth #25 (right mandibular incisor) and #26 (right mandibular lateral). Class V composite resin restorations were observed on teeth #22 (left mandibular canine), #23 (left mandibular lateral), and #24 (left mandibular incisor) (Fig. 2A). There was moderate to severe attrition of the teeth overall (Fig. 2B), and dental calculus and stains on the lower anterior lingual side were notable (Fig. 2C). The intraoral soft tissues

Table1 Clinical evaluation (diagnostic procedures) summary

Tooth #	22	23	24	25	26	27
Percussion	-	-	-	-	-	-
Palpation	-	-	-	-	-	-
Endo ice	+	+	+	+	+	+
EPT	+	+	+	+	+	+

(+; Response, -; No response)

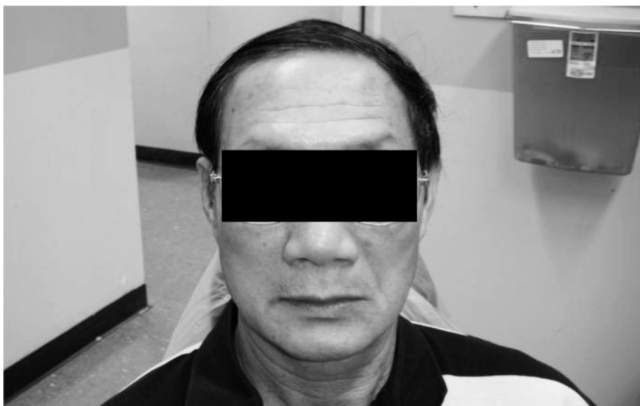
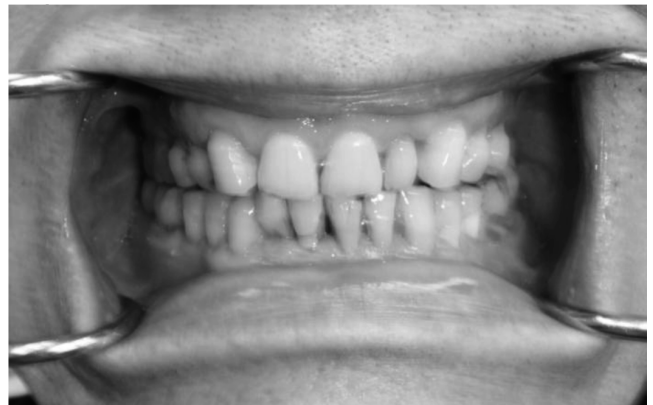
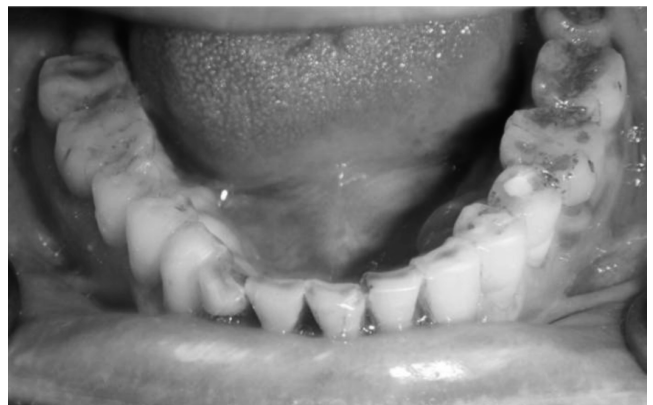
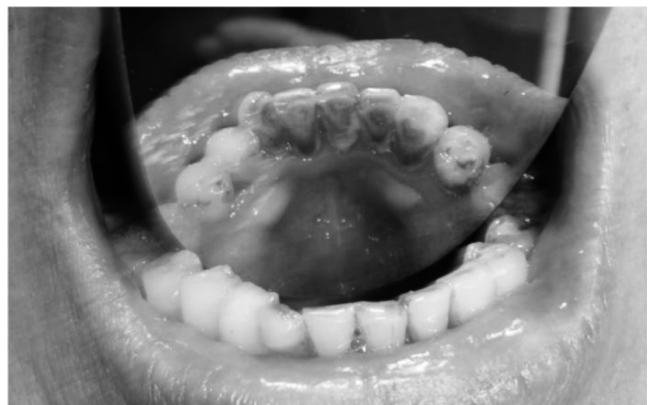Fig. 1 The patient, a 61-year-old Vietnamese male.



A



B



C

Fig. 2 Intraoral clinical pictures. A: Center view. B: Occlusal view. C: Lingual view.

appeared to be healthy in color and texture. Periodontal probing depths were all less than 3 mm, and no mobility of teeth # 22 – 27 was detected. Clinical evaluations (diagnostic procedures) are summarized in the Table. Endodontic examinations and tests such as percussion, palpation, cold testing (Hygenic Endo Ice, Coltene Whaledent, Cuyahoga Falls, OH, USA), and an electrical pulp test (EPT, Analytic Technology, Redmond, WA, USA) were conducted. This revealed that teeth #22 – 27 all had vital pulp.

A diagnostic radiograph was taken using a positioning device (XCP, Dentsply Rinn, Elgin, IL, USA) (Fig. 3), and this revealed an ill-defined radiolucent lesion measuring approximately 4 × 6 mm associated with tooth #24. Within the lesion, a radiopaque area measuring approximately 2 × 4 mm was evident. There was radiolucency at the cervical level in teeth #22, #23, #24, and #26, and tooth #25 had a radiopaque appearance.

Based on the clinical and radiographic information for tooth #24, the most likely clinical pulp diagnosis was normal pulp, and the periradicular diagnosis was PCOD at the mixed stage. We also consulted an oral pathologist about this case, who agreed with our diagnosis. The endodontic evaluation was discussed with the patient, and no treatment was recommended.

The patient visited us again for an 18-month follow-up examination. He was still asymptomatic, with no change in his medical condition. A radiograph was taken using a digital radiograph system (Schick CDR, Schick Technology, Long Island City, NY, USA) (Fig. 4). Upon comparison

with the previous diagnostic radiograph (Fig. 3), a slight increase of calcification was seen around the borders of the lesion of tooth #24. All the lower anterior teeth tested vital. No tenderness to percussion or palpation was elicited, and the periodontal probing depths were all <3 mm. No further treatment was recommended.

Discussion

Fibrous dysplasia, ossifying fibroma, cementifying fibroma, hypercementosis, cementoblastoma, and PCOD were all included in the differential diagnosis of the present case based on the radiographic appearance. Fibrous dysplasia is primarily a disease of childhood during the period of skeletal growth. The most commonly affected site is the maxillary premolar region. Ossifying fibroma has the highest prevalence among teenagers. It appears more often on the maxilla than in the mandible, and is frequently in the area around the incisors and canines. Cementifying fibroma is more prevalent in females than in males, and appears more often in the molar/premolar region of the mandible (5). Cementoblastoma is usually fused to the root. The lesion appears as a radiopaque mass with a radiolucent halo. Hypercementosis is deposition of excessive cementum around the root. It is characterized radiographically by the presence of a normal periodontal ligament space and lamina dura. Based on the location, epidemiologic data, pulp test result (vital pulp), and radiographic appearance, the most likely clinical diagnosis was mixed-stage PCOD. PCOD usually occurs in middle-aged black women. This patient was an Asian male, and therefore the circumstances

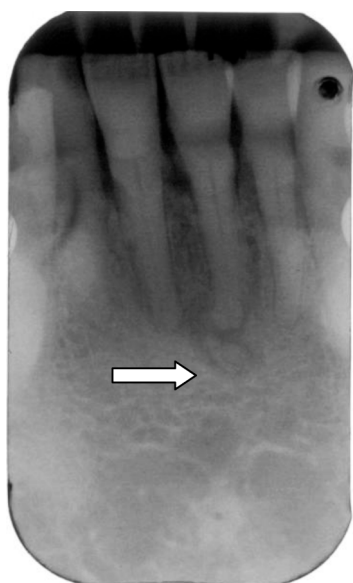


Fig. 3 Diagnostic radiograph (Arrow; Periapical COD [Mixed stage]).

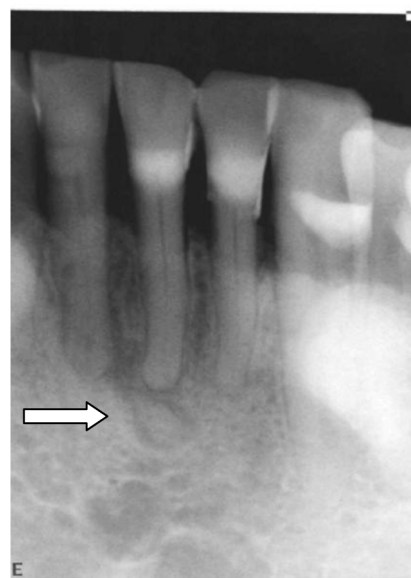


Fig. 4 Eighteen-month follow-up radiograph (Arrow; Periapical COD [Mixed stage]).

were unusual. The endodontic evaluation was discussed with the patient, and no treatment was recommended. Follow-up was important to identify any possible progression and associated complications, as the clinical diagnosis was provisional. After 18 months, no change was observed, and thus our conclusion was that the provisional and final diagnoses were the same.

Knowledge of periapical radiolucency is essential in dental practice because COD mimics radiographic endodontic pathosis, especially when early-stage lesions cause radiolucency without radiopacity inclusion or when mixed-stage lesions cause radiolucency with radiopacity inclusion. The pulp of a tooth must be necrotic in order to cause enough apical bone resorption to be seen as a periapical inflammatory lesion (6). Thus, root canal treatment is not effective if the pulp of the tooth is vital, as determined by a pulp test. Dentists should not rely on radiographic findings alone. Without proper pulp testing and diagnosis, the radiographic presentation in the periapical area could easily be misdiagnosed as periapical periodontitis. In this case, the diagnosis was vital pulp, and thus the case was considered to be mixed-stage PCOD, which generally requires no treatment. Effective teamwork between the general dentist and the endodontist prevented unnecessary root canal treatment, thus saving time and resources, and contributing to patient welfare. With increased knowledge about COD and the use of pulp testing for an accurate diagnosis, dentists can save the pulp and teeth of more patients, thus contributing significantly

to dental public health.

Acknowledgments

This case was undertaken when Dr. Komabayashi was an endodontic resident/master degree student at the University of Connecticut.

References

1. Resnick CM, Novelline RA (2008) Cemento-osseous dysplasia, a radiological mimic of periapical dental abscess. *Emerg Radiol* 15, 367-374.
2. Zegarelli EV, Kutscher AH, Napoli N, Iurono F, Hoffman P (1964) The cementoma. A study of 230 patients with 435 cementomas. *Oral Surg Oral Med Oral Pathol* 17, 219-224.
3. Young SK, Markowitz NR, Sullivan S, Seale TW, Hirschi R (1989) Familial gigantiform cementoma: classification and presentation of a large pedigree. *Oral Surg Oral Med Oral Pathol* 68, 740-747.
4. MacDonald-Jankowski DS (2003) Florid cemento-osseous dysplasia: a systematic review. *Dentomaxillofac Radiol* 32, 141-149.
5. Natkin E (1990) Zebra hunt. *Zebra V*, Part 2. *J Endod* 16, 552-555.
6. Kakehashi S, Stanley HR, Fitzgerald RJ (1965) The effects of surgical exposures of dental pulps in germ-free and conventional laboratory rats. *Oral Surg Oral Med Oral Pathol* 20, 340-349.