Journal of Oral Science, Vol. 52, No. 1, 49-54, 2010

Original

ConA and UEA-I lectin histochemistry of parotid gland mucoepidermoid carcinoma

Ana Paula V. Sobral[1,2], Moacyr J. B. M. Rego[1], Carmelita L. B. Cavalacanti[1], Luiz B. Carvalho Jr[1,3] and Eduardo I. C. Beltrão[1,3]

[1]Keizo Asami Immunopathology Laboratory (LIKA), Federal University of Pernambuco (UFPE), Recife, Brazil
[2]Oral Pathology Laboratory, Dentistry College, Pernambuco University (UPE), Camaragibe, Brazil
[3]Biochemistry Department, Biological Science Center, Federal University of Pernambuco (UFPE), Recife, Brazil

(Received 4 June and accepted 27 November 2009)

Abstract: Mucoepidermoid carcinoma (MEC) corresponds to 5-12% of all salivary gland tumours, and is classified as low, intermediate or high grade. Traditionally, immunohistochemistry was considered as the complementary tool for diagnosis of salivary gland neoplasia. Lectin histochemistry has also been increasingly used in recent years. In this work, lectins were used as histochemical markers for normal and transformed parotid glands. Biopsy specimens of 15 cases diagnosed as MEC (low, intermediate and high grade) of the parotid gland were trypsin- and methanol-H_2O_2-treated and incubated with horseradish peroxidase (HRP)-conjugated lectins, Concanavalin A (Con A-HRP) and *Ulex europeus* I (UEA-I-HRP). Con A stained the neoplasic cells of MEC (all grades). In high and intermediate cases, ductal cells were weakly stained by Con A. UEA-I weakly stained normal cells of the excretory duct and neoplasic cells in high grade. Neoplasic cells in intermediate grade were moderately stained and in low grade, the cell membrane was intensely stained with UEA-I. Stroma presented a direct relation between malignancy and staining intensity for UEA-I. The results indicated that lectin histochemistry distinguished the cell biology among histological grades of MEC. (J Oral Sci 52, 49-54, 2010)

Correspondence to Dr. Ana Paula Veras Sobral, Rua Monte Alverne, 107/05, Hipódromo – Recife – PE 52041-610 – Brazil
Tel: +55-81-34581088
Fax: +55-81-34586758
E-mail: anapvsobral@yahoo.com.br & anapaula@fop.upe.br

Keywords: parotid gland; lectin histochemistry; mucoepidermoid carcinoma.

Introduction

Carbohydrates have an enormous potential for encoding biological information. These combination molecules (in glycoproteins and glycolipids) dot the outer surface of all cells and serve as cellular identification tags to the surrounding world (1). The extracellular matrix (ECM) provides a physical framework for cellular attachment and facilitates normal physiological regulation of cell proliferation, migration and differentiation (2).

Lectins are structurally diverse carbohydrate-binding proteins or glycoproteins of non-immune origin (3) that agglutinate cells and recognize carbohydrates in oligosaccharides and glycoconjugates (4). By virtue of their binding specifities, lectins have been used in the medical and biological areas. In histochemistry, lectins with different carbohydrate specificity can provide a sensitive detection system for changes in glycosylation and carbohydrate expression that may occur during embryogenesis, growth and disease. Tumour lectinology has so far shown cytochemical and histochemical differences between normal and transformed tissues such as mammary (5,6), brain (7), oral tissues (8), lung (9) and within a single class of tumour (10).

Quantitative and qualitative changes in glycoconjugates of cell outer and inner membranes could be significant in the development and progression of pathologies, including

neoplasias. Higher or weaker and even the absence of staining patterns between normal and transformed tissues suggest derangement of secretory mechanisms. The observation that, in general, the more anaplastic the cell becomes, more intense its staining, seems to indicate that the site and nature of cell-surface glycoconjugates are altered. In addition, tissue factors may influence and induce differentiation/dedifferentiation reflected in the different lectin binding patterns (7).

Mucoepidermoid carcinoma (MEC) is the most common malignant salivary tumour, corresponding to 5-12% of all salivary gland tumours, and is classified as low, intermediate or high grade. Salivary gland tumours are classified essentially based on morphology (11) and MEC is characterized by the presence of various cell types resembling the excretory duct of salivary glands and its configuration varies with the degree of malignancy (12). Regarding the pathology of salivary gland tumours, discussions related to morphology, pathogenesis, diagnosis and classification have taken place specially to characterize the constituent tumour cells to establish differences among tumour types.

This work aimed to evaluate the use of Concanavalin A (Con A-HRP) and *Ulex europeus* I (UEA-I-HRP) in histochemistry for the characterization of glucose and/or mannose and L-fucose profile in mucoepidemoid carcinoma of the major salivary gland.

Materials and Methods

Specimens

Fifteen cases of mucoepidermoid carcinoma of the parotid gland (low grade, $n = 5$; intermediate grade, $n = 5$ and high grade, $n = 5$) classified according to WHO (13), and 15 normal salivary glands were obtained from the Tissue Archives of the Oral Pathology Department, School of Dentistry, University of the State of Pernambuco (UPE). This work was approved by University of Pernambuco Ethical Committee.

Lectin histochemistry:

Four-micrometer-thick sections of the specimens were deparaffinized in xylene and dehydrated in graded series of alcohol (100-70%). Slices were treated with 0.1% (w/v) trypsin solution for 2 min at 37°C and with a 0.3% (v/v) methanol-H_2O_2 solution for 30 min at 25°C and then incubated with HRP-conjugated lectins (Con A-HRP and UEA-I-HRP at 50 µg/ml). PBS (10 mM phosphate buffer, pH 7.2, 150 mM NaCl) was used to prepare all solutions and as washing solution between each step. Peroxidase was visualized with a solution of diaminobenzidine-H_2O_2 for 5-8 min. Haematoxylin was used for counter-staining. Tissues were evaluated by light microscopy. Lectin-binding inhibition assays were developed by incubating lectin with its corresponding specific sugars, methyl-α-D-mannoside for Con A and L-fucose for UEA-I (100 to 500 mM) prior to sample incubation.

Results

In normal parotid gland, myoepithelial cells and vascular endothelium were weakly stained by Con A and UEA-I. Acinar and luminal cells of the excretory ducts were also recognized by UEA-I with a weak staining pattern.

Neoplasic cells in all cases of MEC were stained by Con A (glucose and mannose specific) with intense staining of the cytoplasm and/or membrane (Fig. 1). Intermediate grade MEC presented a moderate staining with Con A, and this was the highest staining pattern among the three grades (Fig. 1c). Neoplasic stroma was not stained with Con A in high grade MEC, while low and intermediate grades were weakly stained. Vascular endothelium and duct structure were differentially stained with Con A (Table 1).

The UEA-I staining pattern varied from weak to intense for neoplasic cells. The staining in low grade MEC was intense in the cytoplasm and membrane (Fig. 2a). Stroma, connective tissue around the neoplasic cells, was not stained by UEA-I in low grade MEC (Fig. 2b), but was weakly stained in the intermediate grade (Fig. 2c) and intensely stained in high grade (Fig. 2d). Detailed results are presented in Table 1.

Tissue staining was completely abolished in lectin binding inhibition assays using methyl-α-D-mannoside for Con A and L-fucose for UEA-I at 300 mM. This concentration was the lowest, with the highest inhibition as well as the lowest background staining.

Discussion

Clinicopathologic investigations have described that recurrence and overall survival in MEC of salivary glands are linked to tumour grade and size, clinical stage of disease, perineural and vascular involvement, and lymph node distant metastasis. MEC is a unique epithelial neoplasm composed of epidermoid, mucous and intermediate cells in variable proportions. The architecture of this neoplasm varies from predominantly cystic with abundant mucous cells to exclusively solid nests and sheets of epidermoid cells with squamoid differentiation and a paucity of intermediate cells. Historically, this neoplasm presents clinical behaviour dependent upon its histopathologic appearance varying from a relatively benign neoplasm with a low grade morphology to an extremely aggressive neoplasm which has a high mortality (12,14).

Glycoproteins are a family of complex proteins carrying

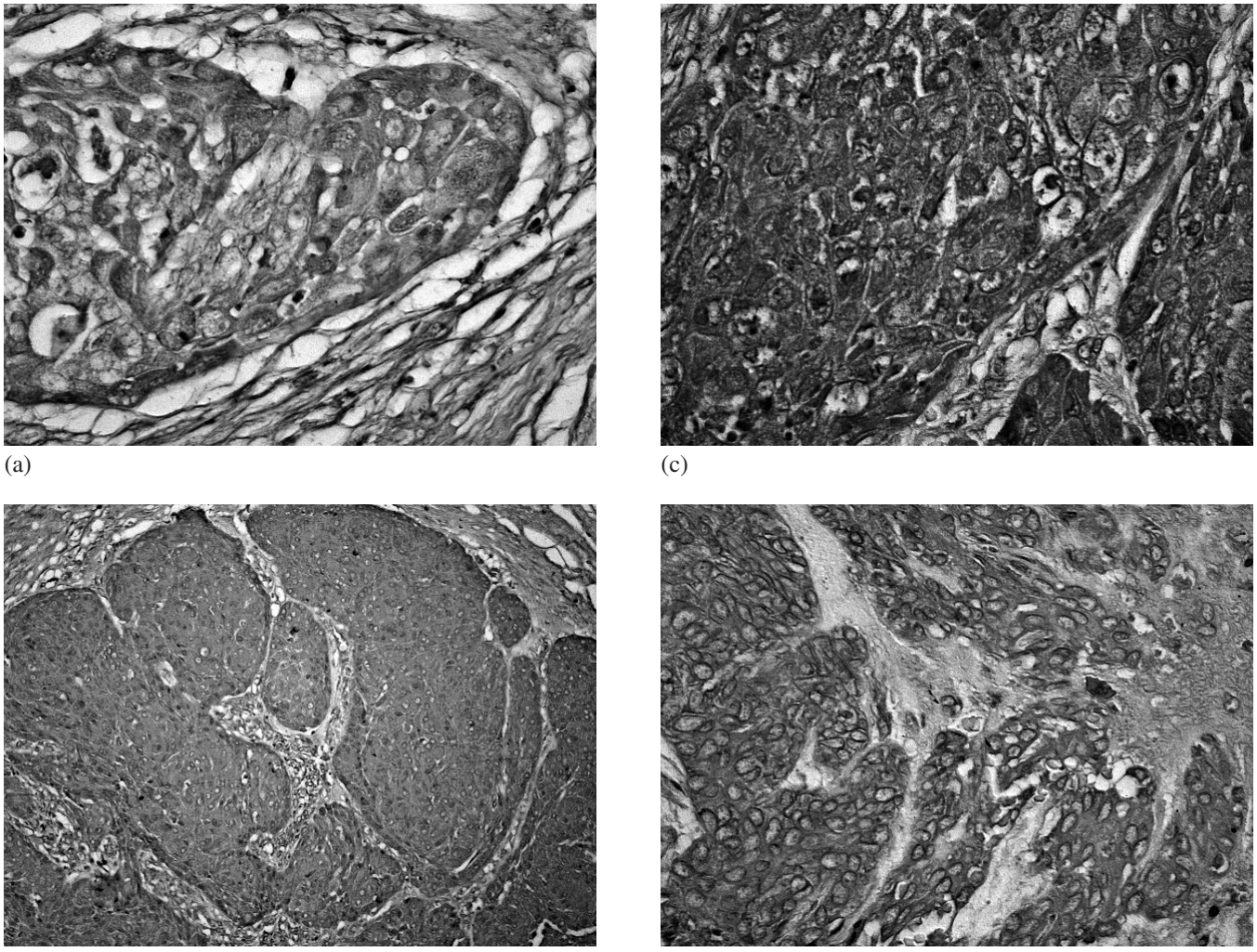

Fig. 1 (a) Con A-HRP staining in neoplasic cells of low grade MEC (×100), (b) intermediate grade MEC (×100) and (c) (×400) and high grade MEC (d).

covalently linked oligosaccharide chains. In the oligosaccharides, the monosaccharide moiety is hexosamines in the acyl form, neutral sugar such as glucose, galactose, fucose, and mannose and various derivatives of sialic acid (*N*-acetyl neuraminic acid). These monosaccharide units can attach to one another at multiple points, forming branches. Two identical monosaccharides can link to form 11 different disaccharides (1,15). Neoplastic transformation is associated with altered cell surface carbohydrate composition of the cell membrane and the changes in the surface of tumour cells are relevant to their abnormal growth, metastasis and changes in cell adhesion (16).

Lectins decipher glycocodes, recognizing specific sugars to carry out various functions such as cell attachment, migration or invasion. Glycocodes are different from either codes of the nucleotides in nucleic acids and the amino acids in proteins, which can interconnect linearly. Among all of the variety of adhesion molecules, cell-surface carbohydrate structures have been the focus of many investigative efforts. Typically, lectins and their complimentary carbohydrate are located on the surfaces of opposing cells, which can be of the same type or different types. Their interactions are required for cell differentiation, development and pathological states (15). Cancer cells use carbohydrate moieties to escape recognition by the immune cells as they migrate through the body (1).

In the last two decades, it has been possible to investigate other biologic features which reflect the identity of cells. In this context, lectin histochemistry is a useful tool since invasiveness, adhesion, angiogenesis in tumour cell surroundings and apoptotic susceptibility are functionally maintained by a combination of defined molecules. These processes are affected, directly or indirectly, by *N*- and/or *O*-glycosylation of functional proteins or lipids (17). The

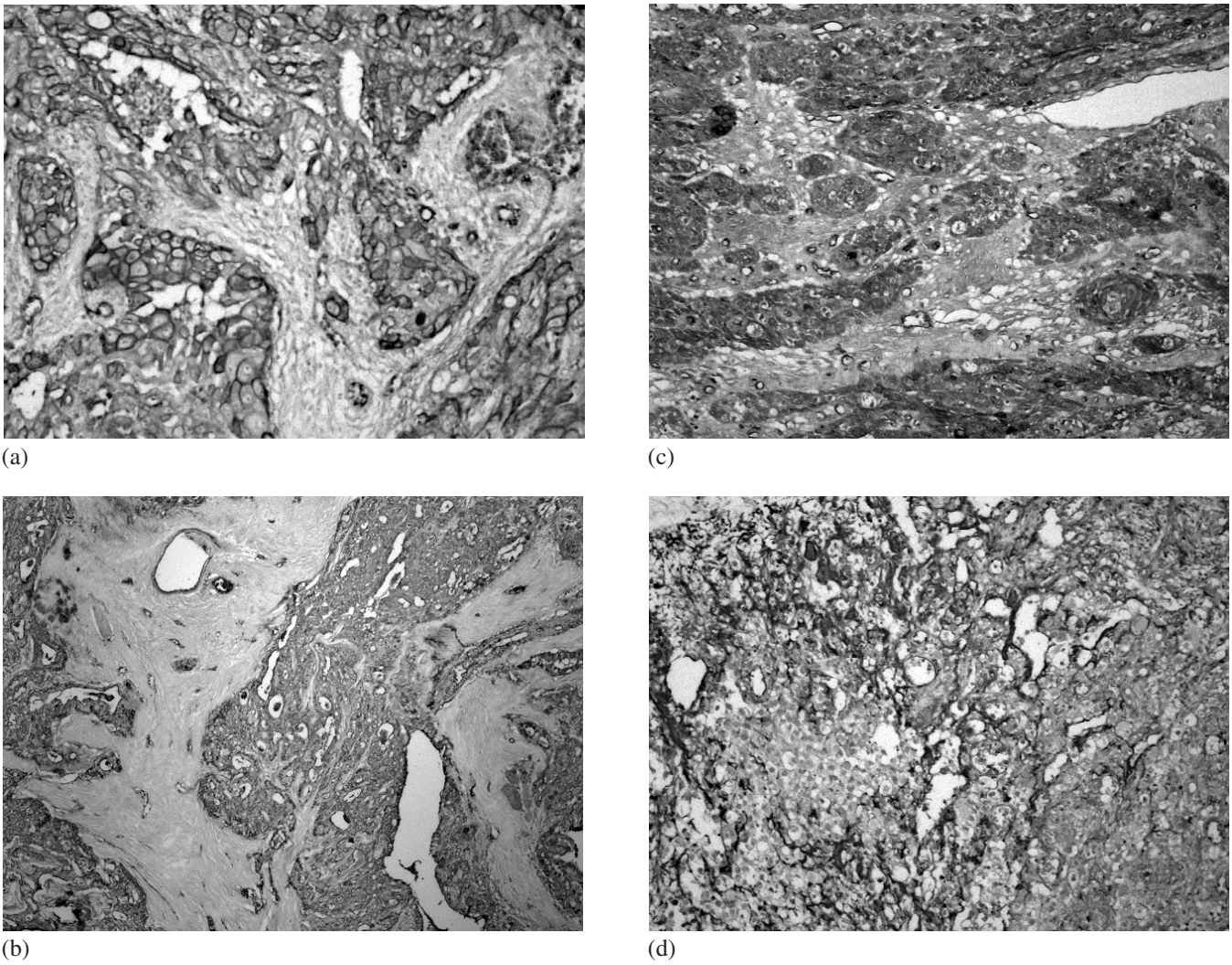

Fig. 2 (a) Cytoplasm and membrane UEA-I-HRP staining of neoplasic cell in low grade MEC. Stroma presented a direct relation between malignancy and staining intensity for UEA-I. (b) Weak stromal staining in low grade MEC (×100) (c), intermediate grade MEC shows moderate staining (×100) and (c) High grade MEC reveals intense stromal staining.

characterization of the saccharide profile is therefore indispensable for understanding many biological processes (18).

Our results present UEA-I as a marker for the differentiation of neoplasic cells in graded MEC. The staining pattern observed was inversely proportional to the grade of the pathology, i.e., the higher the grade, the lower the staining. On the other hand, stroma presented a direct relation between malignancy and staining intensity for the grade of tumours. Those findings indicate that L-fucose residues are expressed differentially in the tumours studied.

L-fucose (6-deoxy-L-galactose) is a monosaccharide that is a common component of many *N*- and *O*-linked glycans and glycolipids produced by mammalian cells. Two structural features distinguish fucose from other six-carbon sugars present in mammals. These include the lack of a hydroxyl group on the carbon at the 6-position (C-6) and the L-configuration. Fucose frequently also exists as a terminal modification of glycan structures. Fucosylated glycans have been implicated in the pathogenesis of several human diseases. Many examples of altered glycosylation in cancer involve fucose-containing oligosaccharides (19). This feature contributes to lectin histochemistry being used as an auxiliary tool to determine the prognosis and/or diagnosis of such neoplasia, especially when vimentin and smooth muscle actin (SMA) (20) and cytokeratin (21) used in immunohistochemistry fail to characterize neoplasic cells.

Con A recognized graded MEC with a weak staining pattern in most of the cell structures studied. Neoplasic cells of intermediate grade of MEC were moderately stained with this lectin, indicating that glucose/mannose is present in

Table 1 Lectin histochemistry of mucoepidermoid carcinoma of salivary gland using Con A and UEA-I

	Con A	UEA-I
Normal gland		
Vascular endothelium	+	+ ^{c}
Myoepithelial cells	+	+
Luminal duct cells	-	+
Acinar cells	-	+ ^{c}
MEC (low grade)		
Stroma	+	-
Neoplasic cells	+ $^{c/m}$	+ + + ^{m} / + ^{c}
Vascular endothelium	-	+ +
Desmoplasia	-	+
Ductal structures	-	+ + ^{m}
MEC (intermediate grade)		
Stroma	+	+
Neoplasic cells	++ $^{c/m}$	++ $^{c/m}$
Vascular endothelium	+	+ + +
Desmoplasia	-	+ + +
Ductal structures	+	+ + +
MEC (high grade)		
Stroma	-	+ + +
Neoplasic cells	+ $^{c/m}$	+ $^{c/m}$
Vascular endothelium	+	+ + +
Desmoplasia	+	+
Ductal structures	+	+

^{m} membrane staining; ^{c} *c*ytoplasm staining; $^{c/m}$ cytoplasm and/or membrane staining.
- negative staining ; + weak staining; + + moderate staining; + + + strong staining.

a higher content in this grade. Since stroma was not recognized by Con A in high grade MEC as well as vascular endothelium and desmoplasic cells, the absence and/or non availability of Con A-specific sugars are indicative of biochemical alterations in the glycosylation or glycosyl transfer pathways.

An interesting finding was observed regarding connective tissue around neoplasic cells; UEA-I strongly stained these cells in intermediate grade MEC but a weak staining was observed in the other two grades. Con A staining was weak in high grade of MEC. Studies have demonstrated that progression in grades of MEC is related to the decrease in desmoplasia. Such data suggest that there is no correlation between immunohistochemical markers (vimentin and SMA) and carbohydrate expression in connective tissue around neoplasic cells using lectin histochemistry (20). In this context, the saccharide profile can be used as extra information for the characterization of stroma in the MEC.

As observed in other malignant tumours, lectin histochemistry is able to characterize cell biology with a specificity as high as antibody-antigen recognition. Such specificity is corroborated by the abolishment of lectin-carbohydrate binding, which is as precise as that observed in immunohistochemistry. Data presented here indicate that lectins give useful information in distinguishing and/or characterizing cell biology among histological grades of MEC.

Acknowledgments

This work was financially supported by CNPq, CAPES and FACEPE.

References

1. Nangia-Makker P, Conklin J, Hogan V, Raz A (2002) Carbohydrate-binding proteins in cancer, and their ligands as therapeutic agents. Trends Mol Med 8, 187-192.
2. Suwiwat S, Ricciardelli C, Tammi R, Tammi M, Auvinen P, Kosma VM, LeBaron RG, Raymond WA, Tilley WD, Horsfall DJ (2004) Expression of

extracellular matrix components versican, chondroitin sulfate, tenascin, and hyaluronan, and their association with disease outcome in node-negative breast cancer. Clin Cancer Res 10, 2491-2498.
3. Kennedy JF, Palva PMG, Corella MTS, Cavalcanti MSM, Coelho LCBB (1995) Lectins, versatile proteins of recognition: a review. Carbohydr Polym 26, 219-230.
4. Sharon N, Lis H (1993) Carbohydrates in cell recognition. Sci Am 268, 82-89.
5. Campos LM, Cavalcanti CL, Lima-Filho JL, Carvalho LB, Beltrão EI (2006) Acridinium ester conjugated to lectin as chemiluminescent histochemistry marker. Biomarkers 11, 480-484.
6. Korourian S, Siegel E, Kieber-Emmons T, Monzavi-Karbassi B (2008) Expression analysis of carbohydrate antigens in ductal carcinoma in situ of the breast by lectin histochemistry. BMC cancer 8, 136.
7. Beltrão EI, Medeiros PL, Rodrigues OG, Figueredo-Silva J, Valença MM, Coelho LC, Carvalho LB Jr (2003) Parkia pendula lectin histochemistry marker for meningothelial tumour. Eur J Histochem 47, 139-142.
8. Pillai KR, Remani P, Kannan S, Sujathan K, Matthew B, Vijayakumar T, Nair MK, Menon VP (1996) Lectin histochemistry of oral premalignant and malignant lesions: correlation of JFL and PNA binding pattern with tumour progression. Eur J Cancer B Oral Oncol 32B, 32-37.
9. Thöm I, Schult-Kronefelda O, Burkholderb I, Goern M, Andritzky B, Blonski K, Kugler C, Edler L, Bokemeyer C, Schumacher U, Laack E (2007) Lectin histochemistry of metastatic adenocarcinomas of the lung. Lung Cancer 56, 391-397.
10. Gabius HJ (1998) Tumor lectinology: at the intersection of carbohydrate chemistry, biochemistry, cell biology and oncology. Angew Chem Int Ed Eng 27, 1267-1276.
11. Kokemueller H, Brueggemann N, Swennen G, Eckardt A (2005) Mucoepidermoid carcinoma of the salivary glands – clinical review of 42 cases. Oral Oncol 41, 3-10.
12. Goode RK, El-Naggar AK (2005) Mucoepidermoid carcinoma. In: World Health Organization classification of tumours: pathology and genetics of head and neck tumours, Barnes L, Eveson JW, Reichart P, Sidransky D eds, IARC Press, Lyon, 219-220.
13. Barnes L, Eveson JW, Reichart P, Sidransky D (2005) World Health Organization classification of tumours: pathology and genetics of head and neck tumours. IARC Press, Lyon.
14. Hicks J, Flaitz C (2000) Mucoepidermoid carcinoma of salivary glands in children and adolescents: assessment of proliferation markers. Oral Oncol 36, 454-460.
15. Sharon N, Lis H (2004) History of lectins: from hemagglutinins to biological recognition molecules. Glycobiology 14, 53R-62R.
16. Manoharana S, Padmanabhana M, Kolanjiappana K, Ramachandranb CR, Suresha K (2004) Analysis of glycoconjugates in patients with oral squamous cell carcinoma. Clin Chim Acta 339, 91-96.
17. Ono M, Hakomori S (2004) Glycosylation defining cancer cell motility and invasiveness. Glycoconj J 20, 71-78.
18. Shimma Y, Jigami Y (2004) Expression of human glycosyltransferase genes in yeast as a toll for enzimatic synthesis of sugar chain. Glycoconj J 21, 75-78.
19. Becker DJ, Lowe JB (2003) Fucose: biosynthesis and biological function in mammals. Glycobiology 13, 41R-53R.
20. Sobral AP, Loducca SV, Nunes FD, de Araújo NS, Kowaski LP, Araújo VC (2004) Relationship between major and minor salivary gland mucoepidermoid carcinoma malignancy grading and presence of stromal myofibrobasts: immunohistochemical study. J Oral Pathol Med 33, 335-339.
21. Sobral AP, Loducca SV, Kowalski LP, Santos IR, Almeida OP, Araújo NS, Araújo VC (2002) Immunohistochemical distinction of high-grade mucoepidermoid carcinoma and epidermoid carcinoma of the parotid region. Oral Oncol 38, 437-440.