

Application of subepithelial connective tissue graft with or without enamel matrix derivative for root coverage: a split-mouth randomized study

Paulo S. G. Henriques¹⁾, André A. Pelegrine¹⁾, Ana A. Nogueira²⁾
and Mônica M. Borghi²⁾

¹⁾Department of Periodontology, Faculty of Dentistry, São Leopoldo Mandic Dental Research Center, Campinas, SP, Brazil

²⁾Department of Periodontology, São Leopoldo Mandic Dental Research Center, Campinas, SP, Brazil

(Received 24 March and accepted 16 July 2010)

Abstract: The primary aim of this randomized clinical investigation was to evaluate gingival recession defects treated by a coronally advanced flap and subepithelial connective tissue graft (SCTG) with or without enamel matrix derivative (EMD). Twelve patients with Miller's class III buccal recession defects of ≥ 2.0 mm in similar contra lateral sites were included in this split-mouth randomized study. Test sites were treated with SCTG plus EMD while control sites received SCTG only. At baseline, 6 months and 12 months, clinical parameters such as recession level (RL), probing depth (PD), clinical attachment level (CAL), and apico-cervical width of keratinized tissue (KT) were determined. A P value < 0.05 was considered significant. Compared to the baseline and based on paired t tests, both groups had significant improvement in all the clinical parameters. However, the test group showed better results in RL ($P = 0.046$) and CAL ($P = 0.023$) at 6 months. At 12 months, the test group demonstrated better results in RL ($P = 0.01$), PD ($P = 0.017$) and CAL ($P = 0.001$). Only the KT results were not significantly different between groups at both 6 and 12 months ($P = 0.708$) and ($P = 0.570$), respectively. The present study demonstrated the benefit of adding EMD to SCTG for root coverage in Miller's class III buccal

gingival recession defects after 12 months. (J Oral Sci 52, 463-471, 2010)

Keywords: gingival recession; miller's class III recession; connective tissue graft; enamel matrix derivative; periodontal regeneration; case reports.

Introduction

Gingival recession has been defined as the apical displacement of the gingival margin in relation to the cemento-enamel junction (1). Histologically, the collapse of gingival tissue results in attachment loss by destruction of the periodontal connective tissue and alveolar bone. The exposed root surface has been a therapeutic challenge to clinicians for many years. The most frequent etiologic factors associated with recessions are inflammatory periodontal disease, traumatic tooth brushing and inadequate attached gingival dimensions (2-4). Surgical coverage is therefore an aim of mucogingival therapy to improve patients' aesthetics, quality of life and oral health.

Many different surgical procedures have been used to achieve root coverage. Sub-epithelial connective tissue grafting (SCTG) presents a high degree of predictability when used to treat Miller's class I and II gingival recession (5). However, in class III and IV recession defects, the success rate is unpredictable (5,6).

In the last three decades, a number of techniques have been proposed to obtain root coverage: pedicle flaps (PF) (7,8), free soft tissue autografts (FSTA) (9,10), SCTG

Correspondence to Dr. Paulo Sérgio Gomes Henriques, Rua Capitão Francisco de Paula, 346, Cambuí, 13024-450, Campinas, São Paulo, Brazil
Tel: +55-19-32550288
Fax: +55-19-32944815
E-mail: phenriques@mpc.com.br

(11), coronally advanced flaps (CAF) (7,12-14), SCTG plus CAF (15-17) and guided tissue regeneration (GTR) (18-20).

More recently, periodontal regeneration was achieved by using enamel matrix derivative (EMD) (21,22). EMD is an amelogenin derivative obtained from porcine embryogenesis and is capable of inducing regenerative processes in periodontal tissues, due to their fundamental role in cementum development, in a similar way to the normal development of these tissues (23). This regenerative concept has also been demonstrated in root coverage procedures (24). EMD associated with CAF was shown to increase the percentage of root coverage (25).

The aim of this study was to assess the ability of EMD to improve root coverage in Miller's class III gingival recession defects with SCTG (test group), compared to the SCTG alone (control group) for a 6 and 12 months follow-up. The hypothesis being tested in this study was that EMD enhanced the clinical parameters when used with the SCTG.

Materials and Methods

Study population and design

This study employed a split-mouth design, in which 12 systemically healthy non-smoking patients (3 males and 9 females), ranging in age from 35 to 52 years (mean 42.7 ± 5.8), contributed at least two similar contralateral class III gingival recession defects (≥ 2 mm) in upper canines and/or upper premolars (Table 1), with no contraindications for periodontal surgery. Some patients had bilateral single type recession defects and others bilateral similar multiple type recession defects. Periapical radiographs were taken to evaluate the interproximal alveolar bone level to assist in gingival recession classification of teeth exhibiting recession defects. All patients received initial therapy consisting of oral hygiene instructions, scaling and root

planning. Six weeks later, a reevaluation was performed and all the patients recorded an O'Leary index $\leq 10\%$ (26). Each subject was treated on one side with SCTG alone (control group) and the other side with SCTG plus EMD (test group). The side to receive test treatment was determined by coin toss. The patients were provided with comprehensive information concerning the nature and potential risks of surgery involving autogenous gingival grafting with EMD for root coverage. The patients provided consent prior to the initial therapy and were treated between February 2008 and August 2008. The study was conducted in the author's (P.H.) private practice, in accordance with the Helsinki Declaration of 1975, as revised in 2002. The same experienced practitioner (P.H.) performed both operations (at test and control sites) during a single surgical session.

Measurements

The following biometric clinical parameters were evaluated in millimeters mid-facially: recession level (RL), probing depth (PD), clinical attachment level (CAL) and width of the keratinized tissue (KT) using a Marquis periodontal probe (Hu-Friedy Manufacturing Company, Chicago, IL, USA). All the clinical measurements were done by the same calibrated blinded investigator (A.P.) and were rounded down to the nearest millimeter at baseline (immediately before surgery) 6 and 12 months after the surgical intervention, in both treatment groups. Patients were blinded to the test and control sites. Results are presented at the subject level.

Surgical procedure

Preoperative intra-oral antiseptics was accomplished using 0.12% chlorhexidine digluconate solution (Colgate Periogard, São Paulo, SP, Brazil) rinsed for 1 min. Before the surgery, the root surface was gently scaled and planed with Gracey curettes (Hu-Friedy Manufacturing Company), which contributed to reduce buccal prominence. Then, the root surfaces were conditioned with EDTA gel (pH 6.7) (Straumann PrefGel, Straumann, Basel, Switzerland) for 2 min to remove the smear layer. The exposed root surface was rinsed abundantly with sterile saline solution to remove all EDTA residues. After local anesthesia with lidocaine HCl (2%) containing 1:100,000 epinephrine was achieved, the surgery was conducted according to the technique described by Allen and Miller (7) (single recession-type defects) and Zucchelli and de Sanctis (27) (multiple recession-type defects). Two oblique, divergent beveled incisions were performed at the mesial and distal line angles of the tooth (single recession-type defects) or peripheral teeth (multiple recession-type defects) with

Table 1 Demographic and clinical characteristics of patients

Patient no.	Sex	Tooth	Age (years)
1	F	13,14,15/23,24,25	35
2	F	13/23	37
3	F	13/23	38
4	F	13/23	44
5	M	14,15/24,25	39
6	F	14/24	52
7	F	14/24	44
8	M	13/23	45
9	F	15/25	37
10	F	14/24	48
11	F	14/24	42
12	M	15/25	52

gingival recessions and were directed apically in the alveolar mucosa. After intrasulcular incisions, crossed submarginal interproximal incisions created the interdental surgical papillae which were deepithelized. A split-full-split approach was used to elevate the flap. A passive flap coronal mobilization was achieved at the level of the cemento-enamel junction by a sharp dissection accomplished apically.

Test sites procedure

The periosteal subepithelial connective tissue graft was obtained from the palatal area using the single-incision palatal harvest technique reported by Lorenzana and Allen (28). Then, EMD gel (Straumann Emdogain, Straumann) was applied to the root surface and the SCTG was placed over the gel to the height of the cemento-enamel junction, trimmed to extend 2.0 to 3.0 mm beyond the bone crest (both laterally and apically) and fixed with a sling suture using a resorbable suture of polyglactin 910 (Polyglactin 910 Vicryl, Ethicon, Johnson & Johnson Prod. Prof. Ltd) around the crown of the tooth. The flap was coronally positioned 2 mm above the cemento-enamel junction to fully cover the graft by suturing it to the de-epithelialized papilla regions (Fig. 1).

Control sites procedures

The control sites were treated similarly as described previously (including the EDTA gel application) except that EMD gel was not used (Fig. 2).

Post-surgical care

For all subjects, acetaminophen 750 mg (Tylenol, Cilag Farmacêutica Ltd, São Paulo, SP, Brazil) was prescribed four times a day for the first day. The patients were instructed to rinse twice daily with 0.12% chlorhexidine digluconate solution for 4 weeks. The sutures were removed 14 days after surgery. Subjects were advised to discontinue mechanical oral hygiene measures for 4 weeks following surgery to minimize trauma to the surgical sites. Subjects were recalled weekly until they had completed the 6-week period. After the 6-week period, the subjects were monitored once every 2 months until the end of the study at 12 months. During this period, all subjects received professional supra-gingival plaque control and oral hygiene instruction.

Statistical analysis

Twelve subjects were enrolled in a clinical trial comparing treatment of gingival recession defects with SCTG (control group) or with a combination of SCTG and EMD (test group). A split-mouth design was used for this study,

with one side randomized to test and the opposite side to control. The clinical variable changes were compared at baseline, 6 and 12 months after surgery. Descriptive statistics were expressed as mean \pm standard deviation (S.D.). A *t*-test analysis was performed with the subject as the analysis unit. *P* values <0.05 were regarded as statistically significant.

Results

Twelve patients, 3 males and 9 females, aged 35 to 52 years (mean 42.7 ± 5.8), contributed at least two similar class III contralateral gingival recession defects in upper canines and/or upper premolars. In the test group, the recession defects were treated with SCTG+EMD and in the control just SCTG was used, in a split-mouth design. The treated sites consisted of 10 upper canines and 20 upper premolars. Gingival bleeding index and plaque index were kept below 20% throughout the observation period.

At the baseline, no statistically significant differences were found between the two groups in any of the parameters evaluated. Both groups showed a statistically significant result in RL, PD, KT and CAL 6 and 12 months postoperatively, compared to the baseline (intragroup comparison). The test group showed statistically better results than the control group for RL (2.21 ± 0.78 mm and 1.64 ± 1.07 mm, respectively) and CAL changes (2.56 ± 1.37 mm and 1.54 ± 1.16 mm, respectively) at 6 months and for RL (2.54 ± 0.94 mm and 1.72 ± 1.05 mm, respectively), PD (0.46 ± 1.03 mm and 0.49 ± 1.15 mm, respectively) and CAL (3.00 ± 1.21 mm and 1.23 ± 0.99 mm, respectively) at 12 months (intergroup comparison). The mean root coverage in percentage at 12 months postoperatively was 70% in the test group and 54.8% in the control group. There was no statistically significant difference in KT changes between the groups for both evaluation periods and for PD changes in the 6-month postoperative evaluation. Table 2 presents descriptive statistics for the clinical parameters at baseline, after 6 months and after 12 months, for both groups.

Discussion

The primary goal of root coverage techniques is to reestablish aesthetics as well as function by successful coverage of exposed root surfaces and, if possible, regeneration of periodontal supporting tissue. EMD contains a bone sialoprotein-like molecule that binds to the human periodontal ligament cell (29), inducing endogenous production of growth factors that promotes periodontal regeneration (30,31). EMD has been suggested to be effective in improving the clinical attachment level in gingival recession defects (32).

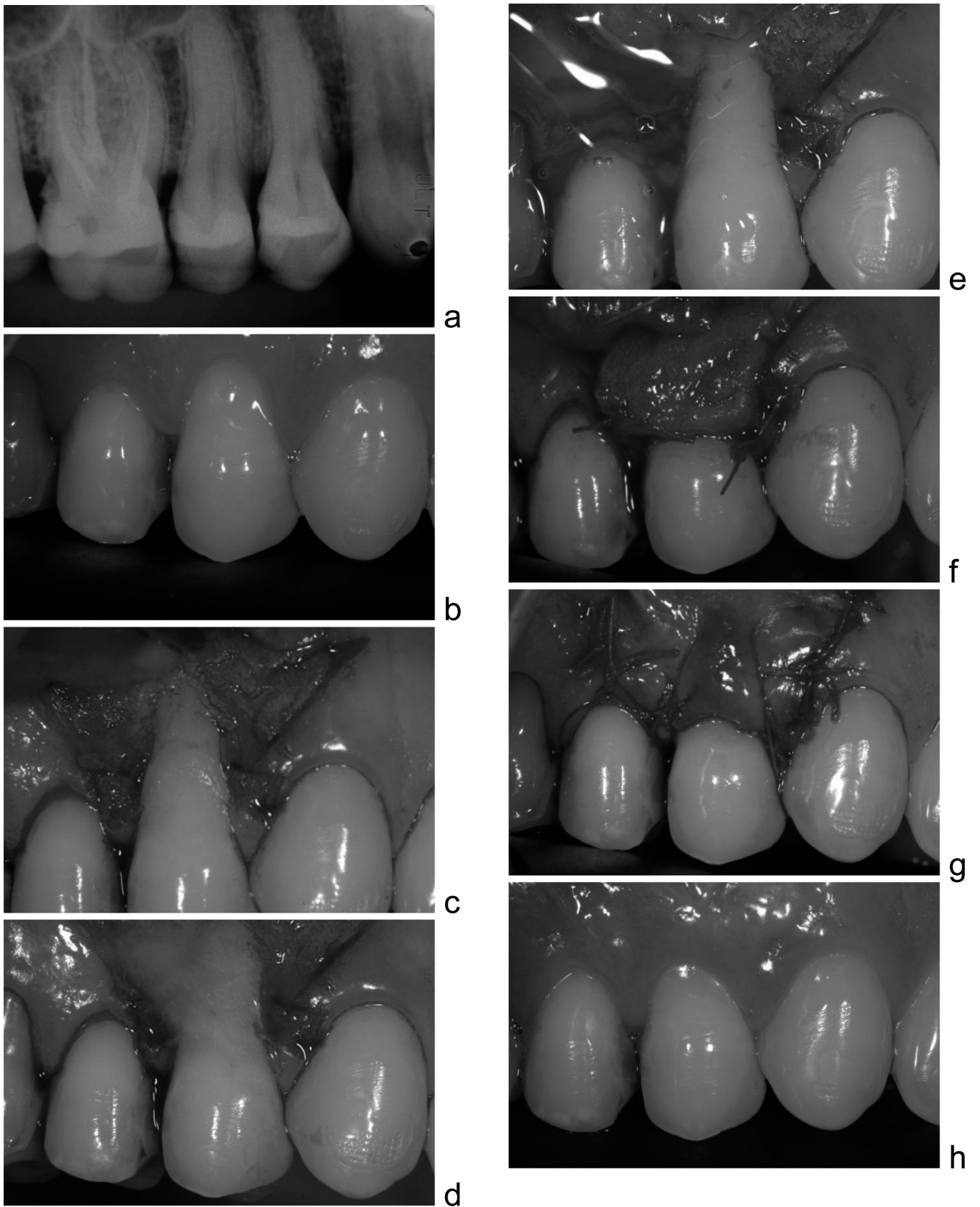


Fig. 1 Test group.

a: Radiographic aspect, b: Baseline view, c: Recipient site, d: EDTA application, e: EMD application, f: SCTG positioned, g: Flap held in a coronal position by suspended sutures, h: 12 months postoperatively

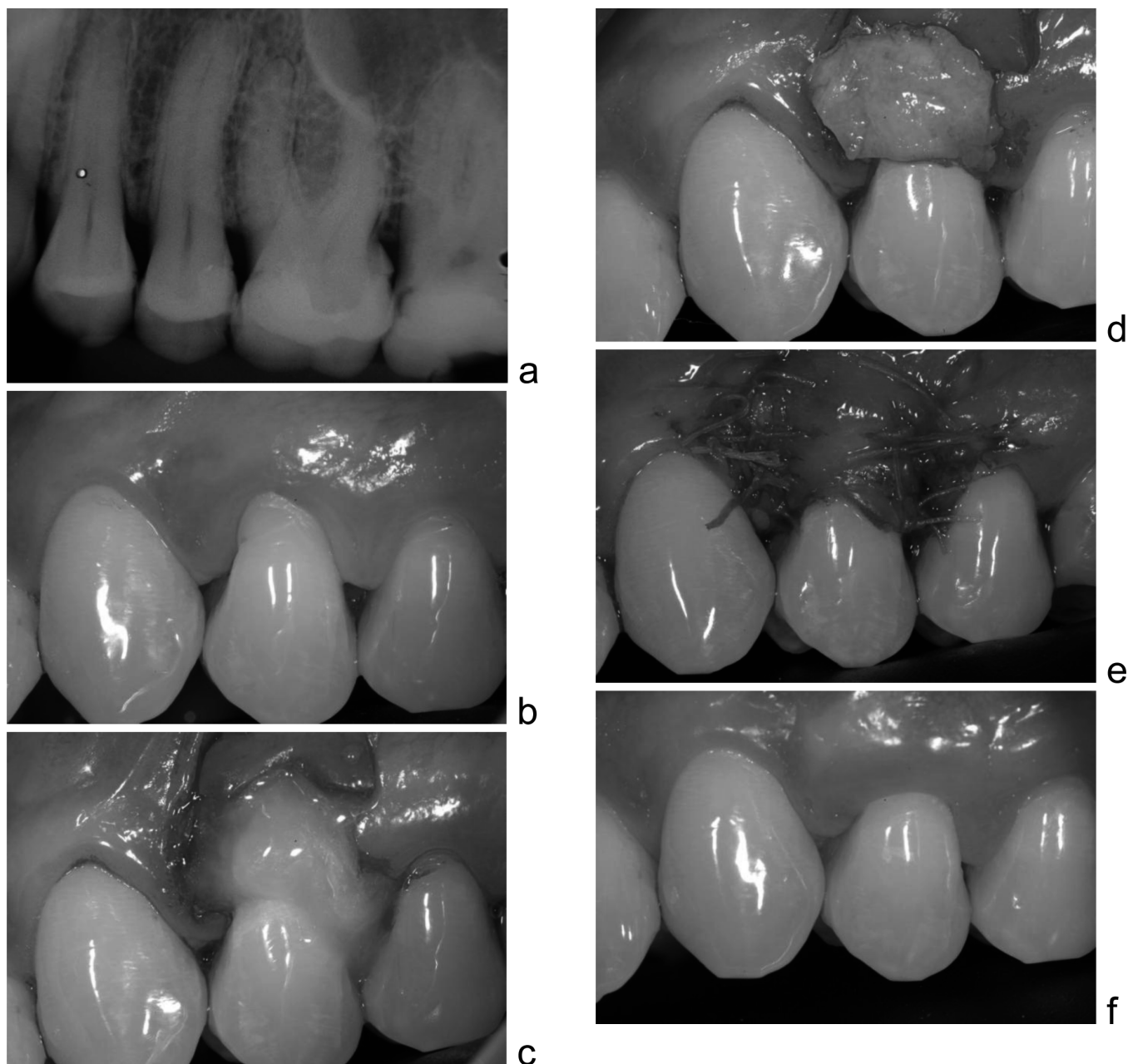


Fig. 2 Control group.

a: Radiographic aspect, b: Baseline view, c: EDTA application, d: SCTG positioned, e: Flap held in a coronal position by suspended sutures, f: 12 months postoperatively

Miller's class I and II recession defects have a predictable outcome after coverage (33). However, in class III recessions, the success rate is not the same (5,6). The primary aim of the present study was to obtain more predictable results in this recession type. A case report, which examined the use of EMD in combination with SCTG in Miller's class III recession defects, suggested good clinical effectiveness in providing root coverage (34). However, Aroca et al. (35) in a 12-month randomized

clinical trial, showed that the association of EMD and SCTG in Miller's class III multiple gingival recession defects does not enhance the mean clinical outcomes.

In this 6- to 12-month randomized, split-mouth clinical study comparing coverage of class III gingival recession defects treated by SCTG (control group) or SCTG+EMD (test group), statistically significant differences were found between the two treatments. The test group showed statistically better results in RL and CAL after 6 months

Table 2 Descriptive statistics of clinical parameters at baseline and after 6 and 12 months for control and test groups

		Control	Test	
		Mean ± SD	Mean ± SD	<i>P</i>
RL	Baseline	3.14 ± 1.12 A	3.63 ± 1.26 A	0.229
	6 months	1.50 ± 1.31 A	1.42 ± 1.16 A	0.754
	1 year	1.42 ± 1.16 A	1.08 ± 1.08 A	0.305
	RL change over 6 months	1.64 ± 1.07 B	2.21 ± 0.78 A	0.046
	RL change over 1 year	1.72 ± 1.05 B	2.54 ± 0.94 A	0.010
PD	Baseline	1.72 ± 0.62 A	2.00 ± 0.74 A	0.166
	6 months	1.82 ± 0.76 A	1.65 ± 0.26 A	0.504
	1 year	2.21 ± 0.89 A	1.54 ± 0.66 B	0.005
	PD change over 6 months	-0.10 ± 0.87 A	0.35 ± 1.21A	0.180
	PD change over 1 year	-0.49 ± 1.15 B	0.46 ± 1.03 A	0.017
KT	Baseline	3.21 ± 1.37 A	2.99 ± 1.45 A	0.303
	6 months	3.83 ± 0.94 A	3.75 ± 1.14 A	0.674
	1 year	3.82 ± 0.67 A	3.81 ± 1.06 A	0.953
	KT change over 6 months	-0.62 ± 1.11A	-0.76 ± 0.99 A	0.708
	KT change over 1 year	-0.61 ± 1.35 A	-0.82 ± 1.31 A	0.570
CAL	Baseline	4.86 ± 0.92 A	5.63 ± 1.23 A	0.079
	6 months	3.32 ± 1.69 A	3.07 ± 1.73 A	0.515
	1 year	3.63 ± 1.52 A	2.63 ± 1.55 B	0.007
	CAL change over 6 months	1.54 ± 1.16 B	2.56 ± 1.37 A	0.023
	CAL change over 1 year	1.23 ± 0.99 B	3.00 ± 1.21 A	0.001

Different letters, in lines, indicate difference significance between them (*t*-test, *P* < 0.05).

and in RL, PD and CAL after 12 months. This suggests that the EMD, when used in association with SCTG, can improve the clinical outcome in Miller's class III recession defects. It might be explained by the EMD's potential to induce periodontal regeneration. Moses et al. (36) showed better root coverage with EMD associated to CAF after 24 months when compared to 12 months, suggesting that a creeping attachment had occurred. The better outcome of the regeneration process within time after the usage of EMD has been demonstrated by other studies (33,36,37).

The statistically better results obtained in the test group (EMD+SCTG) of our study were not confirmed by the results of the test group (EMD+SCTG) of Aroca et al. (35). There were methodological differences between the studies, especially in the demographic data and surgical technique. The surgical technique employed by Aroca et al. (35) did not have vertical releasing incisions like in this study and involved papilla reconstruction, which was not performed in our study. According to Zucchelli et al. (38), the lack of vertical releasing incisions reflects in better clinical outcomes, which could explain the higher level of root coverage obtained in the Aroca (35) study, where a modified tunnel/SCTG technique was used. The tunnel/SCTG

technique allows papilla reconstruction, which can optimize root coverage results. Furthermore, Aroca et al. (35) harvested a dense connective tissue from the tuberosity using a distal wedge technique, while our study was performed with a palatal graft using the single-incision palatal harvest technique reported by Lorenzana and Allen (28). All these relevant aspects could explain the difference in the mean root coverage obtained between the studies: 70% in the test group and 54.8% in the control group of our study versus 82% in the test group and 83% in the control group of their study.

Previous preliminary studies have shown that EMD has the potential of inducing periodontal regeneration (21-24,39). On the other hand, the gold standard root coverage technique (SCTG), despite having good clinical acceptance due to its favorable clinical outcome, does not predictably promote periodontal tissue regeneration (40). Modica et al. (37) showed a higher success rate for root coverage with the coronally positioned flap (CPF) plus EMD, but without statistically significant results when compared to the CPF used alone. The absence of statistical significance in the abovementioned study (37), in opposition with our study, might be correlated to the difference in defect type enrolled

in the studies (class I vs. class III) or the use of the SCTG in the present study. Miller's class III recessions are more unpredictable defects, thus probably needing more complicated therapy. In addition, the use of SCTG may improve the outcome of the coverage therapy, particularly when combined with EMD as in the present study. The periosteal connective tissue might include osteogenic substances in the periosteum that could be stimulated by the EMD, which is believed to enhance the proliferation, differentiation, and migration of osteoblasts and periodontal ligament cells (39,41,42). Therefore, the association of the SCTG and EMD in very complicated gingival recession defects, i.e., Miller's class III gingival recession, seems to promote an additional benefit probably by combining clinical root coverage and periodontal tissue regeneration.

There were no statistically significant differences between the two groups in KT, both after 6 and after 12 months. Despite the fact that Modica et al. (37) and Cueva et al. (33) have shown KT gain when using EMD associated to the coronally advanced flap (CAF) in root coverage therapies, the present study failed to demonstrate additional KT gain when the EMD was used in combination with SCTG. This probably occurred because the SCTG may have been responsible for the majority of the KT gain, but further studies are necessary to provide the answer. On the contrary, Aroca et al. (35) observed that there was no significant KT increase after the SCTG and after SCTG+EMD technique.

On intragroup comparison, it was shown that all clinical parameters improved after both therapies. Therefore, despite the additional clinical benefit of using EMD combined with the SCTG in Miller's class III gingival recession defects, the use of SCTG alone may be continued.

The thin gingival phenotype could be a factor in increasing the risk of gingival recession (43,35). The SCTG increases marginal tissue thickness (38) which may prevent further recession in patients with a thin periodontal phenotype, especially in regenerated periodontal tissues by the use of EMD. Since the therapies in Miller's class III gingival recessions are considered unpredictable, researchers should direct their efforts to develop more predictable techniques for successful root coverage in these critical defects.

The results of this study indicate that the use of EMD is beneficial in augmenting the effects of the SCTG in terms of amount of root coverage, gain in clinical attachment and reducing the probing depth in Miller's class III gingival recession defects.

References

1. American Academy of Periodontology (2001)

- Glossary of periodontal terms. 4th ed, American Academy of Periodontology, Chicago, 44.
2. Wennström JL (1996) Mucogingival therapy. *Ann Periodontol* 1, 671-701.
 3. Trombelli L (1999) Periodontal regeneration in gingival recession defects. *Periodontol* 2000 19, 138-150.
 4. Maynard JG (1987) The rationale for mucogingival therapy in the child and adolescent. *Int J Periodontics Restorative Dent* 7, 36-51.
 5. Miller PD Jr (1985) A classification of marginal tissue recession. *Int J Periodontics Restorative Dent* 5, 8-13.
 6. Wennström JL, Pini-Prato GP (1997) Mucogingival therapy. In: *Clinical periodontology and implant dentistry*, Lindhe J, Karring T, Niklaus P, Lang NP eds, Munksgaard, Copenhagen, 569-571.
 7. Allen EP, Miller PD Jr (1989) Coronal positioning of existing gingiva: short term results in the treatment of shallow marginal tissue recession. *J Periodontol* 60, 316-319.
 8. Harris RJ, Harris AW (1994) The coronally positioned pedicle graft with inlaid margins: a predictable method of obtaining root coverage of shallow defects. *Int J Periodontics Restorative Dent* 14, 228-241.
 9. Miller PD Jr (1982) Root coverage using a free soft tissue autograft following citric acid application. Part 1: technique. *Int J Periodontics Restorative Dent* 2, 65-70.
 10. Holbrook T, Ochsenbein C (1983) Complete coverage of the denuded root surface with a one-stage gingival graft. *Int J Periodontics Restorative Dent* 3, 8-27.
 11. Langer B, Langer L (1985) Subepithelial connective tissue graft technique for root coverage. *J Periodontol* 56, 715-720.
 12. Tarnow DP (1986) Semilunar coronally repositioned flap. *J Clin Periodontol* 13, 182-185.
 13. Pini-Prato G, Baldi C, Pagliaro U, Nieri M, Saletta D, Rotundo R, Cortellini P (1999) Coronally advanced flap procedure for root coverage. Treatment of root surface: root planning versus polishing. *J Periodontol* 70, 1064-1076.
 14. de Sanctis M, Zucchelli G (2007) Coronally advanced flap: a modified surgical approach for isolated recession-type defects: three-year results. *J Clin Periodontol* 34, 262-268.
 15. Nelson SW (1987) The subpedicle connective tissue graft. A bilaminar reconstructive procedure for the coverage of denuded root surfaces. *J Periodontol* 58,

- 95-102.
16. Maynard JG Jr (1977) Coronal positioning of a previously placed autogenous gingival graft. *J Periodontol* 48, 151-155.
 17. Bernimoulin J, Lüscher B, Mühlemann HR (1975) Coronally repositioned periodontal flap. Clinical evaluation after one year. *J Clin Periodontol* 2, 1-13.
 18. Tinti C, Vincenzi GP, Cortellini P, Pini-Prato G, Clauser C (1992) Guided tissue regeneration in the treatment of human facial recession. A 12-case report. *J Periodontol* 63, 554-560.
 19. Pini-Prato G, Clauser C, Magnani C, Cortellini P (1995) Resorbable membrane in the treatment of human buccal recession: a nine-case report. *Int J Periodontics Restorative Dent* 15, 258-267.
 20. Rocuzzo M, Lungo M, Corrente G, Gandolfo S (1996) Comparative study of a bioresorbable and a non-resorbable membrane in the treatment of human buccal gingival recessions. *J Periodontol* 67, 7-14.
 21. Heijl L (1997) Periodontal regeneration with enamel matrix derivative in one human experimental defect. A case report. *J Clin Periodontol* 24, 693-696.
 22. Sculean A, Chiantella GC, Windisch P, Donos N (2000) Clinical and histologic evaluation of human intrabony defects treated with an enamel matrix protein derivative (Emdogain). *Int J Periodontics Restorative Dent* 20, 374-381.
 23. Hammarström L (1997) Enamel matrix, cementum development and regeneration. *J Clin Periodontol* 24, 658-668.
 24. Carnio J, Camargo PM, Kenndy EB, Schenk RK (2002) Histological evaluation of 4 cases of root coverage following a connective tissue graft combined with an enamel matrix derivative preparation. *J Periodontol* 73, 1534-1543.
 25. Spahr A, Haegewald S, Tsoulfidou F, Rompola E, Heijl L, Bernimoulin JP, Ring C, Sander S, Haller B (2005) Coverage of Miller class I and II recession defects using enamel matrix proteins versus coronally advanced flap technique: a 2-year report. *J Periodontol* 76, 1871-1880.
 26. O'Leary TJ, Drake RB, Naylor JE (1972) The plaque control record. *J Periodontol* 43, 38.
 27. Zucchelli G, de Sanctis M (2000) Treatment of multiple recession-type defects in patients with esthetic demands. *J Periodontol* 71, 1506-1514.
 28. Lorenzana ER, Allen EP (2000) The single-incision palatal harvest technique: a strategy for esthetics and patient comfort. *Int J Periodontics Restorative Dent* 20, 297-305.
 29. Suzuki N, Ohyama M, Maeno M, Ito K, Otsuka K (2001) Attachment of human periodontal ligament cells to enamel matrix-derived protein is mediated via interaction between BSP-like molecules and integrin $\alpha v \beta 3$. *J Periodontol* 72, 1520-1526.
 30. Suzuki S, Nagano T, Yamakoshi Y, Gomi K, Arai T, Fukae M, Katagiri T, Oida S (2005) Enamel matrix derivative gel stimulates signal transduction of BMP and TGF- β . *J Dent Res* 84, 510-514.
 31. Heng NHM, N'Guessan PD, Kleber BM, Bernimoulin JP, Pischon N (2007) Enamel matrix derivative induces connective tissue growth factor expression in human osteoblastic cells. *J Periodontol* 78, 2369-2379.
 32. Pilloni A, Paolantonio M, Camargo PM (2006) Root coverage with a coronally positioned flap used in combination with enamel matrix derivative: 18-month clinical evaluation. *J Periodontol* 77, 2031-2039.
 33. Cueva MA, Boltchi FE, Hallmon WW, Nunn ME, Rivera-Hidalgo F, Rees T (2004) A comparative study of coronally advanced flaps with and without the addition of enamel matrix derivative in the treatment of marginal tissue recession. *J Periodontol* 75, 949-956.
 34. Sato S, Yamada K, Kato T, Haryu K, Ito K (2006) Treatment of Miller Class III recessions with enamel matrix derivative (Emdogain) in combination with subepithelial connective tissue grafting. *Int J Periodontics Restorative Dent* 26, 71-77.
 35. Aroca S, Keglevich T, Nikolidakis D, Gera I, Nagy K, Azzi R, Etienne D (2010) Treatment of class III multiple gingival recessions: a randomized-clinical trial. *J Clin Periodontol* 37, 88-97.
 36. Moses O, Artzi Z, Sculean A, Tal H, Kozlovsky A, Romanos GE, Nemcovsky CE (2006) Comparative study of two root coverage procedures: a 24-month follow-up multicenter study. *J Periodontol* 77, 195-202.
 37. Modica F, Del Pizzo M, Rocuzzo M, Romagnoli R (2000) Coronally advanced flap for the treatment of buccal gingival recession with and without enamel matrix derivative. A split-mouth study. *J Periodontol* 71, 1693-1698.
 38. Zucchelli G, Mele M, Mazzotti C, Marzadori M, Montebugnoli L, De Sanctis M (2009) Coronally advanced flap with and without vertical releasing incisions for the treatment of multiple gingival recessions: a comparative controlled randomized clinical trial. *J Periodontol* 80, 1083-1094.
 39. Hammarström L, Heijl L, Gestrelus S (1997)

- Periodontal regeneration in a buccal dehiscence model in monkeys after application of enamel matrix proteins. *J Clin Periodontol* 24, 669-677.
40. Bruno JF, Bowers GM (2000) Histology of a human biopsy section following the placement of a subepithelial connective tissue graft. *Int J Periodontics Resorative Dent* 20, 225-231.
 41. Müller HP, Eger T (1997) Gingival phenotypes in young male adults. *J Clin Periodontol* 24, 65-71.
 42. Müller HP, Eger T, Schorb A (1998) Gingival dimensions after root coverage with free connective tissue grafts. *J Clin Periodontol* 25, 424-430.
 43. Cummings LC, Kaldahl WB, Allen EP (2005) Histologic evaluation of autogenous connective tissue and acellular dermal matrix grafts in humans. *J Periodontol* 76,178-186.