

## Angiofibrolipoma of the buccal mucosa: a case report

Amila Brkić<sup>1)</sup>, Çiğdem Özçamur<sup>1)</sup>, Banu Gürkan-Köseoğlu<sup>1)</sup> and Vakur Olgac<sup>2)</sup>

<sup>1)</sup>Department of Oral Surgery, Faculty of Dentistry, Istanbul University, Çapa, Istanbul, Turkey

<sup>2)</sup>Institute of Oncology, Medical Faculty, Istanbul University, Çapa, Istanbul, Turkey

(Received 29 June and accepted 2 December 2009)

**Abstract:** Angiofibrolipoma is a rare histopathological variant of lipoma, characterized by mature adipocytes, blood vessels and dense collagenous tissue. It is seldom seen in the oral and maxillofacial region. Clinically, as it shares macroscopic similarity with lipoma and fibroma, the diagnosis of angiofibrolipoma is only possible based on its histopathological features. The aim of this report is to present an unusual case of a 59-year-old female patient, who reported a pathological soft mass in the buccal mucosa of the left cheek which was present for 20 years. After excisional biopsy and histopathological evaluation of the sample, the diagnosis of angiofibrolipoma was made. (J Oral Sci 52, 173-176, 2010)

Keywords: lipoma; angiofibrolipoma; buccal mucosa; differential diagnosis.

### Introduction

Lipoma presents a benign mesenchymal tumor composed of mature adipocytes (1-3). It is well separated from surrounding tissues by a thin fibrous capsule (1,4). The most common localization of lipoma is just below the surface of the skin, although it may be found anywhere in the body where adipose tissue is located. Approximately 13% of all lipomas occur in the head and neck region (1). Oral lipomas comprise 0.5-5% of all benign lesions in the oral cavity, with occurrence in major salivary glands, buccal mucosa, lip, tongue, palate, vestibule and floor of the mouth (2,3).

Correspondence to Dr. Amila Brkić, İstanbul Üniversitesi, Diş hekimliği fakültesi, Ağız Diş Çene Hastalıkları ve Cerrahisi A. B. D. 34 093 Çapa İstanbul, Türkiye  
Tel: +90-555-563-91-80  
Fax: +90-212-574-24-05  
E-mail: amilabrkić@hotmail.com

Clinically, oral lipomas are slow-growing tumors in the form of well-circumscribed, mobile, painless, submucosal, sometimes fluctuant yellowish-colored nodules. They are lesions of the middle age, mostly seen in patients older than 40 years (3,4). According to their characteristic clinical and histopathologic features, lipomas are classified into different subtypes, which are important for differential diagnosis and therapeutic approach. The WHO classification of adipocytic tumors distinguishes lipomas based on their clinical and histopathological features into classic lipoma, angiolipoma, chondroid lipoma, and myolipoma spindle cell/pleomorphic lipoma (5). According to another author, histological variants of lipomas include fibrolipomas, angiolipomas, angiofibrolipomas, angio-myolipomas, and infiltrating angiolipomas (6,7). These classifications are based on the relationship between the fat, muscle, blood vessel, and connective tissues involved in the tumor structure. In this way, angiofibrolipomas are a mixture of mature adipocytes, vascular tissue and collagenous connective tissue (6,7). This report presents a rare case of oral angiofibrolipoma in a 59-year-old female.

### Case Report

In November 2008, a 59-year-old female was referred to our department with the complaint of a polyp-like mass, felt from the oral side of the left cheek. From the past history, it was found that the mass, which was present for 20 years as a small prominent area of the mucosa, started to "grow" 3 years before the patient was referred to us. At the same time, it was reported that the mass might have developed as a consequence of traumatic bites while wearing a prosthesis made 20 years ago.

Intraoral examination revealed a polypoid mass, 12 mm in diameter, located on the left side buccal mucosa along the occlusal planes of the upper and lower molars. The color of the covering mucosa was same as the normal surrounding

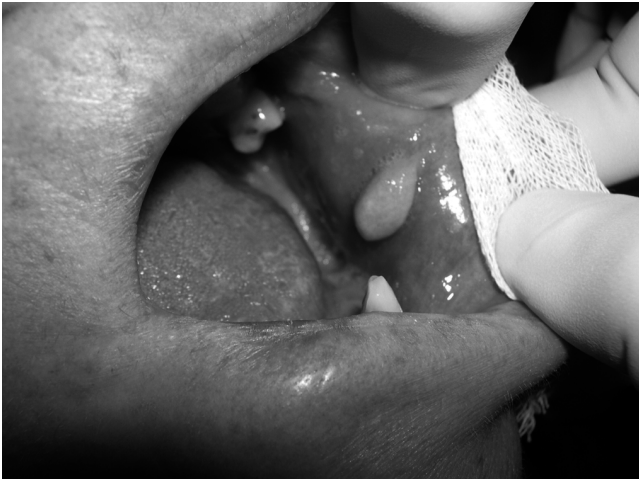

Fig. 1 Clinical appearance of the pathological mass on the left buccal mucosa. The lesion had been present for 20 years.

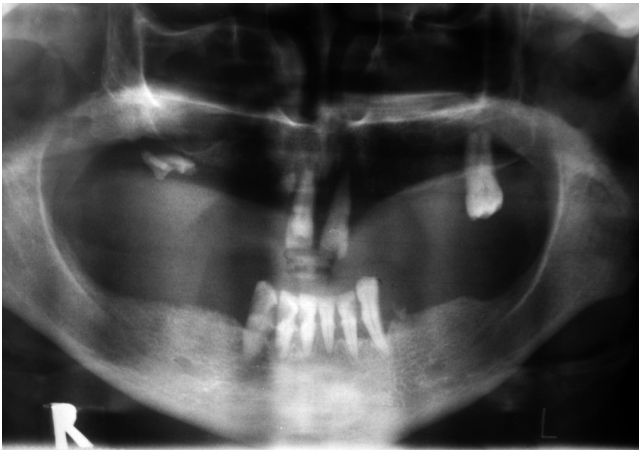


Fig. 2 Panoramic radiograph did not show any pathological features in the jaw.

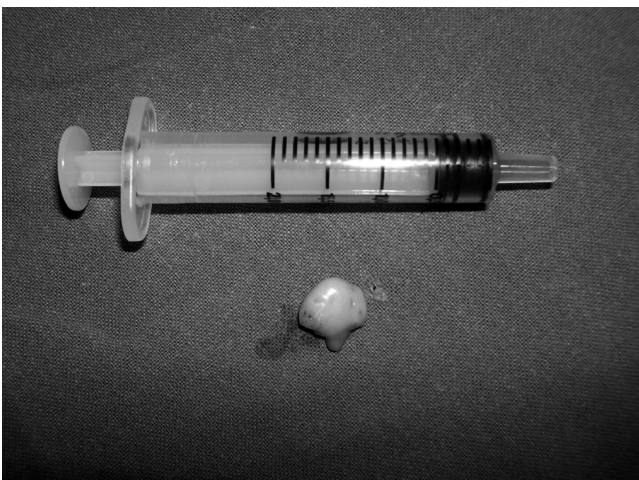

Fig. 3 Pathological specimen after excisional biopsy.

mucosa, with no signs of ulceration or infection. The mass was well demarcated from the surrounding area, mobile but non-pedunculated, soft in consistency, elastic, fluctuant and non-tender (Fig. 1). Extraoral examination revealed no asymmetry or lymphadenopathy. Panoramic radiograph did not show the presence of any pathological change of the jaw structures (Fig. 2). Under local anesthesia, an excisional biopsy of pathological mass in the left buccal mucosa, by conventional scalpel surgery, was performed (Fig. 3). The wound was covered with an iodine bandage. The surgical specimen was fixed in 10% buffered formalin and submitted for histopathological evaluation, with a provisional clinical diagnosis of lipoma. Seven days after surgery, the patient came for review. Healing of the wound was uneventful.

Histopathological examination revealed numerous vascular channels, surrounded by collagen rich fibrous tissue and mature adipocytes. The cells of fibrous tissue were histologically normal and spindle-shaped without mitotic activities, although hyperchromatism was noted in their nucleoli. Collagen fibers were arranged in a parallel fashion with mature fat entrapped within the lesion (Figs. 4A and 4B). The histopathological diagnosis of the lesion was angiofibrolipoma.

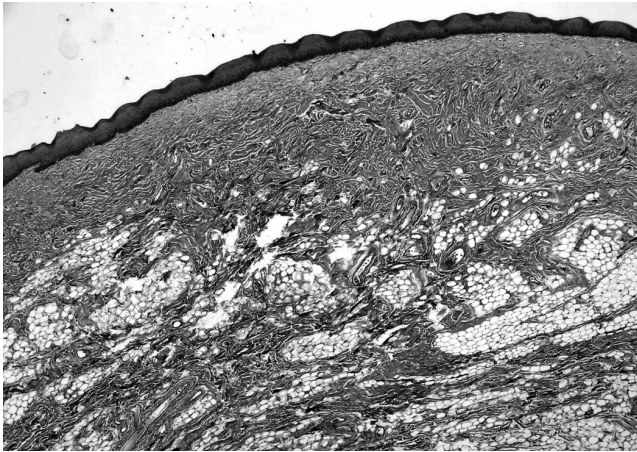
The patient has been under regular follow-up for the past 9 months and has no complaints or complications.

## Discussion

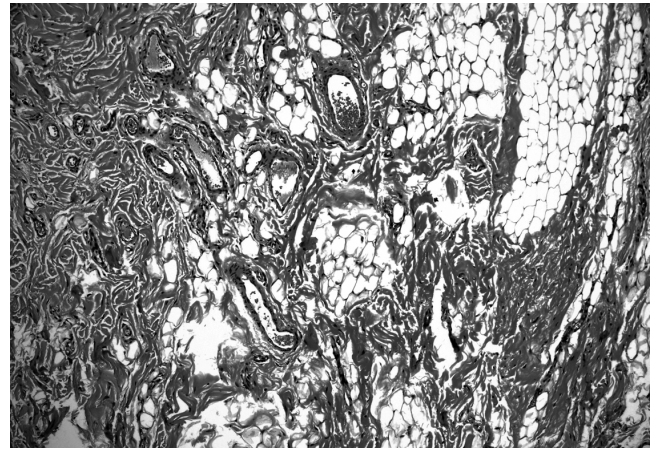The etiology of lipoma is still unknown. It is believed that diabetes mellitus induced by hypercholesterolemia and obesity, radiation, and a familial or genetic link, such as abnormality of chromosome 12, may be involved in lipoma development (8,9). However, in the literature, trauma is also mentioned as one of the etiological factors (8,10,11). There are two different opinions about the occurrence of so-called “traumatic lipomas”. The first is that, after trauma, adipose tissue prolapses through fascia, resulting in a direct impaction. The second opinion is that, after soft tissue trauma and hematoma formation, cytokines mediate differentiation and proliferation of preadipocytes, resulting in lipoma formation (10). In this case, there was reported presence of trauma of the oral mucosa after the patient started to use a prosthesis 20 years earlier. This anamnestic finding also supports the theory of slow growth of lipomas, which developed over several years (1,4). In our case, it took 20 years.

An important characteristic of oral lipomas is their small size with a diameter of 1-3 cm. In this case, the nodule was 1.2 cm in diameter and was reported in a female patient, which is uncommon if we consider the gender prevalence for men (2,3).





A



B

Fig. 4A, B Histopathological features of angiofibrolipoma (hematoxylin-eosin staining), show matured adipose tissue intermixed with dilated vascular elements and collagen-rich fibrous tissue.

One of the rarest seen histopathological variants of lipoma is angiofibrolipoma. This neoplasm is composed of fibroblasts, capillaries, and adipose tissue. It is not encapsulated, but is well separated from neighboring tissues (6,7). In the literature, there are few reports of angiofibrolipoma associated with the oral and maxillofacial region. Saddik et al. reported a case of liposarcoma of the base of the tongue and tonsillar fossa in a patient who underwent several resections of the mass, which was once diagnosed as angiofibrolipoma (12). A report by Jacob et al. described a case of ear canal angiofibrolipoma (7). We believe this is the first reported case of oral angiofibrolipoma located on the buccal mucosa in a female patient. Histopathological analysis of the surgical specimen taken from the buccal mucosa revealed numerous vascular channels surrounded by collagen rich fibrous tissue and mature adipocytes, which was diagnosed as angiofibrolipoma.

Differential diagnosis of lipoma might include some benign connective tissue lesions, such as granular cell tumour, neurofibroma, traumatic fibroma and salivary gland lesions (mucocele and mixed tumor) (4).

The treatment option for lipomas, as for all its histological variants, is surgical excision, after which long-term follow up is recommended to avoid recurrence (1,7,13). Generally, recurrences are very rare. The exception is for infiltrating angiolipomas, which have a recurrence rate of 35-50% (1,13). Our patient reported 9 months postoperatively without any complaints and no signs of recurrence.

## References

1. Auo HJ, Kang JM (2009) Infiltrating angiolipoma

- of the nasopharynx: adjacent to an aberrant internal carotid artery. *Auris Nasus Larynx* 36, 247-250.
2. Furlong MA, Fanburg-Smith JC, Childers EL (2004) Lipoma of the oral and maxillofacial region: site and subclassification of 125 cases. *Oral Surg Oral Med Oral Pathol Oral Radiol Endod* 98, 441-450.
3. Bandéca MC, de Pádua JM, Nadalin MR, Ozório JE, Silva-Sousa YT, da Cruz Perez DE (2007) Oral soft tissue lipomas: a case series. *J Can Dent Assoc* 73, 431-434.
4. Regezi JA, Sciubba J (1993) *Oral pathology: clinical-pathologic correlations*. 2nd ed, WB Saunders, Philadelphia, 235-237.
5. Fletcher CDM, Krishnan Unni K, Mertens F (2002) *World Health Organization classification of tumours: pathology and genetics tumours of soft tissue and bone*. IARC Press, Lyon, 9-46.
6. Liggett AD, Frazier KS, Styer EL (2002) Angiolipomatous tumors in dogs and a cat. *Vet Pathol* 39, 286-289.
7. Jacob A, Kneile J, Welling B (2005) Angiofibrolipoma of the ear canal. *Laryngoscope* 115, 1461-1462.
8. Enzinger FM, Weiss SW (1995) *Soft tissue tumors*. 3rd ed, Mosby, St Louis, 384-405.
9. Merscher S, Marondel I, Pedeutour F, Gaudray P, Kucherlapati R, Turc-Carel C (1997) Identification of new translocation breakpoints at 12q13 in lipomas. *Genomics* 46, 70-77.
10. Aust MC, Spies M, Kall S, Jokuszies A, Gohritz A, Vogt P (2007) Posttraumatic lipoma: fact or fiction? *Skinmed* 6, 266-270.

11. Signorini M, Campiglio GL (1998) Posttraumatic lipomas: where do they really come from? *Plast Reconstr Surg* 101, 699-705.
12. Saddik M, Oldring DJ, Mourad WA (1996) Liposarcoma of the base of tongue and tonsillar fossa: a possibly underdiagnosed neoplasm. *Arch Pathol Lab Med* 120, 292-295.
13. Ozer E, Schuller DE (2006) Angiolipoma of the neck. *Otolaryngol Head Neck Surg* 135, 643-644.