

# Treatment of a young adult with Class III malocclusion using a modified mini maxillary protractor: a case report

Zahir Altuğ and Özge U. Akçam

Department of Orthodontics, School of Dentistry, Ankara University, Ankara, Turkey

(Received 29 June and accepted 5 November 2009)

**Abstract:** We describe the treatment of a young adult male (aged 14 years 9 months) with Class III malocclusion using a mini maxillary protraction appliance, and discuss the results. The patient was treated with an acrylic cap splint-type expander and a modified maxillary protractor until a positive overjet was achieved. Edgewise fixed appliances were used to align the teeth. The treatment resulted in Class I molar occlusion, an ideal overjet, overbite and incisor angulation. A Class I molar relationship was achieved after 6 months of treatment, and the total treatment time was 1 year 6 months. Modified maxillary protractor treatment is effective for correcting skeletal Class III malocclusion. (*J Oral Sci* 52, 155-159, 2010)

Keywords: Class III; maxillary protraction appliance.

## Introduction

Class III malocclusions may occur due to prognathism of the mandible, retrognathism of the maxilla, protrusive mandibular dentition, retrusive maxillary dentition, or combinations of these (1-4). For the treatment of Class III maxillary retrusion, the use of reverse headgear has been described (5). This can produce forward movement of the maxilla and posterior rotation of the mandible (6-8). Animal studies have shown that forward movement of the maxilla is a result of remodelling of the circummaxillary sutures (9,10).

Because of its action in maxillary sutures to enhance the

protraction effect of reverse headgear, rapid maxillary expansion is generally used in the treatment of Class III patients (11,12). Proffit and Fields reported that maxillary expansion must be used before maxillary protraction to mobilize the maxillary sutures (13). A mini maxillary protractor was reported a few years ago by Altug and Arslan, who found it effective for the correction of Class III malocclusion (14,15).

Here we present a case report of the treatment outcome of a patient with skeletal Class III who was treated using a modified maxillary protraction appliance.

## Case Report

The case subject was a boy aged 14 years 9 months old who had no craniofacial deformity, temporomandibular joint disorder or facial asymmetry (Fig. 1A). Intra-oral examination revealed Class I molar occlusion on the right side and Class III molar occlusion on the left side, with a -0.5-mm overjet, a 0-mm overbite, 10-mm crowding in the upper arch and 4-mm crowding in the lower arch (Fig. 1B). He was in the MP3u (16) skeletal growth stage, and a hand-wrist film showed him to have completed 99% of his growth. Findings of pre-treatment Steiner cephalometric analysis (17) are presented in Table 1.

Orthodontic treatment objectives included maxillary protraction to obtain a Class I relationship, maxillary expansion, protrusion of the upper incisors to obtain a positive overjet and overbite, and alignment of the teeth. The patient's release form and written consent were obtained beforehand.

## Treatment progress

The mini maxillary protraction appliance consists of four parts (Fig. 1C):

1) A full-coverage acrylic splint-type expander was constructed for the maxillary arch. Hooks were placed in

Correspondence to Dr. Özge Uslu Akçam, Department of Orthodontics, Faculty of Dentistry, Ankara University, Besevler 06500 Ankara, Turkey  
Tel: +90-312-2122708  
Fax: +90-312-2130960  
E-mail: osgeuslu@gmail.com

the premolar region on the buccal sides of the expander. The screw was activated 3 times in one month by the patient.

2) A mandibular plate covering the posterior mandibular dental arch was constructed.

3) Acrylic chincap. A hook was attached to each side of

the acrylic chincap for application of cervical force.

4) Lower face bow: An 051" bow was used to connect the chincap to the mandibular plate. A horizontal bar was added for application of protraction elastics to the hooks of the maxillary expander (Fig. 1C). A 300 g per side protraction force with an anteroinferior force vector 20-30° to the occlusal plane was applied with elastics between the maxillary hooks to the horizontal bar of the mandibular plate. The patient was instructed to use the appliance at least 18 h a day until a positive overjet was achieved (Fig. 2). After the overcorrection with protraction therapy, edgewise fixed appliances were used to align the teeth.

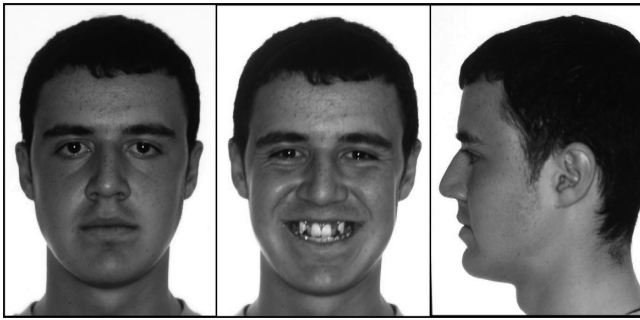


Fig. 1A Pretreatment extraoral photographs.

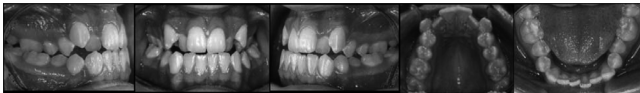

Fig. 1B Pretreatment intraoral photographs.

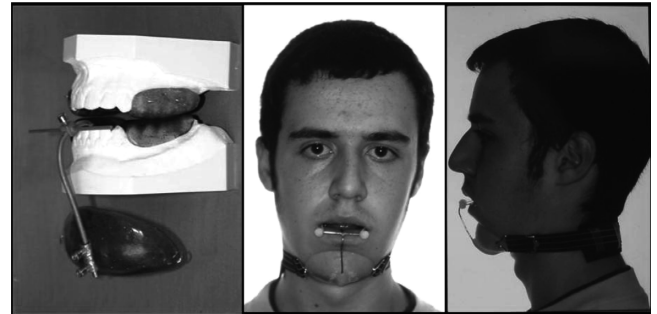

Fig. 1C Mini maxillary protraction appliance applied to the maxillary arch.

Table1 Pretreatment, after protraction and posttreatment cephalometric analysis

|   | Pretreatment      | After protraction | Posttreatment |
|---|-------------------|-------------------|---------------|
| SNA                                     | 77°               | 78°               | 78°           |
| SNB                                     | 78°               | 77°               | 77°           |
| ANB                                     | -1°               | 1°                | 1°            |
| Upper incisor-NA                        | 5 mm / 26.5°      | 6.5 mm / 33°      | 6 mm / 23°    |
| Lower incisor-NB                        | 6 mm / 26°        | 5.5 mm / 22°      | 5.5 mm / 24°  |
| Pg-NB                                   | 5 mm              | 6 mm              | 6.5 mm        |
| Interincisal angle                      | 128°              | 126°              | 130°          |
| OkI-SN                                  | 17.5°             | 16.5°             | 17°           |
| GoGn/SN                                 | 34°               | 36°               | 36°           |
| Steiner's Line to upper lip / lower lip | -3.5 mm / -1.5 mm | -1 mm / 0 mm      | -1 mm / 1 mm  |

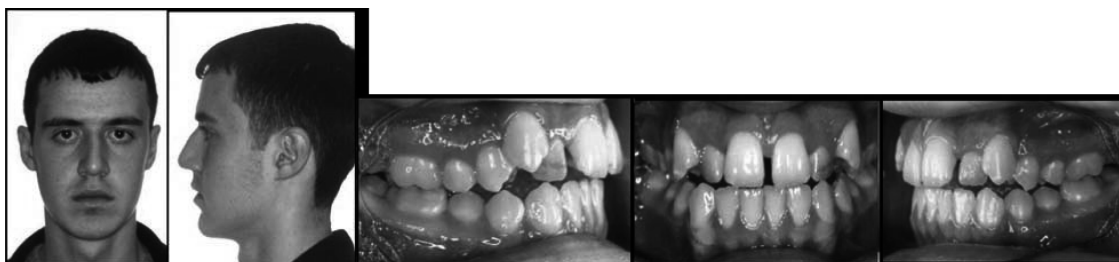


Fig. 2 Post-protraction photographs.

A Class I molar relationship was achieved after 6 months of protraction treatment, and the total treatment time was 1 year 6 months (Figs. 3A, 3B). Hawley plates were utilized for retention.

### Treatment results

Treatment of Class III malocclusion with a mini maxillary protraction appliance resulted in a Class I molar occlusion, an ideal overjet and overbite, and ideal incisor angulation (Figs. 3A, 3B). In line with Björk's structural superimpositions (18), maxillary protraction resulted in an increase of the mandibular plane angle and forward movement of the maxilla, minimal lower incisor retrusion, and extrusion of the incisors. Slight changes were also observed in the soft-tissue profile and lips (Figs. 4A, 4B).

### Discussion

This case report demonstrated the response to maxillary expansion and protraction therapy. The SNA angle increased from  $77^\circ$  to  $78^\circ$ , and the ANB angle increased from  $-1^\circ$  to  $1^\circ$  during protraction therapy. An acrylic cap



Fig. 3A Post-treatment extraoral photographs.

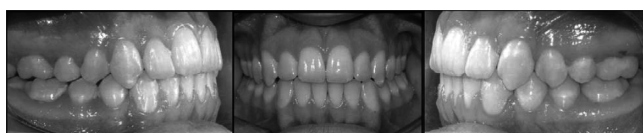

Fig. 3B Post-treatment intraoral photographs.

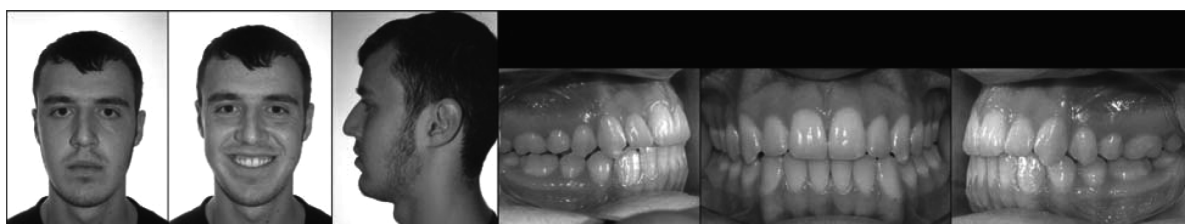


Fig. 5 One-year follow-up extra- and intraoral photographs.

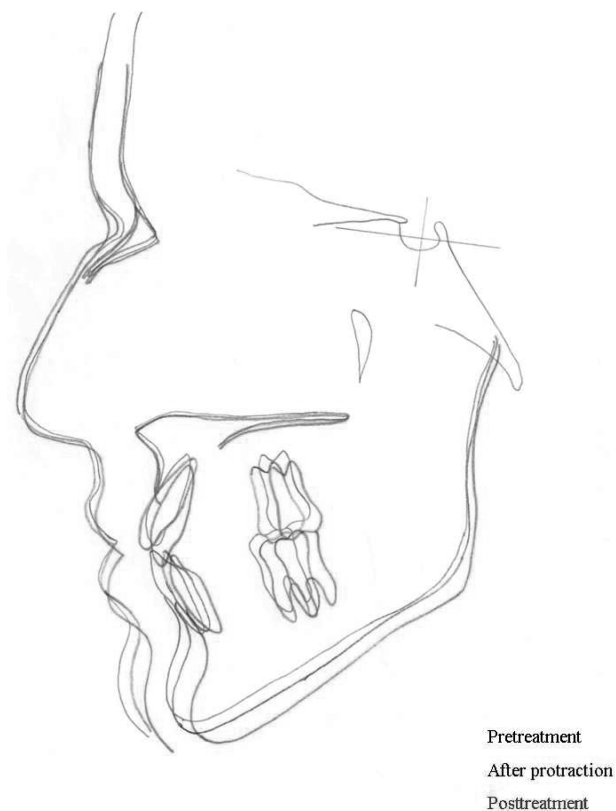


Fig. 4A

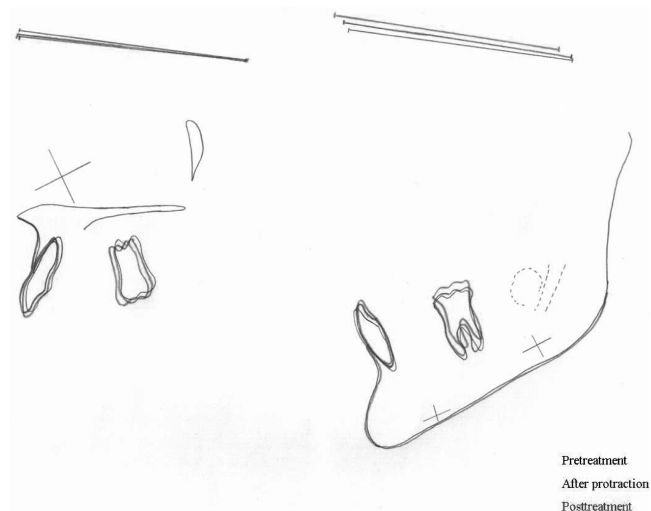


Fig. 4B

Fig. 4A-B Total and local superimpositions done according to Björk's structural superimposition technique.

splint-type expander was used to prevent occlusal interference and to maximize the skeletal effects of maxillary protraction. A 7.5-mm maxillary expansion was achieved. It has been reported that rapid maxillary expansion disrupts the maxillary sutural system and enhances the protraction effect of a face mask (11,12).

The chin is the anchorage region in this protraction device. The force applied to the mandible displaced the mandible downward and backward, and increased in the mandibular plane angle. This appliance can be used effectively in cases of maxillary retrognathism and lower anterior facial height. A counter-clockwise rotation of the palatal plane can be expected as a result of protraction, but on the other hand, the palatal plane rotates upwards.

This patient achieved a "gummy smile" at the end of treatment, which may have been due to insufficient upper lip coverage when smiling. As a clinical recommendation, clinicians should pay attention to the degree of the protraction force vector in patients who may have a gummy-smile tendency.

Optimal timing is important in maxillary protraction to improve the psychosocial development of the child (1,19). Sung and Baik reported that comparison of treatment effects according to age showed no significant difference (20). Kapust et al. divided subjects into three age groups and found minimal significant differences between the groups (21).

Although the treatment time with this appliance was the same as that for previous appliances, the present appliance is smaller, lacks the long vertical bar of a conventional protractor, and has minimal esthetic disadvantages in growing individuals. Therefore it is comfortable for the patient.

The reported case was a young male with a straight profile and a normal vertical facial pattern, who had completed 99% of his growth. Class III malocclusion was corrected in 6 months using a modified mini maxillary protractor and maintained during 1 year of follow-up (Fig. 5). However, long-term observation of this patient will be necessary, since mandibular growth still occurs in adolescence.

A modified maxillary protraction appliance was effective for the treatment of this young adult with skeletal Class III malocclusion.

## References

- Campbell PM (1983) The dilemma of Class III treatment. Early or late? *Angle Orthod* 53, 175-191.
- Ellis EE, McNamara JA Jr (1984) Components of adult Class III malocclusion. *J Oral Maxillofac Surg* 42, 295-305.
- Guyer EC, Ellis EE, McNamara JA Jr, Behrents RG (1986) Components of Class III malocclusion in juveniles and adolescents. *Angle Orthod* 56, 7-30.
- McNamara JA Jr, Brudon WL (1993) Orthodontic and orthopedic treatment in the mixed dentition. Needham Press, Ann Arbor, 117-129, 283-295.
- Potpeschnigg H (1875) Eine zahnrichtmaschine. *Deutsche Vierteljahres-Zahnheilk* 15, 34-36. (in German)
- Irie M, Nakamura S (1975) Orthopedic approach to severe skeletal Class III malocclusion. *Am J Orthod* 67, 377-392.
- Ishii H, Morita S, Takeuchi Y, Nakamura S (1987) Treatment effect of combined maxillary protraction and chin cap appliance in severe skeletal Class III cases. *Am J Orthod Dentofacial Orthop* 92, 304-312.
- Gallagher RW, Miranda F, Buschang PH (1998) Maxillary protraction: treatment and posttreatment effects. *Am J Orthod Dentofacial Orthop* 113, 612-619.
- Kambara T (1977) Dentofacial changes produced by extraoral forward force in the *Macaca irus*. *Am J Orthod* 71, 249-276.
- Nanda R (1978) Protraction of maxilla in rhesus monkeys by controlled extraoral forces. *Am J Orthod* 74, 121-141.
- McNamara JA Jr (1987) An orthopedic approach to the treatment of Class III malocclusion in young patients. *J Clin Orthod* 21, 598-608.
- Turley PK (1988) Orthopedic correction of Class III malocclusion with palatal expansion and custom protraction headgear. *J Clin Orthod* 23, 314-325.
- Proffit WR, Fields HW Jr (1993) Contemporary orthodontics. 3rd ed, Mosby, St Louis, 508-515.
- Altug Z, Arslan AD (2005) A mini-maxillary protractor for Class III correction. *J Clin Orthod* 39, 522-525.
- Altug Z, Arslan AD (2006) Skeletal and dental effects of a mini maxillary protraction appliance. *Angle Orthod* 76, 360-368.
- Houston WJ, Miller JC, Tanner JM (1979) Prediction of the timing of the adolescent growth spurt from ossification events in hand-wrist films. *Br J Orthod* 6, 142-152.
- Steiner CC (1959) Cephalometrics in clinical practice. *Angle Orthod* 29, 8-29.
- Björk A (1955) Cranial base development. A follow-up x-ray study of the individual variation in growth occurring between the ages of 12 and 20 years and

- its relation to brain case and face development. *Am J Orthod* 41, 198-225.
19. Joondeph DR (1993) Early orthodontic treatment. *Am J Orthod Dentofacial Orthop* 104, 199-200.
  20. Sung SJ, Baik HS (1998) Assessment of skeletal and dental changes by maxillary protraction. *Am J Orthod Dentofacial Orthop* 114, 492-502.
  21. Kapust AJ, Sinclair PM, Turley PK (1998) Cephalometric effects of face mask/expansion therapy in Class III children: a comparison of three age groups. *Am J Orthod Dentofacial Orthop* 113, 204-212.