

Central odontogenic fibroma of the mandible: a case report

Ioanna Daskala¹), Demos Kalyvas²), Markos Kolokoudias²),
Dimitris Vlachodimitropoulos³) and Constatinos Alexandridis²)

¹Dental School, University of Athens, Athens, Greece

²Department of Oral and Maxillofacial Surgery, Dental School, University of Athens, Athens, Greece

³Department of Forensic Medicine and Toxicology, Medical School, University of Athens, Athens, Greece

(Received 25 July 2008 and accepted 26 March 2009)

Abstract: Central odontogenic fibroma (COF) is a rare tumor that accounts for 0.1% of all odontogenic tumors. It has been defined as a benign neoplasm, which appears in the jaw. Clinically, the lesion grows slowly and leads to cortical expansion. Radiologically, the most common finding is multilocular radiolucency. In some cases, it may be associated with root resorption or displacement. Histologically, the lesion is characterized by mature collagen fibers and numerous fibroblasts. COF responds well to surgical enucleation with no tendency for malignancy or recurrence. Here, a case of central odontogenic fibroma of the mandible in a 71-year-old man is described. The lesion was an asymptomatic mass with well-defined borders covered by normal mucosa. The lesion presented as a multilocular radiolucency in relation to the root of the canine. The lesion was surgically removed and analyzed histopathologically. There were no postoperative complications. (J Oral Sci 51, 457-461, 2009)

Keywords: central odontogenic fibroma; diagnosis; treatment.

Introduction

Central odontogenic fibroma (COF) has been described as a rare, slow-growing tumor of the jaw. It appears as an asymptomatic expansion of the cortical plate of the mandible or maxilla (1-9). The possibility of being located

in the mandible is almost the same as that in the maxilla (55% and 45%, respectively, or according to Ramer et al. in 2002, 69% and 31%) (6,10). It should be pointed out that the most usual site of presentation in the mandible is the posterior area, while in the maxilla it is the anterior region (2,6,11). This lesion is a benign odontogenic neoplasm that is considered to be derived from mesenchymal odontogenic tissue (2,4,6,8,11-13). It seems that COF appears in a wide age group with predilection for females (11,14). COF radiologically presents as uni- or multilocular radiolucencies with well-defined borders. In some rare cases, it might present mixed radiolucent and radiopaque features and undefined borders (6,11). Root resorption and displacement have been reported in cases of more severe lesions (2,14). COF responds well to surgical enucleation with no tendency to undergo malignant transformation (1,5).

This paper reports a case of odontogenic fibroma of the mandible in a 71-year-old male patient. The findings are discussed in relation to previously case studies.

Case Report

A patient was diagnosed with intra-osseous fibroma at the Oral and Maxillofacial Surgery Clinic, Dental School, University of Athens, Greece. The age and sex of the patient, as well as the location and the radiographic findings of the lesion were obtained. A literature review revealed useful data on this rare neoplasm. After analysis of the data and based on the clinical, radiographic and histological findings, we re-evaluated our case to determine the type of the intra-osseous lesion.

A 71-year-old man was referred to the Oral and Maxillofacial Surgery Clinic with a painless gingival swelling in the left mandibular canine and premolar region. The patient

Correspondence to Dr. Ioanna Daskala, Thermopilon 87 st, Argiroupoli 16451, Athens, Greece

Tel: +30-2109914319

Fax: +30-2109914319

E-mail: iodaska@yahoo.com

reported slow growth of the lesion during the last four years. There were no other symptoms. The patient was hypertensive and under regular medication.

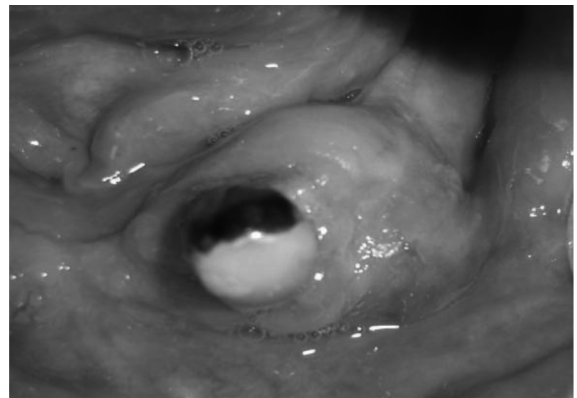
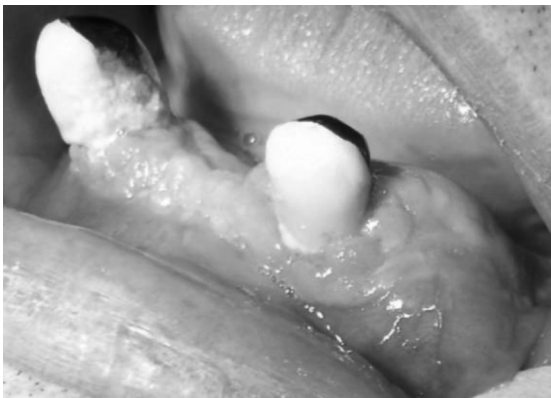The oral examination showed enlargement of the left canine and premolar region in the mandible. The lesion had a patulous base and non-tender bony-hard consistency. There was expansion of the buccal cortex and the oral mucosa covering the mass was firm and of normal colour (Figs. 1 and 2). The involved teeth were positive to thermal testing. The needle aspiration was inconclusive. There was no facial asymmetry and no cervical lymphadenopathy. Radiographic evaluation showed the presence of a multilocular radiolucent area associated with the root of the left canine in the mandible. The margins of the lesion were well-circumscribed and it did not appear to provoke root resorption of the teeth (Figs. 3 and 4).

Differential diagnosis of lesions with similar clinical and radiographic picture included: central ossifying fibroma,

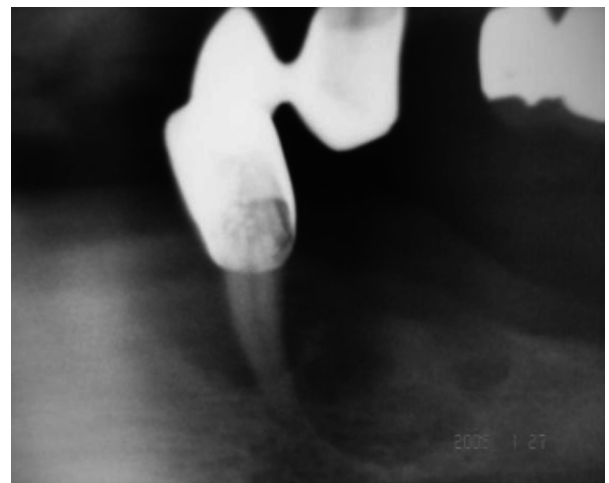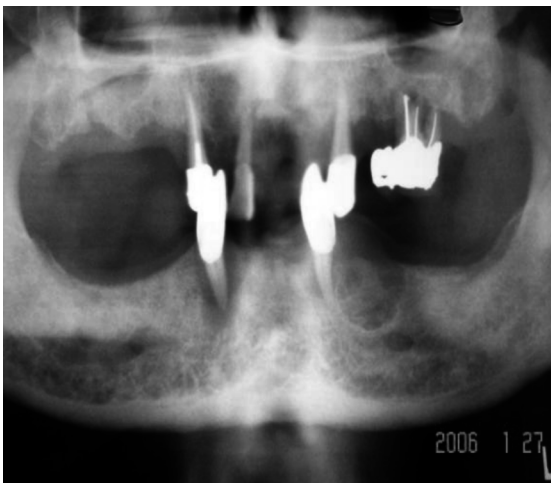
traumatic bone cyst, fibrous dysplasia of the bone, calcifying odontogenic cyst, cementoma, dentigerous cyst, and ameloblastoma (1,15).

The tumor was removed under local anesthesia and the excised specimen measured $3 \times 2 \times 1$ cm (Figs. 5 and 6). The specimen consisted of intermingling bundles of loose collagen fibers situated in a myxoid stroma featuring slender fibroblasts. Irregular, acellular calcifications are present in the connective tissues, as a few round, small, odontogenic epithelial nests (Figs. 7, 8, 9 and 10). Based on the clinical, radiographic and histologic findings, a diagnosis of central odontogenic fibroma was made and it may also be subclassified as epithelial - poor type.

The patient was given necessary advice for recovery. He was examined thoroughly 1, 2 and 4 weeks after surgery and no complications were reported (Fig. 11).



Figs. 1 and 2 Clinical features of COF (an asymptomatic, well-circumscribed and intra-osseous mass).

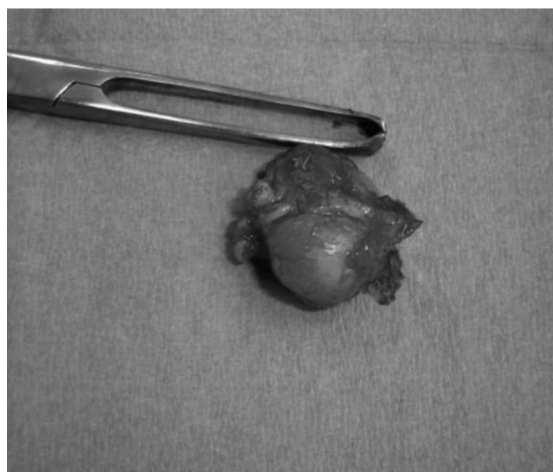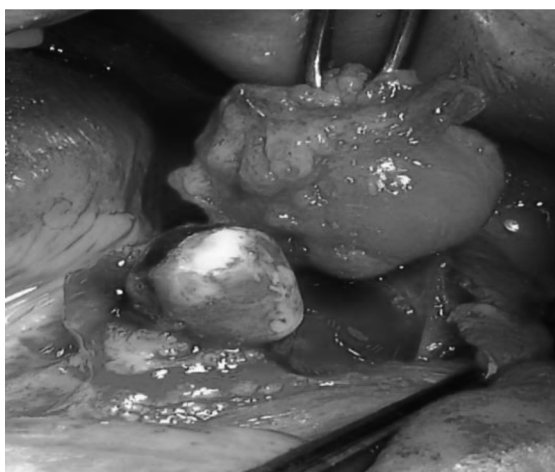


Figs. 3 and 4 Radiographic presentation of the lesion showing the presence of a multilocular radiolucent area associated with the root of the left canine.

Discussion

Gardner in 1980 classified lesions described as COF into three categories: 1) the hyperplastic dental follicle; 2) a fibrous neoplasm with collagenous fibrous connective tissue containing odontogenic epithelium – (simple type); and 3) a lesion with dysplastic dentine or tissue like cementum and odontogenic epithelium (WHO type) (1,15). Moreover, WHO type contained fibrous tissue with myxoid area (2). Currently, it has been suggested that the WHO type should be referred to as odontogenic fibroma complex type or fibroblastic odontogenic fibroma (16-20) (Table 1). The COF is a benign neoplasm reported in the literature that is usually diagnosed in the second and third decade

of life (2,21). The most usual sign is swelling of the mandible or maxilla and less frequently pain and paresthesia are observed (2). Though the COF is reported more often in females than males (1,10), our patient was a 71-year-old man. The lesion had grown slowly and expanded to the buccal cortex. It was a painless swelling and for this reason, the patient had not paid any attention to the lesion during the first three years. The lesion generally measures approximately 0.5-4 cm, usually appearing well-defined and radiographically as a unilocular or multilocular radiolucent area (2,22). However, in this case the mass was well-circumscribed, about $3 \times 2 \times 1$ cm and radiographically described as a multilocular area. There are usually no



Figs. 5 and 6 The tumor was removed under local anesthesia and the excised specimen measured $3 \times 2 \times 1$ cm.

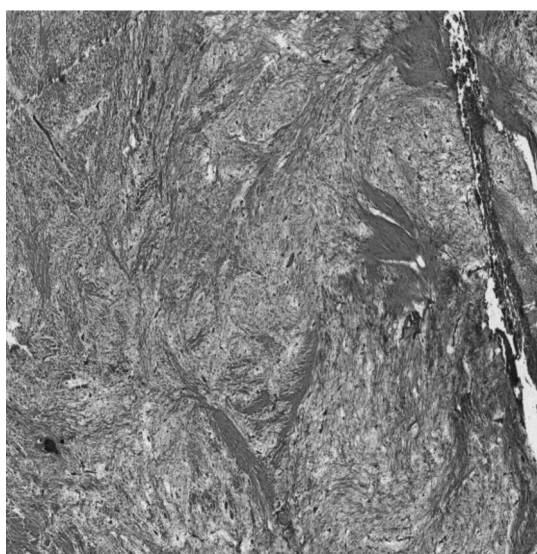


Fig. 7 Interlacing bundles of myxoid fibrous connective tissue (H-E staining. Original magnification $\times 40$).

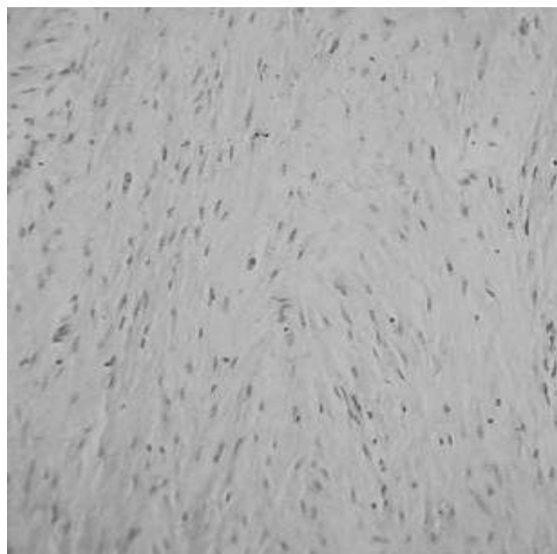


Fig. 8 Interlacing strands of slender fibroblasts in a loose connective tissue stroma (H-E staining. Original magnification $\times 100$).

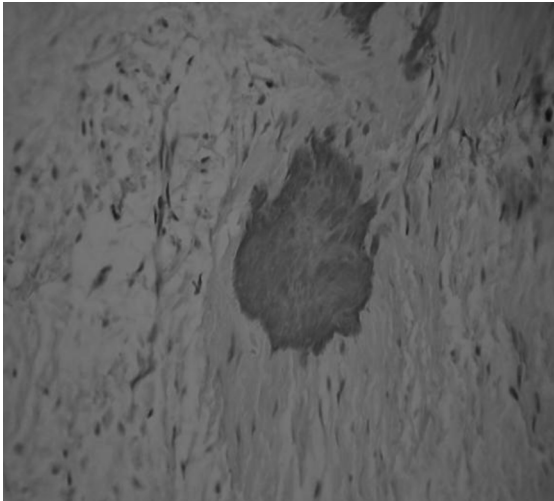


Fig. 9 Focus of calcified material (H-E staining. Original magnification $\times 400$).

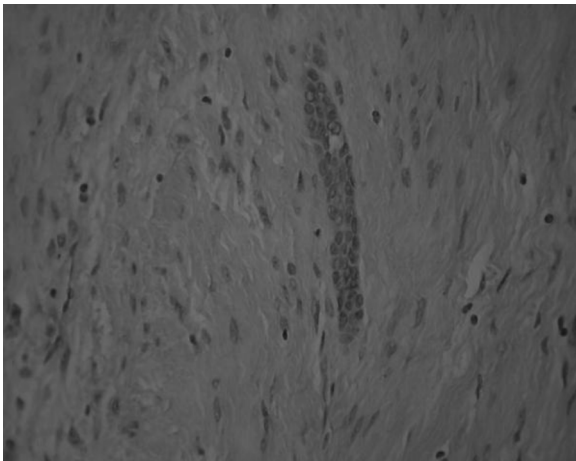


Fig. 10 Rare strand of odontogenic epithelium (H-E staining. Original magnification $\times 400$).

side-effects and no postoperative complications, as observed in our case report. However, dentists must be aware of the clinical, radiological and histopathological findings of this intra-osseous mass of the jaw, in order to include it in the differential diagnosis of neoplasms.

Acknowledgments

We would like to thank Mr Jonathan Henriksen for his excellent photographic assistance.

References

1. Daniels JS (2004) Central odontogenic fibroma of a mandible: a case report and review of the literature. *Oral Surg Oral Med Oral Pathol Oral Radiol Endod* 98, 295-300.
2. Covani U, Crespi R, Perrini N, Barone A (2005) Central odontogenic fibroma: a case report. *Med Oral*

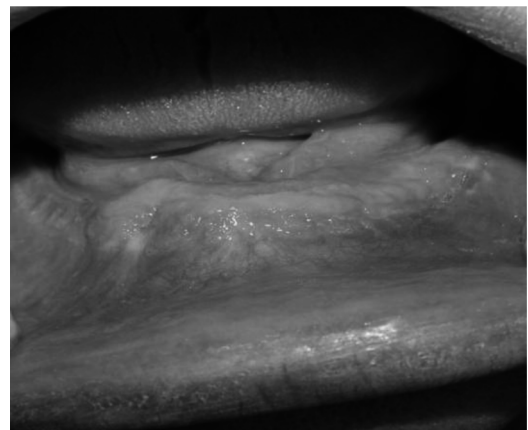


Fig. 11 Post-operative recovery without complications.

Table1 The WHO type odontogenic fibrom

Authors	Case of COF	Sex	Location	Follow-up
Watt-Smith et al. 1998 (7)	1	female	mandible	no recurrence
Ikeshima and Utsunomiya 2005 (9)	3	female	mandible maxilla	–
Raubenheimer and Noffke 2002 (11)	1	male	mandible and maxilla	–
Daniels 2004 (1)	1	female	mandible	no recurrence
Doyle et al. 1985 (20)	6	male (4) female (2)	mandible	no recurrence
Handlers et al. 1991 (21)	19	male (4) female (15)	mandible (3) maxilla (16)	no recurrence (4) not available (15)
Dunlap and Barker 1984 (19)	2	male (1) female (1)	maxilla	no recurrence
Allen et al. 1992 (18)	3	female	mandible maxilla	one recurrence

- Pathol Oral Cir Bucal 10, suppl 2, 154-157.
3. Dunlap CL (1999) Odontogenic fibroma. *Semin Diagn Pathol* 16, 293-296.
 4. Rebai-Chabchoub N, Marbaix E, Iriarte Ortabe JI, Reyhler H (1993) Central odontogenic fibroma. *Rev Stomatol Chir Maxillofac* 94, 271-275.
 5. Huey MW, Bramwell JD, Hutter JW, Kratochvil FJ (1995) Central odontogenic fibroma mimicking a lesion of endodontic origin. *J Endod* 21, 625-627.
 6. Kaffe I, Buchner A (1994) Radiologic features of central odontogenic fibroma. *Oral Surg Oral Med Oral Pathol* 78, 811-818.
 7. Watt-Smith SR, Ell-Labban NG, Tinkler SM (1998) Central odontogenic fibroma. *Int J Oral Maxillofac Surg* 17, 87-91.
 8. Wesly RK, Wysocki GP, Mintz SM (1975) The central odontogenic fibroma. Clinical and morphologic studies. *Oral Surg Oral Med Oral Pathol* 40, 235-245.
 9. Ikeshima A, Utsunomiya T (2005) Case report of intra-osseous fibroma: a study on odontogenic and desmoplastic fibromas with a review of the literature. *J Oral Sci* 47, 149-157.
 10. Ramer M, Buonocore P, Krost B (2002) Central odontogenic fibroma-report of a case and review of the literature. *Periodontal Clin Investig* 24, 27-30.
 11. Raubenheimer EJ, Noffke C (2002) Central odontogenic fibroma-like tumors, hypodontia, and enamel dysplasia: review of the literature and report of a case. *Oral Surg Oral Med Oral Pathol Oral Radiol Endod* 94, 74-77.
 12. Jones GM, Evenson JW, Shepherd JP (1989) Central odontogenic fibroma. A report of two controversial cases illustrating diagnostic dilemmas. *Br J Oral Maxillofac Surg* 27, 406-411.
 13. Gardner DG (1982) The peripheral odontogenic fibroma: an attempt at clarification. *Oral Surg Oral Med Oral Pathol* 54, 40-48.
 14. Cercadillo-Ibarguren I, Berini-Aytes L, Marco-Molino V, Gay-Escoda C (2006) Locally aggressive central odontogenic fibroma associated to an inflammatory cyst: a clinical histological and immunohistochemical study. *J Oral Pathol Med* 35, 513-516.
 15. MacDonald-Jankowski DS (2004) Fibro-osseous lesions of the face and jaws. *Clin Radiol* 59, 11-25.
 16. Gardner DG (1980) The central odontogenic fibroma: an attempt at clarification. *Oral Surg Oral Med Oral Pathol* 50, 425-432.
 17. Gardner DG (1996) Central odontogenic fibroma current concepts. *J Oral Pathol Med* 25, 556-561.
 18. Allen CM, Hammond HL, Stimson PG (1992) Central odontogenic fibroma, WHO type. A report of three cases with an unusual associated giant cell reaction. *Oral Surg Oral Med Oral Pathol* 73, 62-66.
 19. Dunlap CL, Barker BF (1984) Central odontogenic fibroma of the WHO type. *Oral Surg Oral Med Oral Pathol* 57, 390-394.
 20. Doyle JL, Lamster IB, Baden E (1985) Odontogenic fibroma of the complex (WHO) type: report of six cases. *J Oral Maxillofac Surg* 43, 666-674.
 21. Handlers JP, Abrams AM, Melrose RJ, Danforth R (1991) Central odontogenic fibroma: clinicopathologic features of 19 cases and review of the literature. *J Oral Maxillofac Surg* 49, 46-54.
 22. Regezi JA (2002) Odontogenic cysts, odontogenic tumors, fibrous and giant cell lesions of the jaws. *Mod Pathol* 15, 331-341.