

# Comparison between gutta-percha and Resilon retreatment

Mina Zarei<sup>1)</sup>, Fatemeh Shahrami<sup>1)</sup> and Mehdi Vatanpour<sup>2)</sup>

<sup>1)</sup>Department of Endodontics, Faculty of Dentistry and Dental Research Center, Mashhad University of Medical Sciences, Mashhad, Iran

<sup>2)</sup>Department of Endodontics, Faculty of Dentistry, Azad University of Medical Sciences, Tehran, Iran

(Received 7 October 2008 and accepted 30 January 2009)

**Abstract:** Retreatments procedures in endodontic practice require complete removal of the original root filling materials. The aim of this study was to compare the amount of residual filling material on the walls of root canals that were obturated with gutta-percha or Resilon. Thirty extracted single-rooted human teeth were selected and instrumented by RaCe rotary instruments up to MAF #35. They were randomly divided into two groups of 15 teeth each. Group 1 was obturated with gutta-percha and AH26 sealer and group 2 was obturated with the Resilon/Epiphany system by lateral condensation technique. All canals were then retreated using Gates-Glidden drills, MAF #40 and chloroform. The teeth were split longitudinally and photographs were taken by a digital camera connected to a stereomicroscope and then samples were analyzed. The amount of residual material and time of retreatment were determined in each group at three levels in the canal. Data were analyzed by Mann-Whitney and Friedman tests. The Resilon group had significantly more residual material in the canal than the Gutta-percha group ( $P = 0.009$ ). According to the level of the canal, the differences were statistically significant ( $P = 0.013$ ) only in the Resilon group. Time required for retreatment in the two groups was not significantly different ( $P = 0.381$ ). Orthograde retreatment of Resilon was less efficient than that of gutta-percha. (J Oral Sci 51, 181-185, 2009)

**Keywords:** retreatment; rotary instruments; residue material; resilon/epiphany system; gutta-percha.

---



---

## Introduction

Gutta-percha, in combination with a variety of sealers, is the most commonly used material for root canal obturation. Resilon (Pentron Clinical Technologies, Wallingford, CT), a thermoplastic, synthetic, polyester polymer-based root canal filling material, was recently proposed as an alternative to gutta-percha. Resilon is composed of bioactive glass and radiopaque fillers. Its performance is the same as that of gutta-percha, and it has the same handling properties (1). The Resilon sealer is a dual-curable dental-resin composite sealer which has a total filler content of about 70% of its weight, allowing its easy removal in retreatment cases (2). The fillers include calcium hydroxide, barium sulfate, barium glass and silica.

Nickel-titanium (Ni-Ti) files have been used increasingly for root canal preparation because of their unique physical properties (3,4). Endodontic retreatment is indicated when the root canal system is reinfected. This procedure involves complete removal of the original root filling, further cleaning and refilling (5). Gutta-percha is the most commonly removed root-canal filling material (6). However, previous studies have revealed that, when using gutta-percha, the canal walls may not be completely free of debris (1,5,6). Various techniques are employed to remove gutta-percha, including the use of hand or rotary instruments with or without heat application, solvents, and/or ultrasound (7-9). Ni-Ti rotary instruments have also been used for removing filling materials from root canal walls, and numerous studies have reported on their efficacy, cleaning ability, and safety (9-13). In clinical practice,

---

Correspondence to Dr. Mina Zarei, Department of Endodontics, Faculty of Dentistry and Dental Research Center, Mashhad University of Medical Sciences, Mashhad, P.O. Box: 91735-984, Iran

Tel: +98-511-8829501-15

Fax: +98-511-8829500

E-mail: zareim@mums.ac.ir

chloroform is the most effective and most preferred solvent for the removal of gutta-percha (14). It has also been suggested as a solvent for the removal of Resilon. The purpose of this study was to compare the amount of residual filling material on the canal walls in root canals filled with gutta-percha or Resilon and retreated using the RaCe rotary system.

## Materials and Methods

### Specimen preparation

Thirty extracted single-rooted human teeth with a single patent canal were selected and stored in 5.25% NaOCl for 1 h and then in saline until use. The crowns were flattened using steel discs (Brasseler USA, Savannah, Ga, USA) and a final dimension of 15 mm was achieved for each tooth with working lengths set at 14 mm. Root canal preparation was performed by the crown down technique using 0.04 tapered Easy RaCe rotary files (FKG, Switzerland) with a master apical file size #35 (40/ 0.10, 35/ 0.08, 30/ 0.06, 25, 30, 35/0.04 were used sequentially according to the manufacturer's instructions). Throughout instrumentation, a total of 30 ml of 5.25% NaOCl was delivered. After instrumentation, the root canals were rinsed with 5 ml of 17% EDTA (Pulpdent, Watertown, MA, USA) and finally with 5 ml saline. The teeth were then dried and divided into two groups of 15 teeth each. In group 1, the canals were filled with gutta-percha (Hygienic, Coltene/Whaledent Inc, Mahwah, NJ, USA) and AH26 sealer (Dentsply DeTrey, Konstanz, Germany) using the lateral condensation technique. Medium fine accessory cones were introduced for filling the root canals by lateral condensation. The canals in group 2 were coated with the primer using a soaked paper point and excess was removed with a dry paper point, and the sealant was then placed into the root canal with a previously selected master Resilon cone (Pentron Clinical Technologies, Wallingford, CT, USA). Medium fine accessory cones were used for lateral condensation.

A heated instrument was used to seal the filling material off at the orifices of all the canals, and in group 2, the root canal entrances were immediately light-cured for 40 s. The teeth were radiographed in buccolingual and mesiodistal directions to confirm the adequacy of the root filling. After placing a temporary restoration of Zonalin (Masterdent, New York, USA), each tooth was stored in a humidior at 37°C for 2 weeks to allow the sealer to set completely.

### Retreatment Techniques

All temporary cements were removed by fissure bur and 5 mm of filling materials were removed from the cervical

part of the root canal by Gates-Glidden burs # 2 and # 3 (Maillefer, Ballaigues, Switzerland). A drop of 0.2 ml chloroform was introduced in each canal to soften the filling material, and then removed by RaCe rotary files (FKG Dentaire, La-chaux-de-Fonds, Switzerland). The working length was regained gradually using a pecking motion and then the canals were instrumented with file 35/ 0.04; and 40/ 0.04. Therefore, all canals were enlarged to a final file # 40 taper 0.04. During retreatment, all instruments were used in two canals and then discarded. Root canals were constantly irrigated with 5.25% NaOCl. The criteria for completion of retreatment were the presence of clean filings, no evidence of filling material on the files or paper point and smooth canal walls. After final instrumentation, all canals were irrigated with EDTA and dried with paper points. The duration of retreatment, recorded to the nearest second with a stopwatch, was based on the net time of retreatment procedures. All procedures were performed by the same operator. The teeth were grooved vertically with steel discs (Brasseler USA, Savannah, GA, USA) on the buccal and lingual surfaces. They were then split into halves longitudinally with a chisel and mallet. The cleanliness of the canal wall was evaluated through an optical stereomicroscopy with  $\times 20$  magnification (Blue Light Industry, La Habra, CA, USA) and photographs were taken by a Digital Camera (Exwave HAD, Sony, Tokyo, Japan). As in the study by Ezzie et al. (9), a grading system was developed with respect to the amount of residual obturating material and debris at the coronal, middle and apical portions of each canal according to the following criteria:

1. None to slight presence (< 25%) of obturating material and debris on the dentin surface
2. Some presence (25-50%)
3. Moderate presence (50-75%)
4. Heavy presence (> 75%)

No attempt was made to distinguish between filling materials or sealer remnants and the evaluations were carried out blindly by three operators who were unaware of the treatment that was rendered.

### Statistical analysis

Time required for material removal in each group was measured in minutes. Using SPSS software (version 11), canal cleanliness was analyzed with regards to field area between experimental groups. Group comparisons were done using Mann-Whitney and Friedman tests. The significance for all statistical tests was  $P < 0.05$ .

## Results

None of the rotary files showed intracanal failure in either

of the groups. Furthermore, the incidence of all perforations, blockages or ledging was recorded. Residues of the filling materials were observed in all the specimens, regardless of the root filling material. According to Mann-Whitney and Friedman tests, the results were as below:

1) With Friedman test according to mean rank in each group (Table 1), the highest percentage of residual material was determined to be in the coronal region, and the difference between the two groups was significant ( $P = 0.000$ ) (Fig. 1).

2) In the middle and apical parts of the canal, the Resilon and gutta-percha groups were significantly different ( $P = 0.005$ ,  $P = 0.01$ ).

3) Regardless of the level of the canal, there was significantly more residual material in the Resilon group than in the gutta-percha group ( $P = 0.009$ ) (Fig. 2).

4) When the amount of fillings at each third of the root canals were compared, there were no statistically significant differences ( $P = 0.166$ ) in the gutta-percha group in contrast with the Resilon group ( $P = 0.013$ ).

5) Time required for retreatment (from the start of removal of the filling material until completion of cleaning of the debris on the MAF file) was analyzed and the difference between the two groups was not significant ( $P = 0.381$ ). The mean times recorded in the gutta-percha and Resilon groups were 1 h 56 s and 1 h 9 s, respectively.

## Discussion

The success of endodontic retreatment is directly related to the complete removal of the obturating material from the root canal. A number of techniques have been proposed to remove obturating material from the canal system, including the use of manual files, rotary instruments, Gates-Glidden burs, heat, ultrasound, and adjunctive solvents (9,12,14). The root canals were filled using lateral condensation, similar to that reported in most previous studies (15,16). As Wilcox et al. (16) and Friedman et al. (17) have shown, epoxy-resin-based sealers adhere to the dentine and are more difficult to remove than non-adhesive sealers. Therefore, in order to ensure a fair assessment of the Resilon system, we compared it with AH26 which is an epoxy-resin sealer.

In the present study, we used Easy RaCe rotary files for canal preparation and retreatment procedures, as they are most routinely used. For removing the filling material, we used Gates-Glidden drills at the orifice level, as did Friedman et al. (18), for facilitating access to the most apical portion. Chloroform was used as the solvent because it effectively dissolves gutta-percha (19), and it was also recommended by the manufacturer for retreatment of the Resilon system. The remaining material was removed

Table 1 Mean rank in two experimental groups

Section	Group	Mean rank	<i>P</i> value
Coronal	Resilon	21.73	0.000
	Gutta-percha	9.27	
Middle	Resilon	19.67	0.005
	Gutta-percha	11.33	
Apical	Resilon	19.27	0.01
	Gutta-percha	11.73	

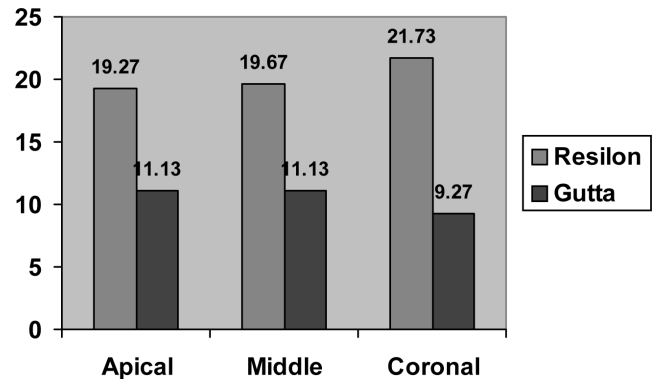


Fig. 1 Mean rank residue material at three levels in the canal.

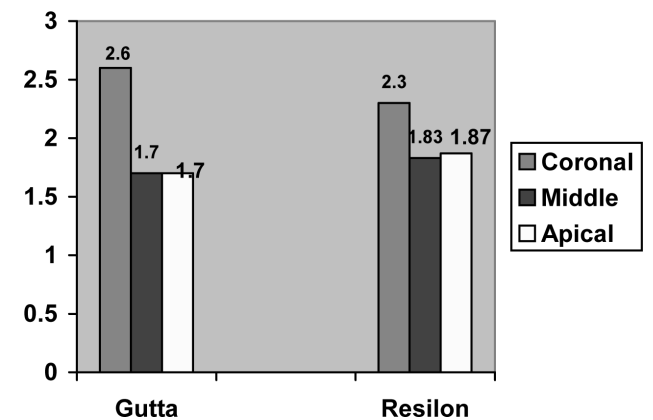


Fig. 2 Mean rank residue material in the two experimental groups.

with engine-driven instruments because the filling material was trapped in the instruments' flutes.

The conventional methods of removing gutta-percha using hand files can be a tedious, time-consuming process (15). Several studies have shown that Ni-Ti rotary files are safe to use in removing filling materials (9,11-13,19). In the present study, we captured images with a digital camera connected to a stereomicroscope with  $\times 20$  magnification, similar to that used by Wilcox et al. (16) and Oliveira et al. (15).

In the present study, the retreatment procedure was considered complete when there was no evident filling material on the instruments. However, all the canals had remnants of the filling material, as shown in other studies (9,13). Our results indicate that the absence of filling material on the instruments is not a valid criterion for demonstrating complete removal of filling material from the canal walls, as elucidated by the results of a study by Schirrmeister et al. (12).

It is expected that the amount of residual filling material would be less if the removal was done with an operating dental microscope. For routine endodontic therapy, we do not use a dental microscope for removal of filling material and previous studies have shown that the difference was not statistically significant (20); however, some other studies contradict these findings (21,22). The time required to remove gutta-percha was lesser than that for Resilon; however, the difference was not statistically significant. Our results are in contradiction with those of Ezzie et al. (9) and de Oliveira et al. (15), but are in accordance with those of Schirrmeister et al. (12), who reported that the mean time of retreatment did not depend on the type of filling material. In this study, the amount of residue was consistently higher at the coronal canal level, and this result does not agree with those of other studies (9,13,23,24). This may be because the temporary filling materials were retained on the canal walls in the coronal region.

In the present study, a significantly greater amount of obturating material was observed in the Resilon group than in the gutta-percha group, which contradicted the results of Ezzie et al. (9) and Schirrmeister et al. (12), but was in accordance with those of Hassanloo et al. (23). As Taşdemir et al. (13) have mentioned, this contradiction between different studies could be attributed to methodological differences and to the possibility that the Resilon filling in other studies might have been removed before they had completely hardened during the 1 – 3 weeks. After removal of the material, the amount of debris in the Resilon group was significantly higher in the coronal and the middle regions than in the apical region. This may have been due to the relatively ineffective removal of the smear layer and sealer delivery to the apical portion; using a file one size bigger than MAF may result in cleaner apical canal walls (25). Within the experimental conditions of the present study, the currently available endodontic filling system is retreatable with chloroform and rotary files, and orthograde retreatment of Resilon was less effective than that of gutta-percha.

## Acknowledgments

This study was supported by a grant from the Vice Chancellor of Research Council of Mashhad University of Medical Sciences, Iran.

## References

1. Shipper G, Ørstavik D, Teixeira FB, Trope M (2004) An evaluation of microbial leakage in roots filled with a thermoplastic synthetic polymer-based root canal filling material (Resilon). *J Endod* 30, 342-347.
2. Teixeira FB, Teixeira EC, Thompson J, Leinfeider KF, Trope M (2004) Dentinal bonding reaches the root canal system. *J Esthet Restor Dent* 16, 348-354.
3. Poulsen WB, Dove SB, de Rio CE (1995) Effect of nickel-titanium engine-driven instrument rotational speed on root canal morphology. *J Endod* 21, 609-612.
4. Sae-Lim V, Rajamanickam I, Lim BK, Lee HL (2000) Effectiveness of Profile .04 taper rotary instruments in endodontic retreatment. *J Endod* 26, 100-104.
5. Stabholz A, Friedman S (1988) Endodontic retreatment-case selection and technique. Part 2: treatment planning for retreatment. *J Endod* 14, 604-614.
6. Friedman S, Rotstein I, Shar-Lev S (1989) Bypassing gutta-percha root fillings with an automated device. *J Endod* 15, 432-437.
7. Wilcox LR (1989) Endodontic retreatment: ultrasonics and chloroform as the final step in reinstrumentation. *J Endod* 15, 125-128.
8. Hülsmann M, Bluhm V (2004) Efficacy, cleaning ability and safety of different rotary NiTi instruments in root canal retreatment. *Int Endod J* 37, 468-476.
9. Ezzie E, Fleury A, Solomon E, Spears R, He J (2006) Efficacy of retreatment techniques for a resin-based root canal obturation material. *J Endod* 32, 341-344.
10. Imura N, Kato AS, Hata GI, Uemura M, Toda T, Weine F (2000) A comparison of the relative efficacies of four hand and rotary instrumentation techniques during endodontic retreatment. *Int Endod J* 33, 361-366.
11. Masiero AV, Barletta FB (2005) Effectiveness of different techniques for removing gutta-percha during retreatment. *Int Endod J* 38, 2-7.
12. Schirrmeister JF, Meyer KM, Hermanns P, Altenburger MJ, Wrbas KT (2006) Effectiveness of hand and rotary instrumentation for removing a new synthetic polymer-based root canal obturation

- material (Epiphany) during retreatment. *Int Endod J* 39, 150-156.
13. Taşdemir T, Yildirim T, Celik D (2008) Comparative study of removal of current endodontic fillings. *J Endod* 34, 326-329.
  14. Cunha RS, De Martin AS, Barros PP, da Silva FM, de Castilho Jacinto R, da Silveira Bueno CE (2007) In vitro evaluation of the cleansing working time and analysis of the amount of gutta-percha or Resilon remnants in the root canal walls after instrumentation for endodontic retreatment. *J Endod* 33, 1426-1428.
  15. de Oliveira DP, Barbizam JVB, Trope M, Teixeira FB (2006) Comparison between gutta-percha and resilon removal using two different techniques in endodontic retreatment. *J Endod* 32, 362-364.
  16. Wilcox LR, Krell KV, Madison S, Rittman B (1987) Endodontic retreatment: evaluation of gutta-percha and sealer removal and canal reinstrumentation. *J Endod* 13, 453-457.
  17. Friedman S, Moshonov J, Trope M (1992) Efficacy of removing glass ionomer cement, zinc oxide eugenol, and epoxy resin sealers from retreated root canals. *Oral Surg Oral Med Oral Pathol* 73, 609-612.
  18. Friedman S, Moshonov J, Trope M (1993) Residue of gutta-percha and a glass ionomer cement sealer following root canal retreatment. *Int Endod J* 26, 169-172.
  19. Bramante CM, Betti LV (2000) Efficacy of Quantec rotary instruments for gutta-percha removal. *Int Endod J* 33, 463-467.
  20. Baldassari-Cruz LA, Wilcox LR (1999) Effectiveness of gutta-percha removal with and without the microscope. *J Endod* 25, 627-628.
  21. Baldassari-Cruz LA, Lilly JP, Rivera EM (2002) The influence of dental operating microscope in locating the mesiolingual canal orifice. *Oral Surg Oral Med Oral Pathol Oral Radiol Endod* 93, 190-194.
  22. Schirrmeister JF, Hermanns P, Meyer KM, Goetz F, Hellwig E (2006) Detectability of residual Epiphany and gutta-percha after root canal retreatment using a dental operating microscope and radiographs – an ex vivo study. *Int Endod J* 39, 558-565.
  23. Hassanloo A, Watson P, Finer Y, Friedman S (2007) Retreatment efficacy of the Epiphany soft resin obturation system. *Int Endod J* 40, 633-643.
  24. Schirrmeister JF, Wrbas KT, Schneider FH, Altenburger MJ, Hellwig E (2006) Effectiveness of a hand file and three nickel-titanium rotary instruments for removing gutta-percha in curved root canals during retreatment. *Oral Surg Oral Med Oral Pathol Oral Radiol Endod* 101, 542-547.
  25. Somma F, Cammarota G, Plotino G, Grande NM, Pameijer CH (2008) The effectiveness of manual and mechanical instrumentation for the retreatment of three different root canal filling materials. *J Endod* 34, 466-469.