

Endodontic treatment of a radiculous maxillary premolar: a case report

Maryam Javidi, Mina Zarei and Mehdi Vatanpour

Department of Endodontics, Faculty of Dentistry, Mashad University of Medical Sciences, Mashhad, Iran

(Received 9 July and accepted 18 December 2007)

Abstract: We report the diagnosis and successful clinical management of three patients with anatomical variation in the maxillary first premolars. Maxillary first premolars have highly variable root canal morphology, but the presence of three canals is rare. This article describes the diagnosis and clinical management of first maxillary premolars with three canals and three separate roots, with special reference to radiographic interpretation and access refinements. (J. Oral Sci. 50, 99-102, 2008)

Keywords: anatomical variations; maxillary premolar; radiculous.

Introduction

Although three-rooted maxillary premolars are rare, the possibility of extra roots or canals should be borne in mind to ensure successful endodontic treatment. The most important reason for treatment failure is incomplete cleaning and shaping of canals. Therefore the first step for successful treatment is an exact diagnosis of the root canal system and recognition of its variations. One of the possible variations of maxillary first premolars is the presence of extra roots. This anatomic abnormality is an additional challenge, which begins at case assessment and involves all operative stages, including access cavity design, localization, cleaning and shaping of the root canal system.

The reported frequency of three root canals in a maxillary premolar varies from 0.5% to 6% (1-4), generally with one

canal in each of three roots (5). The anatomy of three-rooted maxillary premolars resembles that of maxillary molars, and therefore they are sometimes referred to as small molars or as being "radiculous" (6,7).

Although preoperative radiography gives a two-dimensional image of a three-dimensional object, precise interpretation can reveal external and anatomic details that suggest the presence of extra canals/roots. For this reason, whenever there is an abrupt straightening or loss of a radiolucent canal in the pulp cavity, an extra canal should be suspected, either in the same root or in other independent roots (8).

Also, whenever the mesio-distal width of the mid-root image is equal to or greater than the mesio distal width of the crown, the tooth most likely has three roots (9).

Case Report

Case 1

A 23-year-old male presented at the dental clinic of the Faculty of Dentistry, Mashad University of Medical Sciences, because of severe pain in tooth #24. The patient had no systemic disorder. Clinically, the probing depth was less than 3 mm all around the tooth, and no mobility was seen.

The pulp had been exposed by a carious lesion and the tooth was very sensitive to cold (Endo-frost, Roeko, Langenau, Germany). A preoperative radiograph revealed caries on the mesial surface of the tooth, with an abrupt loss of radiolucency in the pulp canal and a mesio-distal root diameter greater than the mesiodistal width of the crown (Fig. 1). Also, as radiographic findings showed, a possible anatomic tooth variation was suspected.

After anesthesia with persocaine-E (Lidocaine 2% plus epinephrine 1/80000; Darou Pakhsh Co, Tehran, Iran), a rubber dam was placed and an access cavity was prepared. In the floor of pulp chamber only two orifices were

Correspondence to Dr. Maryam Javidi, Department of Endodontics, Faculty of Dentistry, Mashad University, P.O. Box: 91735-984, Mashhad, Iran
Tel: +98-511-8829501-15
Fax: +98-511-8829500
E-mail: m_javidi_endo@yahoo.com

detectable. Even with extension of the access cavity, no other orifices were found. As we noted a slightly larger size of the buccal orifice, extension of this orifice was carried out using a low-speed round bur No 1 (Dentsply Maillefer, Ballaigues, Switzerland). By exploring the extended buccal orifice with a DG16 explorer, the exact location of the mesiobuccal and distobuccal canals was clarified.

By initial placing of a No. 15 file (Dentsply Maillefer) a working radiograph was taken (Fig. 2). This radiograph confirmed the presence of three canals. Then biomechanical preparation was carried out with 5.25% NaOCl as an irrigant. Master apical files comprising No. 35 in the buccal canals and No. 40 in the palatal canal were selected,

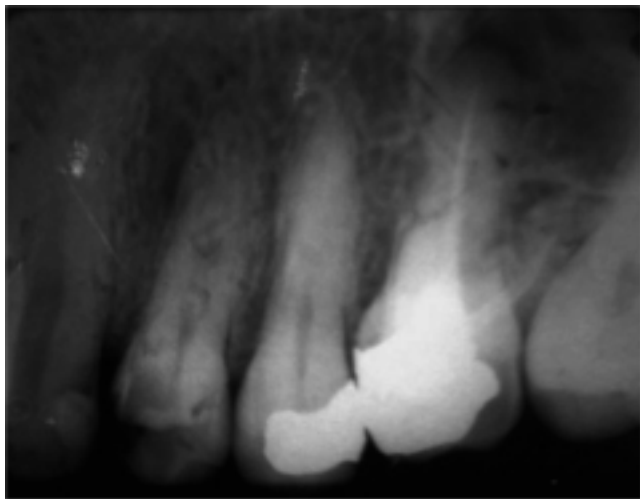


Fig. 1 Diagnostic film, showing caries and complexity of the roots of tooth #24.

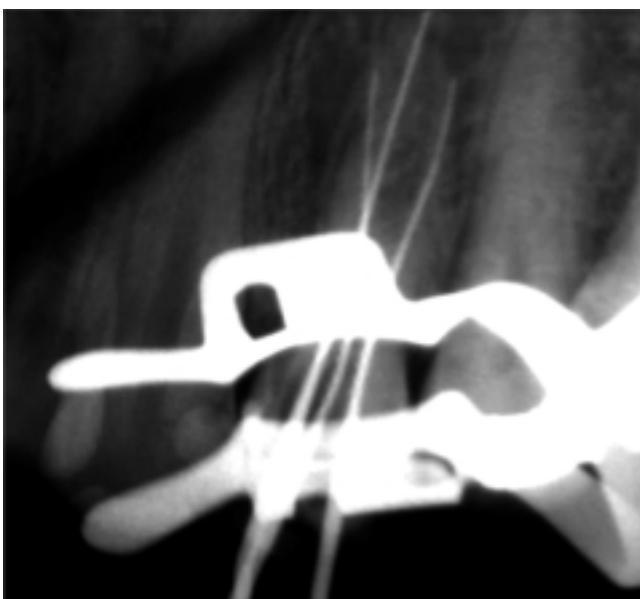


Fig. 2 Initial file: Three separate canals were negotiated.

and after shaping, obturation was carried out with gutta-percha points and AH26 sealer (Dentsply DeTrey, Konstanz, Germany) as a sealer using the lateral condensation technique (Fig. 3).

Case 2

A 35-year-old healthy male presented at the dental clinic of the Faculty of Dentistry, Mashad University of Medical Sciences, because of percussion pain in tooth #24. A preoperative radiograph revealed an incompletely treated root canal and a radicular lesion. Considering the width of the mesiodistal part of the root in the middle region and complexity, a possible extra root was suspected (Fig. 4).

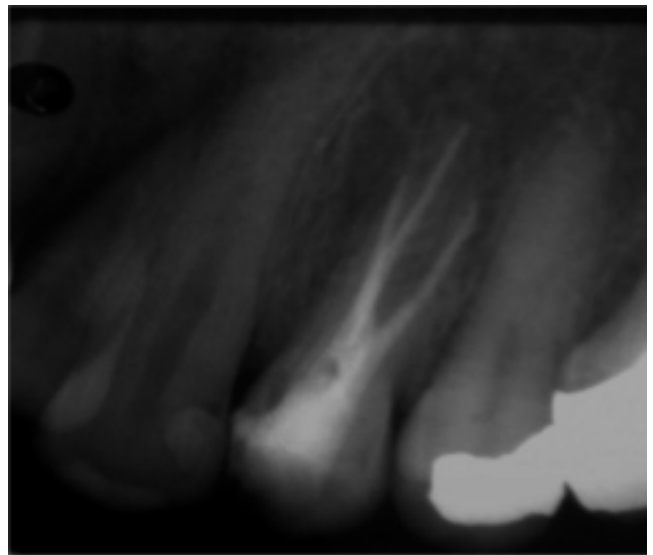


Fig. 3 Obturation.

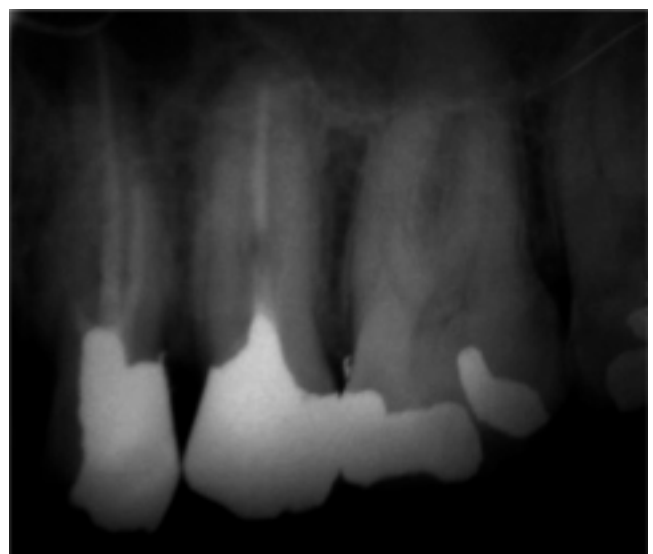

Fig. 4 Diagnostic film, showing poor obturation and a missed canal in tooth #24.

After anesthesia with persocaine-E and placing of a rubber dam, all existing restoration materials were removed, and immediately after preparation of an improved access cavity, a third orifice was found near the distal marginal ridge and toward the buccal cusp. After removal of the previous obturation materials, completion of cleaning and shaping was performed with hand files (Dentsply Maillefer). Master apical files comprising No. 40 for the buccal canals and No. 45 for the palatal canal were selected. Obturation of the three canals was done with gutta-percha points using AH26 and the lateral condensation technique (Fig. 5).

Case 3

A 28-year-old healthy female presented at the dental clinic of the Faculty of Dentistry, Mashad University of Medical Sciences, because of persistent severe tooth pain in response to cold. Tooth #14 had been treated one month before presentation, but her preoperative pain had persisted. Her last radiograph revealed evidence of an extra root (Fig. 6). After anesthesia with Persocaine-E and placing of a rubber dam, all previous restorations were removed and improved access was achieved using a DG16 explorer. The third missed orifice was found easily after bio-mechanical cleaning and shaping with hand files (Dentsply Maillefer) and 5.25% NaOCl. Master apical files comprising No. 30 in the buccal canals and No. 35 in the palatal canal were selected. Obturation of the three canals was done with gutta-percha points using AH26 and the lateral condensation technique (Fig. 7).

Discussion

Although access to all of the root canals, cleaning and shaping, followed by hermetic filling are necessary for successful root canal treatment, knowledge of the anatomical abnormalities of teeth is very important for successful endodontic treatment. Therefore accurate evaluation of diagnostic radiographic views is essential for confirming the number of tooth roots and canals. In the treatment of three-rooted maxillary first premolars, the buccal orifices may be completely separate, as in cases 2 and 3, or very close to each other as in case 1, making localization of the orifices difficult. Some studies have advocated a T-shaped access outline (10). However, in cases like the present case 1, only the directional positioning of an explorer and files is able to locate the buccal orifices, although in all cases radiographic examination is also important. Precise radiographic examination can alert clinicians to the presence of variations, leading to successful treatment.

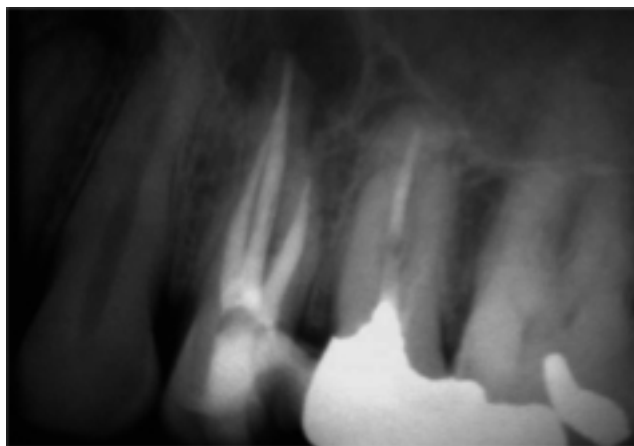


Fig. 5 Obturation.

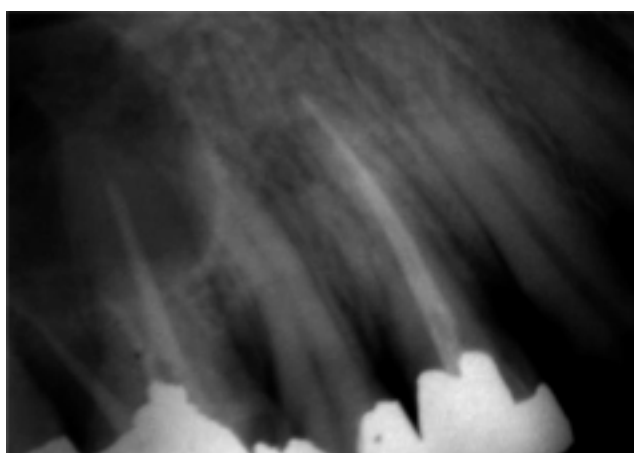


Fig. 6 Diagnostic film, showing poor obturation and a missed canal in tooth #14.

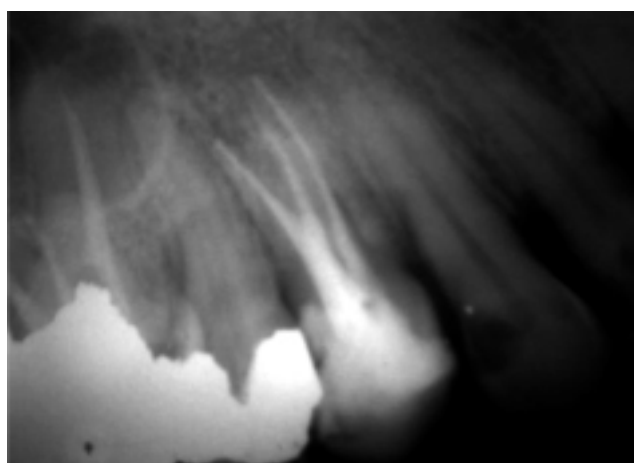


Fig. 7 Radiograph after retreatment of three canals.

References

1. Bellizzi R, Hartwell G (1985) Radiographic evaluation of root canal anatomy of *in vivo* endodontically treated maxillary premolars. *J Endod* 11, 37-39

2. Carns EJ, Skidmore AE (1973) Configuration and deviations of root canals of maxillary first premolars. *Oral Surg Oral Med Oral Pathol* 36, 880-886
3. Hess W (1925) Anatomy of the root canals of the teeth of the permanent dentitions. Part I. William Wood, New York, 3-49
4. Pineda F, Kuttler Y (1972) Mesiodistal and buccolingual roentgenographic investigation of 7,275 root canals. *Oral Surg Oral Med Oral Pathol* 33, 101-110
5. Vertucci FJ, Gegauff A (1979) Root canal morphology of the maxillary first premolar. *J Am Dent Assoc* 99, 194-198
6. Maibaum WW (1989) Endodontic treatment of a "ridiculous" maxillary premolar: a case report. *Gen Dent* 37, 340-341
7. Goon WW (1993) The "radiculous" maxillary premolar: recognition diagnosis and case report of surgical intervention. *Northwest Dent.* 72, 31-33
8. Soares JA, Leonardo RT (2003) Root canal treatment of three-rooted maxillary first and second premolars – a case report. *Int Endod J* 36, 705-710
9. Sieraski SM, Taylor GN, Kohn RA (1989) Identification and endodontic management of three-canal maxillary premolars. *J Endod* 15, 29-32
10. Balleri P, Gesi A, Ferrari M (1997) Primer premolar superior com tres raices. *Endod Prac* 3, 13-15