

Fabrication of a maxillary posterior fixed partial denture with a type 4 gold alloy and a dual-polymerizing indirect composite

Hideo Matsumura^{1,2)}, Shuichi Mori³⁾ and Naomi Tanoue⁴⁾

¹⁾Department of Fixed Prosthodontics, Nihon University School of Dentistry, Tokyo, Japan

²⁾Division of Advanced Dental Treatment, Dental Research Center, Nihon University School of Dentistry, Tokyo, Japan

³⁾Private Dental Laboratory, Nagayo, Japan

⁴⁾Department of Specialized Dentistry, Nagasaki University Hospital of Medicine and Dentistry, Nagasaki, Japan

(Received 8 January and accepted 25 February 2008)

Abstract: The aim of the present study was to design and fabricate a maxillary posterior fixed partial denture (FPD) made of a type 4 gold alloy and an indirect composite. Unlike the conventional framework design of a resin veneered restoration, cut-back was extended approximately 1/4 to 1/3 width in the occlusal table of the buccal cusp. Multiple retentive beads 150-200 µm in diameter were placed on the metal surface to be veneered. The gold alloy was cast in a cristobalite mold using a centrifugal casting machine. The cut surface with the retentive beads was air-abraded with alumina, and a priming agent (Alloy Primer) that contained triazine dithione monomer (VTD) was applied. A tooth-colored veneer was then fabricated with a highly loaded light- and heat-cured composite material (Estenia). This design and procedure can be applied as a standardized laboratory technique for fabrication of maxillary posterior restorations and FPDs. (*J. Oral Sci.* 50, 113-116, 2008)

Keywords: composite; cut-back; framework; gold alloy; retentive bead; triazine.

Correspondence to Dr. Hideo Matsumura, Department of Fixed Prosthodontics, Nihon University School of Dentistry, 1-8-13 Kanda-Surugadai, Chiyoda-ku, Tokyo 101-8310, Japan
Tel: +81-3-3219-8145
Fax: +81-3-3219-8351
E-mail: matsumura@dent.nihon-u.ac.jp

Introduction

Type 4 gold alloy is used in prosthodontic practice because of its excellent mechanical and handling properties, age-hardenability, and adequate corrosion resistance. The alloy is applied to long-spanned fixed partial dentures (FPDs) as well as removable denture frameworks. However, one of the problems associated with prostheses made of type 4 gold alloy has been the lack of bonding ability with tooth-colored materials. Also, the properties of resin veneering agents need to be improved for the long-term success of prosthodontic treatments.

A highly loaded dual-activated composite material with more than 90 mass% of inorganic filler (Estenia, Kuraray Co., Ltd., Kurashiki, Japan) was released in 1997. Laboratory evaluation subsequently demonstrated the improved characteristics of the indirect composite material (1-4). Although the manufacturer recommends the use of the Estenia and Estenia C&B (Kuraray Medical Inc., Tokyo, Japan) materials primarily for metal-free restorations (4-6), clinicians and dental laboratory technicians need to acquire a standardized veneering technique for the casting alloy in combination with the currently available composite material and bonding system. This article describes veneering procedures for the gold alloy framework of a maxillary posterior FPD with the Estenia composite. Photographs of the current veneering technique can be seen in a representative Japanese prosthodontic textbook for undergraduate dental students (7).

Technical Case Report

A maxillary three-unit FPD to be used for education in fixed prosthodontic practice was planned for a simulated patient model. Abutment preparation, impression, and die fabrication were performed using the same procedure as that for porcelain-fused-to-metal (PFM) restorations. The facial finish line to be veneered should be either a rounded shoulder preparation without marginal bevel or a chamfer preparation with sufficient thickness. The laboratory procedures consisted of the following steps.

1. Prepare a wax pattern of the FPD on the stone dies. Mark the contact point and the border of the veneering area (Fig. 1).
2. Cut back the buccal surface of the premolar wax retainer and the first molar pontic with a carving instrument (Fig. 2).
3. Extend the cut back area to the entire buccal surfaces as well as occlusal tables within the range from 1/4 to 1/3 of the buccal cusp width (Fig. 3).
4. Apply adhesive, sprinkle retentive beads 150-200 μm in diameter (Retention Beads ss, GC Corp., Tokyo, Japan), and place a runner bar and sprues using a wax material (Ready Casting Wax, GC Corp.) (Fig. 4).
5. Invest the wax pattern into a cristobalite mold material. Cast gold alloy (Casting Gold Type IV, GC Corp.) into the mold with a centrifugal casting apparatus (Fig. 5).
6. Cut the sprues with a rotary cutting disk (Fig. 6). One-piece casting is also acceptable for the three-unit FPD.
7. After soldering between the second molar retainer and the first molar pontic, confirm the fit to the dies of the prosthesis, and polish the framework moderately (Fig. 7).
8. Grind the peripheral area of the cut-back surface to remove retentive beads and to flatten the marginal veneering area. Abrade the cut-back surface with 50-70 μm alumina (Hi-Aluminas, Shofu Inc., Kyoto, Japan) using an airborne particle abrader (Jet Blast II, J. Morita Corp., Suita, Japan), to increase the bonding area and mechanically clean the surface (Fig. 8).
9. Apply a single liquid priming agent (Alloy Primer, Kuraray Medical Inc.) containing both a thione monomer (6-(4-vinylbenzyl-*n*-propyl)amino 1,3,5-triazine 2,4-dithione, VTD) and a phosphate monomer (10-methacryloyloxydecyl dihydrogen phosphate, MDP) to the alumina-blasted surface (Fig. 9).
10. Apply a single liquid bonding agent (Estenia Opaque Primer, Kuraray Medical Inc.) for consistent bonding between the framework and the opaque resin. Paint a thin layer of opaque material, and expose the layers to light from a laboratory polymerizing apparatus (α -Light II, J. Morita Corp.) for 30 s (Fig. 10).
11. Repeat application of the Opaque Primer, opaque resin, and subsequent light-polymerization three times to enhance conversion of the opaque resin matrix. The Opaque Primer contains both the MDP adhesion promoting monomer and an initiator for heat and redox dual-polymerization. Characterize the opaque resin surface using the appropriate shade of staining material (Fig. 11).
12. Place the dentin portion of the composite material (Estenia) with a thin spatula, and pre-polymerize the resin matrix with the unit for 10 s. Insert hair-lines and/or other characteristics again using the staining materials before application of the incisal colored material. Add an enamel portion material (Estenia) to the incisal edges to reproduce a natural tooth-color appearance.
13. Apply surface coating material (Air-Barrier, Kuraray Medical Inc.) to reduce the surface inhibited layer of the resin component, and light-polymerize the veneered materials in the unit for 5 minutes (Fig. 12).
14. Heat the FPD in an oven (KL 100, J. Morita Inc.) at 100°C for 15 minutes to ensure the heat polymerization reaction.
15. Grind and polish the surface with rotary instruments (Smooth Cut, GC Corp.; Seiko Wheel, Seikoshia, Kurume, Japan; and Sharp Mini, Ohki Chemical, Hiroshima, Japan). Use a diamond paste (Dia Glaze, Yeti Dental-Shirokusu, Osaka, Japan) to achieve a microscopically smooth surface (Figs. 13-15).

Discussion

This report has described a technique for fabrication of a FPD using a highly loaded light- and heat-polymerizable composite material and a type 4 gold alloy, since the porcelain-fused-to-metal technique cannot be applied to type 4 gold alloys. This combination is applicable to cone telescope dentures, long-spanned fixed partial dentures, and conventional dentures with varied structures. Matsumura et al. previously reported an anterior fixed partial denture made of the Estenia composite and Ti-6Al-7Nb alloy, in which incisal edges of the anterior teeth, 2-3 mm in length, were fabricated with the composite (8). The design aimed to achieve improvement in the esthetic appearance of the incisal edges.

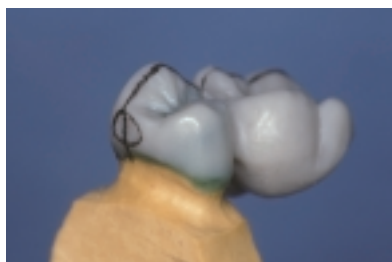

Fig. 1 A wax pattern for the premolar retainer and pontic.

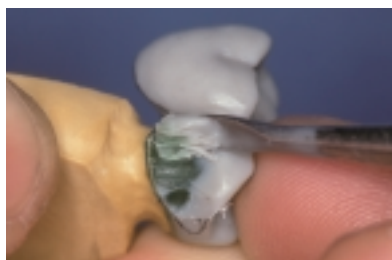

Fig. 2 Cut-back with a wax carver for the facial surfaces.

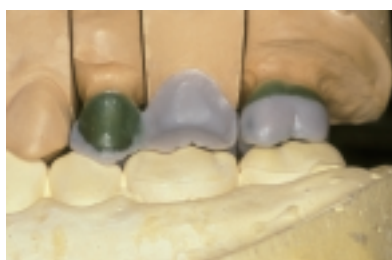

Fig. 3 Buccal view of the wax pattern.

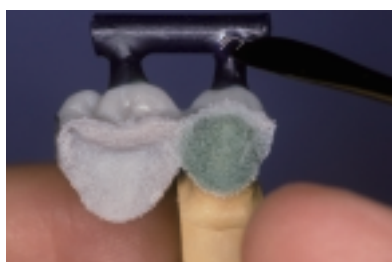

Fig. 4 Placement of retentive beads (Retention Beads ss), sprues, and a runner bar.

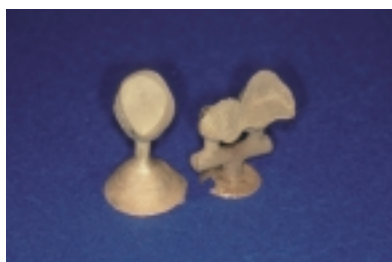

Fig. 5 Retainers and a pontic cast with type 4 gold alloy.




Fig. 6 Cutting the sprue with a rotary cutting disk.



Fig. 7 Cast gold alloy framework.

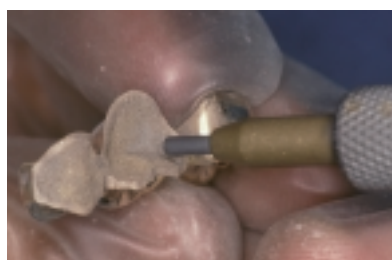

Fig. 8 Air-abrasion with alumina (50-70 μm , Hi-Aluminas).

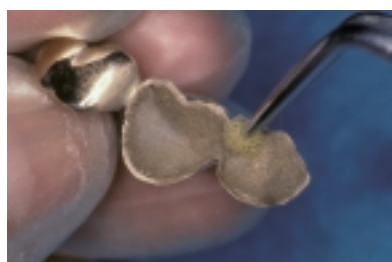


Fig. 9 Application of a priming agent (Alloy Primer).

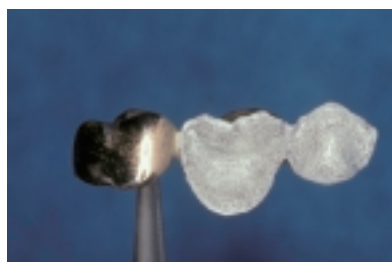

Fig. 10 Application of a bonding agent (Estenia Opaque Primer) and thin layers of opaque material.

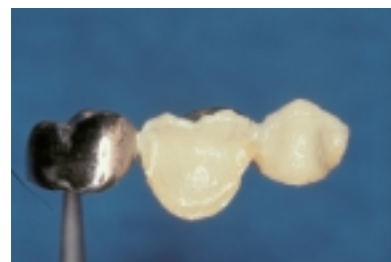

Fig. 11 Repeated application of the Opaque Primer liquid and the opaque resin.




Fig. 12 Light polymerization of the Estenia composite.

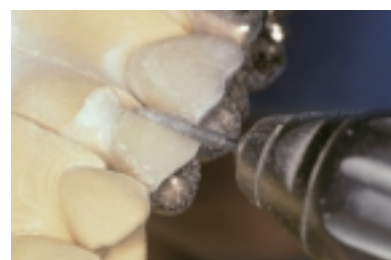

Fig. 13 Grinding the surface with a diamond rotary instrument.

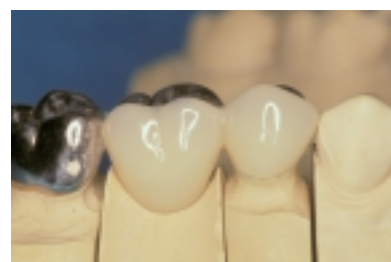

Fig. 14 Buccal view of the FPD.

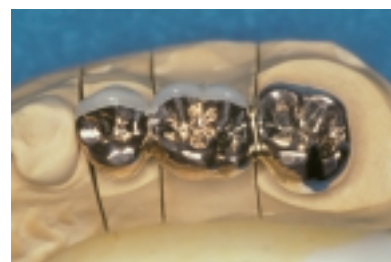

Fig. 15 Occlusal view of the FPD. Approximately 1/4 to 1/3 of the buccal cusp is veneered with the Estenia composite.

Based on the design of anterior restorations, the present report has described a design for maxillary posterior restorations. In the presented case, approximately 1/4-1/3 of the buccal cusps in bucco-lingual width were covered with the composite material. According to previous reports on clinical evaluation of composite veneered restorations, the color stability, rather than wear and unpredictable fracture, of a veneering agent is a critical concern (9-11). Considering the fact that a maxillary buccal cusp is not a functional cusp, and that the majority of patients are susceptible to cuspid protected occlusion in their lateral mandibular movement, the probability of direct contact between the composite material and an antagonist will be low. This concept, however, is not applicable to mandibular dentition because buccal cusps are functional cusps in the mandible.

Ogino et al. reported that wear resistance of the Estenia composite is higher than that of type 4 gold alloy, although bonding of the composite and alloy considerably affects the wear characteristics of jointed materials (12). Shiono et al. described a case of severely worn cast restoration opposed by a restoration made of the Estenia composite, in which polishing of the restoration surface appeared to be insufficient. Due to the increased loading of inorganic fillers as shown for Estenia, the wear resistance of composite materials has improved substantially. A roughened composite surface, however, plays the role of an abrasive instrument to an antagonist. It is necessary for clinicians and dental laboratory technicians to understand that highly loaded composites demonstrate the characteristics of a brittle ceramic material, and that careful polishing using a series of diamond rotary instruments is indispensable for achieving smooth surfaces.

Acknowledgments

This work was supported in part by a grant from the Japan Dental Association, and by the Sato Fund, Nihon University School of Dentistry.

References

1. Tanoue N, Matsumura H, Atsuta M (2000) Wear and surface roughness of current prosthetic composites after toothbrush/dentifrice abrasion. *J Prosthet Dent* 84, 93-97
2. Kawano F, Ohguri T, Ichikawa T, Matsumoto N (2001) Influence of thermal cycles in water on flexural strength of laboratory-processed composite resin. *J Oral Rehabil* 28, 703-707
3. Takahashi Y, Hisama K, Sato H, Chai J, Shimizu H, Kido H, Ukon S (2002) Probability of failure of highly filled indirect resin-veneered implant-supported restorations: an *in vitro* study. *Int J Prosthodont* 15, 179-182
4. Nakamura T, Waki T, Kinuta S, Tanaka H (2003) Strength and elastic modulus of fiber-reinforced composites used for fabricating FPDs. *Int J Prosthodont* 16, 549-553
5. Shiono H, Koizumi H, Nemoto M, Ishikawa Y, Matsumura H, Tanoue N (2005) Clinical evaluation of jacket crowns made of the Estenia indirect composite. *Int Chin J Dent* 5, 17-21
6. Kuijs RH, Fennis WM, Kreulen CM, Roeters FJ, Creugers NH, Burgersdijk RC (2006) A randomized clinical trial of cusp-replacing resin composite restorations: efficiency and short-term effectiveness. *Int J Prosthodont* 19, 349-354
7. Atsuta M, Matsumura H (2004) Resin-veneered restorations. In *Crown and bridge prosthodontics*, 3rd ed, Ishibashi K, Kawazoe T, Kawawa T, Fukushima S, Yatani H eds, Ishiyaku Publishers, Tokyo, 192-199 (in Japanese)
8. Matsumura H, Yoneyama T, Shimoe S (2002) Veneering technique for a Ti-6Al-7Nb framework used in a resin-bonded fixed partial denture with a highly filled indirect composite. *J Prosthet Dent* 88, 636-639
9. Matsumura H, Nakamura M, Tanoue N, Atsuta M (2000) Clinical evaluation of an urethane tetramethacrylate-based composite material as a prosthetic veneering agent. *J Oral Rehabil* 27, 846-852
10. Tanoue N, Mori S, Sugawara H, Matsumura H, Koizumi H (2006) One-year clinical evaluation of anterior composite veneered restorations made of the Solidex composite and silver-palladium-copper-gold alloy. *Int Chin J Dent* 6, 105-109
11. Tanoue N, Shimoe S, Nemoto M, Matsumura H (2005) Repair and re-seating of resin-bonded fixed partial denture performed after minimal abutment reduction: a clinical report. *Int Chin J Dent* 5, 97-100
12. Ogino T, Koizumi H, Furuchi M, Murakami M, Matsumura H, Tanoue N (2007) Effect of a metal priming agent on wear resistance of gold alloy-indirect composite joint. *Dent Mater J* 26, 201-208